1) Dentre as comorbidades da Doença de Dupuytren encontramos mais frequentemente
   a) Anemia, hipotireoidismo, sarcoidose e artrite reumatoide
   b) Psoríase, Diabetes, hipercolesterolemia e índice de massa corporal abaixo da média
   c) Síndrome do túnel do carpo, artrite reumatoide, sinovite vilonodular e artrose
   d) Gota, anemia, cefaléia e dedo em gatilho

Resposta B

referência Green página 149

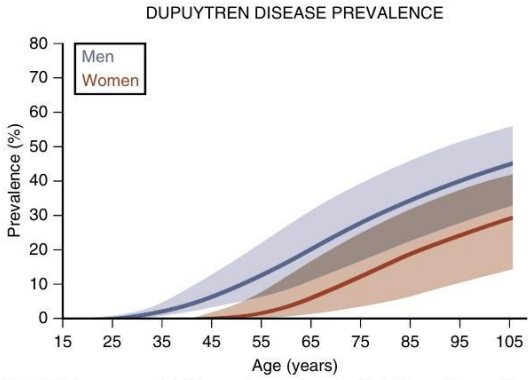

Fig. 4.1 Summary of DD prevalence data in 11 high-quality studies selected from 199 reviewed publications. Lines represent mean values; shaded areas are 95% confidence intervals. Prevalence in women parallels that of men but lags by about 15 years. (Data from Lanting R, Broekstra DC, Werker PMN, et al: A systematic review and meta-analysis on the prevalence of Dupuytren disease in the general population of Western countries, *Plast Reconstr Surg* 133[3]:593–603, 2014.)

Self-reported family history studies *underreport* Dupuytren prevalence because of late-onset disease and lack of awareness of mild involvement in senior relatives.[34] Nearly half of DD patients know of an affected relative.[17] However, over two-thirds will have an affected living relative if one examines the extended family tree.[34] *Positive family history is the strongest predictor of developing the disease* and is associated with early onset and early age of first treatment.[17,35] On average, patients with *both* parental lines affected have an earlier age of onset than those with only one affected line, who, in turn, have an earlier age of onset than those with no family history.[35] An affected sibling triples one's risk of developing DD.[17] These findings strongly suggest a genetic basis. It is likely that Dupuytren, like diabetes, is not one disease but a phenotypic group involving multiple genes and environmental triggers.

Ectopic Disease Versus Dupuytren Spectrum

In Dupuytren patients, similar local soft tissue changes can arise in areas outside the palm. Nodular fibrotic changes of the extensor surfaces of finger or toe joints (knuckle pads), plantar tissues (Ledderhose), shoulder joint capsule (frozen shoulder),[36] and tunica albuginea of the penis (Peyronie)[37] correlate with the presence of DD. Other locations of Dupuytren-linked nodular pathology include the gastrocnemius fascia,[38] Achilles tendon,[39] forearm,[40] palmaris longus,[41] Guyon canal,[42] flexor carpi ulnaris,[39,43] flexor carpi radialis,[39,44] and upper arm.[45] Because these findings may or may not present with palm disease, "ectopic Dupuytren disease" is a misnomer. For example, the author has followed a patient for over a decade with bilateral knuckle pads, Ledderhose, and frozen shoulder, but unaffected palms. Referring to this group of related fibrotic manifestations[38] as *Dupuytren spectrum disease* better reflects demographic[36,37,46,47] and genomic[48-50] correlations and the need for a systemic research focus.

Dupuytren Diathesis

The term *diathesis* was first used in 1891 to distinguish idiopathic from "false" (posttraumatic) DC.[51] Houston reintroduced the term in 1961 to describe a *recontracture-prone Dupuytren phenotype* associated with a family history of Dupuytren, knuckle pads, bilateral disease, Ledderhose disease, and "younger average age" at treatment.[52] However, he repeatedly changed the criteria and, three decades later, cautioned against efforts to quantify diathesis-based predictions.[53]

Efforts to quantify the correlation between recontracture and diathesis factors have yielded conflicting results. Statistical correlations between recontracture and family history of Dupuytren have been reported as significant[35,54-56] and *not* significant[57-63]; knuckle pads significant[57,60] and *not* significant[61]; Ledderhose significant[54,55,57] and *not* significant,[60,61] early-onset disease significant,[55,58-60] *not* significant,[62-64] and significant *negative* risk[61]; any ectopic lesions (knuckle pads, Ledderhose, Peyronie) significant[39,55,58,59] and *not* significant[60,62]; bilateral involvement significant[55-57] and *not* significant[58,60,61,63]; male gender significant[55,60] and *not* significant[62]; younger age at first treatment significant,[39,54,56,62,65-69] *not* significant,[64,70] and significant *negative* risk[61]; more than two involved rays significant[55] and *not* significant[58]; more than three involved rays significant[71] and *not* significant[59]; radial hand involvement significant[55,59,71] and *not* significant.[62,72] Predictive combinations of risk factors have also been reported[55,59,60] and disputed.[62] Despite these uncertainties, diathesis factors of *family history of DD, onset younger than 50, Ledderhose,* and *knuckle pads* are in everyday use to guide recommendations. The bulk of evidence suggests the *strongest biologic predictor of recontracture is younger age at the first corrective procedure.* Diathesis factors do *not* correlate with either histologic staging,[73] Dupuytren genetic risk score,[74] or 5-year functional outcomes.[75]

Comorbidities and Risk Factor Categories

Reported DD *comorbidities* include hypercholesterolemia,[76] diabetes,[77] smoking tobacco,[78] alcoholism,[79] diabetes,[80] psoriasis,[81] epilepsy,[80] regional trauma,[82] chronic hand vibration exposure,[83] and a lower-than-average body mass index.[84] Whether these associations *cause, aggravate,* or relate to a *common origin* requires a better understanding of the molecular biology of disease onset and disease persistence. The literature is mixed, with conflicting reports of either correlation or lack of correlation for most of these factors.[35,85]

Dupuytren risk categories include (1) risk of *ever developing DD,* (2) risk of *progression* from a nodule to contracture, and (3) risk of *recontracture* after a corrective procedure. These are not interchangeable. For example, diabetes[86] and hyperlipidemia[76,87] correlate more with the risk of developing DD than with the risk of progressing to DC. The opposite is the case for chronic hand vibration exposure.[86] Alcoholism correlates with a greater risk of diagnosis and contracture[86] but not the age at first treatment.[35]

Spurious correlations are an issue in the study of Dupuytren and other chronic diseases. For example, frequent medical visits for a chronic illness increase the chance of diagnosing an unrelated chronic disease such as DD and falsely associating the two.[77,88] In contrast, patients with multiple medical comorbidities are less likely to choose treatment for recontracture,[89] biasing associations between comorbidities and postprocedure progression. Measurements of *angular contracture severity* without considering disease duration may also yield spurious correlations. For example, chronic heavy alcohol use correlates with greater contracture severity[90] but may also delay treatment presentation, leading to greater contracture severity at presentation. *Disease awareness* from affected family members *lowers* the average self-reported age of onset, which *increases* the self-reported duration of disease.

Rheumatoid arthritis[91] and obesity[92] are *negative risk factors* for Dupuytren: They correlate with a *lower risk* of developing DD. Overlapping genetic loci relating to both body mass index (BMI) and DD[93,94] points to the potential of investigating biologically different comorbidities to guide further research into the origins of DD.

2) A técnica de tenorrafia abaixo foi descrita por qual autor e quando utilizada para tendões flexores dos dedos é melhor indicada nas zonas:

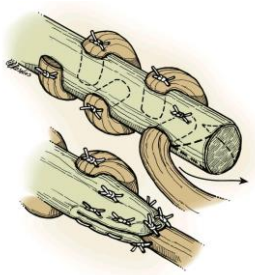

a) Bunnell - Zonas 1 e 2
b) Bruner - Zonas 3 e 4
c) Pulvertaft – Zonas 3 e 5
d) Tsuge – Zonas 2 e 4

Resposta C
referência Green página 237

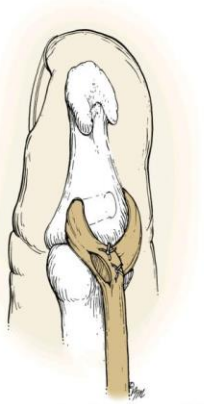

Fig. 6.31 Distal juncture technique. Tendon graft, which must be thin, is passed through transverse drill hole in distal phalanx. (Copyright © Elizabeth Martin.)

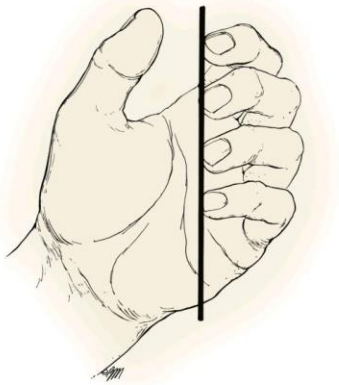

Fig. 6.33 Determining tension in a reconstructed flexor system at the time of suturing the proximal juncture. With the wrist in neutral position, each finger falls into slightly less flexion than its ulnar neighbor. (Copyright © Elizabeth Martin.)

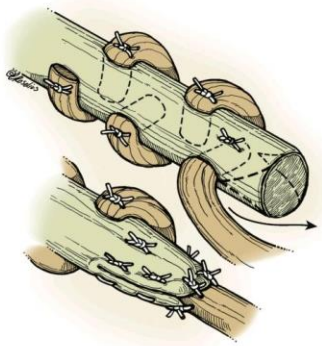

Fig. 6.32 Modified Pulvertaft end-weave technique. The graft is secured to the proximal motor tendon via multiple weaves through the motor tendon held in place with 3-0 polyester sutures. (Copyright © Elizabeth Martin.)

relevant canine model.[179] Traditional extrasynovial grafts, such as palmaris longus or plantaris tendon grafts, undergo a significant cellular necrosis when transplanted to the digital sheath and are repopulated by fibroblasts donated through the formation of peritendinous adhesion or through the proximal tendon juncture sites. Similarly, studies of tendon graft neovascularization show new vessels growing to the tendon graft through adhesion formation and also through the tendon junctures. These newly donated fibroblasts are responsible for producing collagen that will strengthen the graft over time. Intrasynovial grafts have, in basic science study and limited clinical study, showed an improved capacity to survive transplantation to the digital sheath. They have a surface that is designed to allow for synovial fluid imbibition and that may promote nutrition and cellular survival. It may also explain the ability of these grafts to incorporate with much less cellular necrosis or adhesion formation and with maintenance of the critical gliding surface.[179]

Single-Stage Flexor Tendon Grafting: Flexor Digitorum Profundus Tendon Disrupted, Flexor Digitorum Superficialis Tendon Intact

Indications

In patients with transection or avulsion of the FDP tendon but an intact FDS tendon, early direct FDP repair is the preferred treatment method. When more than 4 weeks have elapsed from the time of injury, tendon grafting may be necessary and, depending on the status of the tendon sheath, can be done as a one- or two-stage procedure. When the FDS tendon is functional, caution must be exercised in offering a free tendon graft to restore distal joint function.[200]

Useful digital motion is maintained when the FDS tendon is functional (Fig. 6.34). Most patients with a severed FDP tendon but an intact FDS tendon adapt nicely and may require no treatment; this is especially true if the DIP joint is stable. An appropriate preoperative explanation of the considerable risk of worsening function after attempted reconstruction of the isolated FDP laceration is essential. Most surgeons advise nonoperative treatment, especially in older patients or heavy laborers.[201] In patients troubled by instability at the DIP joint or weakness of grip, stabilization of the DIP joint by tenodesis or arthrodesis is a good solution. Despite the difficulties and considerable risks, outstanding results with FDP grafting in carefully selected patients have been reported.[76,103,191,202-206] Some of the variability in patient results may be attributed to different methods of patient evaluation.[200]

3) Na luxação metacarpofalangeana dorsal irredutível (complexa) do polegar, o motivo mais frequente é a interposição

a) da polia A1
b) o tendão flexor longo do polegar
c) de fragmento ósseo
d) da placa volar

Resposta D

referência Green página 358

AUTHOR'S PREFERRED METHOD OF TREATMENT: RADIAL COLLATERAL LIGAMENT INJURIES

The principles of treatment are similar to those for the UCL. Partial tears of the RCL are treated by immobilization of the MP joint full time for 4 weeks in either a thumb spica cast or splint. A splint is worn the majority of the time for an additional 2 weeks during which active range-of-motion movement in flexion and extension is begun. The literature does not resolve the question of whether all complete tears of the RCL need to be repaired. Casting is typically effective in the lower-demand patient, although I do routinely offer surgical repair when there is lack of a firm endpoint or significant laxity on examination for most patients. Complete tears with volar subluxation of the MP joint should be repaired. Patients with symptomatic chronic RCL instability are also offered surgery unless they are elderly or sedentary and are satisfied with a splint. Surgical options for the chronically insufficient RCL are similar to the UCL: tendon graft reconstruction or arthrodesis (particularly if there is already degenerative wear of the cartilage).

Historical Perspective

Most dislocations of the thumb MP joint are dorsal, although volar dislocation has been reported and may be irreducible.[112] The mechanism of dorsal dislocation is hyperextension, with complete rupture of the volar plate, capsule, and at least part of the collateral ligaments. Rupture of the volar plate usually occurs proximally but can be midsubstance or distal to the sesamoid bones. Most dorsal dislocations are reducible, although some are more complex injuries and are irreducible. Reduction is blocked typically by the interposed volar plate and less commonly by the flexor pollicis longus. The flexor pollicis longus tendon more often remains within the flexor tendon sheath and displaces to the ulnar side of the metacarpal head, creating a "noose" around the metacarpal neck together with the radially displaced thenar intrinsic musculature. Volar dislocations have been described and in some cases may be reduced without surgery.[113]

Preoperative Evaluation

Diagnosis of an MP joint dislocation is generally not difficult. Clinically, the MP joint has an obvious hyperextension deformity and the metacarpal is adducted. There may be dimpling of the skin on the volar aspect of the MP joint that is suggestive of a complex dislocation. Radiographs typically show the MP joint to be hyperextended, with the proximal phalanx dorsal and sometimes lying in "bayonet" apposition to the metacarpal. There may be an increased space between the metacarpal head and the proximal phalanx suggestive of interposed soft tissue. Interposition of the sesamoids between the metacarpal head and the proximal phalanx is evidence of a complex, irreducible dislocation.

Treatment Options

The majority of dorsal dislocations may be easily reduced without surgery. Simple longitudinal traction as a reduction maneuver should be avoided because it might convert a simple dislocation into an irreducible complex one. The preferred reduction technique is hyperextension of the MP joint, followed by direct pressure on the dorsal base of the proximal phalanx to gently push it over the metacarpal head.

Less severe hyperextension injuries can cause dorsal subluxation of the MP joint rather than frank dislocation. This may present as a locked MP joint in which the joint cannot be flexed actively or passively. The pathoanatomy is thought to be entrapment of the radial condyle in a tear of the radial part of the volar plate, proximal to the sesamoid. Closed reduction may be attempted with regional anesthesia or a lidocaine block of the MP joint. The examiner applies volar-directed pressure on the proximal phalanx while twisting it on the metacarpal head.[114] If closed reduction fails, open reduction may be necessary and may be done through several approaches.

The surgical approach may be dorsal, volar, or lateral. Bohart and colleagues[115] prefer the dorsal approach because of its simplicity. A longitudinal skin incision exposes the extensor tendons. The interval between the extensor pollicis longus and extensor pollicis brevis tendons is utilized. The dorsal capsule is incised. The tissue interposed in the joint is identified and mobilized using blunt instruments such as hooks, forceps, and periosteal elevators. The tissue is pushed over the metacarpal head and the joint is reduced. Occasionally, a dorsal MP dislocation will present with a volar laceration that necessitates extension and debridement of the volar wound. The proximal phalanx is hyperextended, and the interposed soft tissue is extricated from the joint. The advantage of the volar approach is that it allows the interposed structures to be pulled from within the joint and affords an excellent view of the neurovascular bundles, tendons, and affected structures.[116] Once reduced, the joint is usually stable, but if not, ligament and volar plate repair may be performed.

AUTHOR'S PREFERRED METHOD OF TREATMENT: METACARPOPHALANGEAL DISLOCATION OF THE THUMB

Closed reduction is usually successful with the following technique. Under radial and median nerve wrist block or Bier block anesthesia, distally directed pressure is applied to the base of the proximal phalanx with the metacarpal in a position of flexion and adduction. This maneuver relaxes the noose that the thenar muscles and flexor pollicis longus occasionally create around the metacarpal neck. If necessary, flexing the IP joint and the wrist will relax an entrapped flexor pollicis longus tendon that is blocking reduction. After reduction, collateral ligament stability is tested and a congruous reduction confirmed by radiographs. Stability is assessed by extending the joint to determine the point at which it starts to subluxate. The thumb should be fitted with a dorsal block splint in 10 degrees more flexion than the point of instability. The thumb may then be extended 10 degrees per week. If there is significant collateral ligament instability, consideration should be given to immobilization of the MP joint for 4 weeks or open collateral ligament repair (rarely needed). Open reduction is required when closed reduction fails. If the case presents within 24 hours of injury, we make a small dorsal incision, insert a Freer elevator, and try to push interposed tissue from within the joint. If that fails or if the dislocation is more than 24 hours old, the joint is exposed through a volar zigzag incision. Interposed or entrapped structures are reduced with blunt instruments, avoiding injury to the metacarpal head. Stabilization of the joint in 25 degrees of flexion with a Kirschner wire should be done if the joint is unstable. If the volar plate is detached from the base of the proximal phalanx, surgical repair using bone anchors or repair of surrounding soft tissue is recommended after closed reduction.

Postoperative Management and Expectations

Patients are advised that they will most likely have a stable joint after closed or open reduction. However, stiffness is possible after any dislocation, and the chance of stiffness is greater if surgery is required. Recovery of motion can be slow and may require several months of therapy. Patients should be counseled at the time of injury that stability is a more important consideration than full range of motion of the MP joint. The protocol for rehabilitation is similar to that for acute collateral ligament injury of the MP joint, with a focus on avoidance of

4) Na artrose mediocarpal provocada pelo SNAC e SLAC wrist, o tratamento de escolha é:

a) artrodese dos quatro cantos
b) carpectomia proximal
c) artrodese tri escafóide
d) artrodese escafo-capitato

Resposta A

referência Green página 450

CRITICAL POINTS

Lunotriquetral Arthrodesis

Indications
- Painful partial coalition of the LT joint
- Symptomatic LT dissociative instability (Chapter 13)

Contraindications
- Patients with midcarpal arthritis
- Nondissociative proximal row instability (see Chapter 13)
- LT dissociation secondary to ulnocarpal impaction
- Volar intercalated segment instability

Pearls
- Appropriate reduction will maximize fusion mass in hopes of successful union.
- I prefer the use of autograft, primarily from the distal radius.

Technical Points
- The use of bone graft is helpful; I prefer to use autograft from the distal radius.
- Make a small incision on the medial wrist and spread the tissues before inserting hardware to prevent injury to the small dorsal cutaneous branches of the ulnar nerve.
- I prefer using one or two headless compression screws or staples over Kirschner wires alone.
- Ensure that the lunate is reduced intraoperatively and that its alignment is neutral in the sagittal plane.
- Avoid overcompression of the LT interval.
- Time to union may be significant. If Kirschner wires are utilized, burying them postoperatively can be helpful in minimizing pin irritation or pin track infections, thus minimizing the need for early pin removal.

Postoperative Care
- The patient is immobilized in the postoperative dressing for approximately 2 weeks.
- At 14 days postoperatively, if an LT fusion was an isolated procedure, a short-arm cast is applied. If a procedure in the forearm is performed or a stabilizing procedure of the distal radioulnar joint is performed, a muenster cast may be indicated.
- At 6 to 8 weeks postoperatively, the patient will graduate to a removable splint and initiate supervised therapy.

Expectations
- Residual symptoms may persist after successful LT fusion due to the complexity of ulnar sided wrist pain.
- Most patients will achieve 75% to 80% of contralateral wrist motion.
- Grip strength should be approximately 80% of contralateral side.
- Likely full use will be allowed at 4 months postoperatively.
- Full recovery will take approximately 9 to 12 months.

Pitfalls
- Neuroma or neuropathic pain from ulnar sensory branch injury
- Failure to diagnose concomitant ulnar impaction syndrome
- A nonunion rate of 30%[35]
- A loss of 30% to 40% range of motion
- Results are somewhat unpredictable.
- Recovery takes 9 to 12 months.
- The pain may not be entirely relieved.

with triquetrohamate fusion[47]; therefore this operation is not recommended. The author's experience mirrors that of these investigators.

Capitohamate Arthrodesis

Like triquetral hamate arthrodesis, capitohamate fusions are a less common intercarpal arthrodesis. It has been proposed in the treatment of Kienböck disease, stage IIB and IIC.[48] This preliminary report of eight wrists with only 15-month average follow-up period demonstrated encouraging results. These procedures were done in conjunction with lunate excision. Additional and longer-term studies with this arthrodesis will better validate its use.

Scaphoid Excision and Four-Corner Arthrodesis (Luno-Capitate-Triquetrum-Hamate)

The SLAC and SNAC patterns of arthritis generally spare the radiolunate articulation, and therefore luno-capitate-triquetrum-hamate arthrodesis (four-corner fusion) with scaphoid excision has become the procedure of choice for midcarpal joint arthritis.[15,49-53] Excision of the scaphoid must include stabilization of the remaining carpus to prevent gross instability, and this is achieved effectively either through arthrodesis of the ulnar four bones or by luno-capitate fusion alone. Lunocapitate arthrodesis reduces the area of cancellous bone exposed and may be less reliable than four-corner fusion.

Indications

The presence of degenerative changes in the proximal radioscaphoid and midcarpal joints identifies the pattern as SLAC wrist stage III (Fig. 12.12). If the lunocapitate and midcarpal joints are preserved, proximal row carpectomy is an alternative to four-corner fusion (Chapter 13).[49,54,55] However, while controversial, some long-term outcomes with proximal row carpectomy have shown poorer outcomes in patients less than 40 years of age.[55] Painful scaphoid nonunion with the SNAC III pattern of arthritis, as well as the fragmented scaphoid of Preiser disease, are also well served with scaphoid excision and four-corner fusion.

Contraindications

The radio-lunate articulation must be intact and free of disease for four-corner fusion or lunocapitate fusion to succeed.

AUTHOR'S PREFERRED METHOD OF TREATMENT: SCAPHOID EXCISION AND FOUR-CORNER FUSION

A longitudinal incision is made in the line of the third metacarpal. The extensor retinaculum is incised over the third compartment, and the fourth and second compartments are exposed over the carpus. Posterior interosseous neurectomy is performed for pain control by excising a 1-cm segment of the nerve proximal to the dorsal rim of the radius. The anterior interosseous nerve can also be removed at the surgeon's discretion. The fiber-splitting capsulotomy or a longitudinal capsular incision is performed to expose the joint. Since normal kinematics of the wrist are eliminated by a midcarpal fusion, there is no apparent benefit of one capsular/joint exposure technique over the other. Visual inspection of the lunate and the

5) É uma característica da instabilidade carpal não dissociativa:
   a) É uma instabilidade assintomática
   b) Apresenta sempre completa integridade dos ligamentos interósseos carpais conectando os ossos da fileira proximal
   c) A instabilidade mediocarpal pura é a mais comum
   d) Na instabilidade da fileira proximal podemos ter três variedades: VISI, DISI E NEUTRA

Resposta B

referência Green página 537

CRITICAL POINTS

LT Arthrodesis

Indications
- Dynamic LT instability secondary to complete intrinsic ligament rupture in the absence of an ulnocarpal abutment syndrome (i.e., normal TFCC) and normal midcarpal joint

Contraindications
- Radiocarpal or midcarpal arthritis
- Ulnar positive variance
- VISI

Preoperative Evaluation
- Positive LT ballottement test
- Fluoroscopic evaluation of abnormal proximal-distal shift of the triquetrum during radioulnar inclination
- Arthroscopy to rule out TFCC degeneration, ulnocarpal impaction, or triquetrum-hamate impingement

Technical Points
- Perform a dorsal (e.g., zigzag, lazy "S," or longitudinal) incision centered at the IV-V septum.
- Perform a longitudinal incision of the extensor retinaculum along the V compartment.
- Open the septum between IV and V; coagulate intraseptal artery. Perform a PIN neurectomy if the nerve appears damaged or has a neuroma. Limited capsulotomy to expose the LT joint.
- Complete section of the remnants of LT ligaments.
- Open the LT as a book and remove the adjacent articular surfaces with a dental rongeur or high-speed bur with copious saline irrigation to expose cancellous bone. Do not excise the rim of the opposing cortical edges to preserve the normal intercarpal separation.
- Harvest cancellous bone from the radius.
- Two 0.062-inch nonparallel Kirschner wires are preset in the ulnar aspect of the triquetrum. Beware of the dorsal branch of the ulnar nerve.
- Bone graft is densely packed in the biconcave cavity.
- The joint is reduced, and the Kirschner wires are driven into the lunate and their position verified.
- One wire is used to insert a headless cannulated compression screw.
- Cut the second wire below the skin's surface.
- Perform standard capsular and retinacular closure.

Postoperative Regimen
- Short-arm thumb spica cast for at least 6 weeks, changed at 10 days for stitch removal and radiographs
- At 6 weeks, cast removal, radiographs, and new cast applied
- Follow with out-of-plaster radiographs until healing is obvious, confirm with CT scan, and remove Kirschner wire under local anesthesia.
- Rehabilitation after cast removal to regain motion and grip strength
- Contact sports not allowed until 6 months postoperatively.
- If successful: 75% of patients have a painless wrist with 80% of global motion and 75% grip strength.
- Caution: high rate of complications and nonunion

Stage 3: chronic LT dissociation with carpal collapse. LT dissociation with carpal collapse is secondary to complete disruption of all portions of the LT interosseous ligament and attenuation or disruption of the dorsal and palmar intrinsic and extrinsic stabilizing ligaments—predominantly the DRC and ulnar arcuate ligaments. As a result of such a global ligament insufficiency, the carpus collapses into a dissociative VISI pattern of malalignment. As the underlying pathology involves the intrinsic and extrinsic ligaments, fusion of the lunate and triquetrum is unsuccessful in reducing VISI. Neither an isolated fusion of the LT joint nor any sort of tendon reconstruction is likely to reliably correct such a complex unstable condition in maintaining control of the lunate. Halikis and associates recommended RL fusion for static dissociative VISI.[206] Excision of the triquetrum could be considered in this situation and utilized as bone graft.

AUTHORS' PREFERRED METHOD OF TREATMENT: LT DISSOCIATION

We believe that acute complete tears of the LT ligaments are best treated by above-elbow cast immobilization alone or with arthroscopically assisted percutaneous LT joint fixation with Kirschner wires. The potential for improved ligament healing by more rigid fixation may outweigh the potential morbidity of pinning the joint. Temporary cannulated screw fixation of the LT joint may enable earlier mobilization of the wrist. We are not aware of any comparative outcome studies of above-elbow casting versus temporary fixation for acute complete LT injuries.

For chronic instability without carpal collapse, we recommend ligament reconstruction (see Fig. 13.47)[201] or tenodesis[203] using the ECU tendon. Ligament reconstruction is an anatomically sound solution for chronic, dynamic LT dissociation because it replaces the most important stabilizer of the joint—the palmar LT ligament.

We seldom perform LT fusions, owing to the substantial rate of complications. When there is no other alternative than fusing the joint, we prefer the method described by Guidera et al.,[204] in which the empty space left in the LT joint, after resecting cartilage and subchondral bone from the central portion of the two articular surfaces, is filled with abundant, tightly packed cancellous bone graft obtained from the distal radius. The procedure is modified by the addition of a single cannulated screw to one or more Kirschner wires.

For patients with stage 3 static deformities, we recommend against an LT fusion. Our first choice would be RL fusion for static VISI deformity.[44] Others prefer midcarpal fusion for static VISI deformity.

NONDISSOCIATIVE CARPAL INSTABILITY (CIND)

A painful wrist is said to have a nondissociative pattern of instability when there is dysfunction of the radiocarpal and/or the midcarpal joints with complete integrity of the interosseous ligaments connecting the bones within the proximal row.[16,30,74,76,77,135] Depending on which joints are affected, CIND problems can be further subdivided into radiocarpal, combined radiocarpal-midcarpal (or more simply, proximal row instability),[75] and rarely pure midcarpal instability (Fig. 13.48). Proximal row instability has two distinct varieties: CIND-VISI (i.e., flexion rotation of the proximal row with a tendency of the capitate to subluxate volarly) and CIND-DISI (i.e., extension rotation of the proximal row with a dorsal capitate subluxation).

Radiocarpal Instability

Nondissociative radiocarpal instability occurs in patients with excessive laxity, insufficiency, or rupture of the radiocarpal ligaments. In these cases, the entire carpus can be displaced beyond normal limits down the volar or ulnar inclination of the radius. With time, further stretching of the capsule may occur, and the carpus becomes permanently translocated.[77,78] This condition is most commonly seen in patients with inflammatory arthritis (Fig. 13.49) or in patients with developmental deformities such as the Madelung deformity. Posttraumatic radiocarpal instability is less frequent, most often associated with a radiocarpal

6) A técnica para reconstrução da instabilidade crônica da articulação radioulnar distal representada na figura abaixo é descrita por:

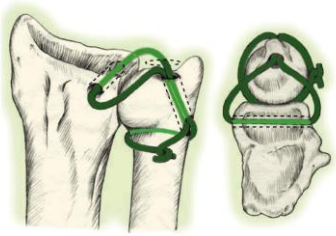

a) Shecker e colaboradores e serve para reconstrução do ligamento radioulnar volar
b) Hui e Linscheid e serve para reconstrução do ligamento radioulnar dorsal
c) Boyess e Bunnell e serve para reconstrução dos ligamentos radioulnares volar e dorsal
d) Adams e Berger e serve para reconstrução dos ligamentos radioulnares volar e dorsal

Resposta D

referência Green página 579

A modification of the press test,[47] originally described to diagnose TFCC tears, is useful for evaluating suspected DRUJ instability.[2] In this modified test, the patient rises from a chair using the hands for assistance by pushing against a tabletop directly in front of them. Instability is shown by greater "depression" of the ulnar head on the affected side and is often associated with pain. Tenderness over the ulnar styloid may be associated with an unstable nonunion. In a dorsally angulated malunion of the distal radius, the ulnar head may be prominent palmarly, especially with supination.

The most specific radiographic signs of instability include a widened DRUJ and a prominent ulnar head volar or dorsal to the radius. Indirect radiographic signs include a malunited distal radius, deformities of the radial or ulnar shafts, displaced basilar fracture of the ulnar styloid, and a displaced avulsion fracture from the fovea. CT imaging in supination, pronation, and neutral is the most accurate imaging modality to evaluate the DRUJ for instability.[60-62] (See Imaging section earlier in the chapter.)

Treatment

Nonoperative management of severe, chronic DRUJ instability usually fails, unless the individual is willing to use a splint that restricts forearm rotation. A 4- to 6-week trial of forearm splinting or long-arm casting and antiinflammatory medications is indicated for mild instability, particularly in a low-demand patient.[121] Coexistent conditions, such as ECU tendinitis or ulnar impaction syndrome should be identified and treated accordingly. Special consideration is given to patients with symptoms of instability who have a flat sigmoid notch and bilateral DRUJ hypermobility because these patients respond less predictably to reconstructive surgery. Advanced imaging (MRI) may assist in evaluating articular congruity while considering the influence of articular cartilage thickness on joint morphology.[7] To take advantage of the dynamic DRUJ stabilizers, a strengthening program for the forearm and wrist along with supportive soft bracing or taping during activities can be considered. Recurrent dislocations may cause further attenuation of the soft tissue restraints and predispose to degeneration of the articular cartilage and the rims of the sigmoid notch.

Restoration of stability and a full, painless arc of motion are the goals of surgical treatment for a posttraumatic unstable DRUJ. The anatomic derangements underlying the instability must be identified correctly, including bony deformity, ligament injury, and combinations. In established DRUJ instability without malunion or arthritis, late repair of a class 1B TFCC tear is an option if its radioulnar ligament components are otherwise robust, with the goal to restore their mechanical integrity.[73] Soft tissue repair or reconstruction in the presence of marked bony deformity, however, will likely fail.

A soft tissue reconstructive procedure is indicated when the TFCC is irreparable and the sigmoid notch is competent. Reconstructive techniques can be classified into three categories: (1) a radioulnar tether that is extrinsic to the joint,[122] (2) an indirect radioulnar link via an ulnocarpal sling or a tenodesis,[123-125] or (3) reconstruction of the distal radioulnar ligaments.[2,126,127] The techniques in the first two categories may improve symptoms, but are not anatomic and do not restore normal joint stability or mechanics in laboratory studies.[128] Nonetheless, these reconstructions may be the only option in some cases and are occasionally used in conjunction with a Darrach excision of the distal ulna or to stabilize a previously resected distal ulna.[129]

A radioulnar tether is created using a technique described by Boyes and Bunnell[122] (Fig. 14.21). The ulnocarpal tenodesis techniques are exemplified by the Hui and Linscheid technique[124] (Fig. 14.22) using a distally based strip of the FCU tendon to reconstruct the volar ulnocarpal ligaments. These techniques are particularly applicable when ulnocarpal instability is the primary problem, and DRUJ instability is a lesser concern.

Reconstruction of the distal radioulnar ligaments is the most anatomic approach and has the greatest potential to restore stability without substantial loss of rotation or strength.

Scheker and associates[127] described a technique for reconstruction of the dorsal radioulnar ligament using a tendon graft. The tendon graft is threaded through holes at the anatomic insertion points of the DRUL on the radius and the ulnar fovea, then threaded through two additional holes on the radius and ulnar shafts and tied to itself. In a subsequent modification, both arms of the radioulnar ligaments were reconstructed anatomically and tied to themselves at the radial and ulnar metaphyses.[130] A technique developed by Adams and Berger reconstructs the anatomic origin and insertion of the palmar and dorsal radioulnar ligaments using a palmaris tendon graft.[2] (See Author's Preferred Method of Treatment: Distal Radioulnar Ligament Reconstruction and Fig. 14.23.) Each of these procedures is dependent on a mechanically competent sigmoid notch to provide a buttress effect for proper ligament function. If the notch is not competent, either an osteoplasty of the sigmoid notch must be done concurrently or another surgical option considered (see Osteoplasty of the Sigmoid Notch and Ulna).

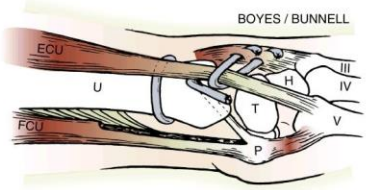

Fig. 14.21 Technique described by Boyes and Bunnell[122] for chronic distal radial ulnar joint instability reconstructs volar ulnocarpal ligaments and creates a tether between the distal radius and ulna. *ECU,* Extensor carpi ulnaris; *FCU,* flexor carpi ulnaris; *H,* hamate; *P,* pisiform; *T,* triquetrum; *U,* ulna; *III,* long finger metacarpal; *IV,* ring finger metacarpal; *V,* small finger metacarpal. (From Petersen MS, Adams BD: Biomechanical evaluation of distal radioulnar reconstructions, *J Hand Surg Am* 18[2]:328–334, 1993.)

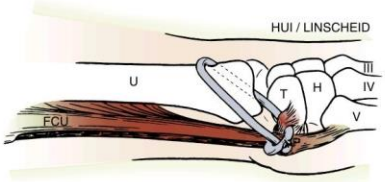

Fig. 14.22 Hui and Linscheid procedure reconstructs volar ulnocarpal ligament using strip of flexor carpi ulnaris tendon. It is particularly useful for primary ulnocarpal instability and secondary distal radial ulnar joint instability. *FCU,* Flexor carpi ulnaris; *H,* hamate; *P,* pisiform; *T,* triquetrum; *U,* ulna; *III,* long finger metacarpal; *IV,* ring finger metacarpal; *V,* small finger metacarpal. (From Petersen MS, Adams BD: Biomechanical evaluation of distal radioulnar reconstructions, *J Hand Surg Am* 18[2]:328–334, 1993.)

7) Na classificação artroscópica de Slade e Geissler para pseudartrose do escafóide, observamos uma união fibrosa com uma linha de fratura mínima no tipo

a) 1
b) 2
c) 3
d) 4

Resposta B

referência Green página 696

preserve the volar radiocarpal ligaments and prevent carpal instability.[127] In a recent study of 21 chronic scaphoid nonunions with SNAC arthritis, all 10 proximal pole nonunions had >6 mm of exposed bone on the radial styloid, obviating the use of radial styloidectomy as safe treatment.[128] With advanced arthritis, nonoperative management may be considered if symptoms are not severe. With increasing pain, other options may include partial denervation or salvage procedures such as scaphoid excision and four-bone fusion, proximal row carpectomy, total wrist fusion, hemiwrist arthroplasty, and total wrist arthroplasty.

Patient parameters to consider when evaluating scaphoid nonunions include:

1. Length of time nonunion has been present
2. Amount of pain or dysfunction
3. Activity level
4. Systemic comorbidities present

Length of time nonunion has been present. The longer the nonunion has been present, the more likely it is that there will be secondary issues such as arthritis, scaphoid deformity, and carpal instability. In a study by Mack and colleagues, older nonunion was associated with more severe arthritis.[20]

Amount of pain or dysfunction. The intensity, duration, and frequency of pain should be recorded in all four life domains: sleep, work, activities of daily living, and hobbies/athletic pursuits. When the only option may be a partial or complete wrist fusion, nonoperative treatment can be continued as long as the level of pain and dysfunction is tolerable. A salvage procedure or wrist arthroplasty may always be performed later.

Activity level. Elderly, inactive, or infirm patients may choose to accept the pain and limited range of motion of a scaphoid nonunion. There is no mandate for operative repair because salvage operations may always be considered if escalating arthritic pain causes increasing impairment.

Presence of comorbidities. Scaphoid nonunion surgery can be complex and complicated, and the best efforts may be thwarted by heavy tobacco use, poor compliance, uncontrolled diabetes or inflammatory arthritis, steroid dependency, or other factors.

Operative Treatment of Scaphoid Nonunion

Classification

Several classification schemes have been proposed for scaphoid nonunion, generally based on factors such as time since injury, mobility of the fragments, cystic or flexion deformity, and degenerative change. Two such classification systems are listed in Tables 16.2 and 16.3. Table 16.4 presents a four-part practical classification and treatment algorithm based on fracture nonunion characteristics and vascularity.

Type I: delayed or fibrous union, no deformity. Scaphoid nonunions without substantial bone loss require only rigid fixation to heal if there is adequate perfusion. These include fractures with a delayed presentation, fibrous unions, and nonunions with minimal sclerosis (<1 mm). Stable scaphoid fractures presenting for treatment after 1 month may have already developed bone resorption at the fracture site and have a poorer union rate with casting alone. Selected stable scaphoid delayed unions without deformity or bone loss can be successfully treated with reduction and internal rigid fixation without bone grafting using techniques described for acute fractures above. Scaphoid nonunions that have minimal bone resorption of the anterior cortical bone and minimal fracture sclerosis (<2 mm confirmed by CT scan) still have the potential for healing in the early stages with screw fixation alone. Slade and coworkers successfully treated aligned nonunions without bone loss using headless screw fixation and no bone graft. All 15 patients in this case series healed at an average of 14 weeks with bridging cortical bone on CT.[88]

TABLE 16.2 Slade and Geissler Classification of Scaphoid Fracture Nonunion

Type	Description
Type 1	Delayed presentation for 4–12 weeks
Type 2	Fibrous union, minimal fracture line
Type 3	Minimal sclerosis of less than 1 mm
Type 4	Cystic formation of 1–5 mm
Type 5	Humpback deformity with cystic change of more than 5 mm
Type 6	Wrist arthrosis

From Geissler WB. Arthroscopic management of scaphoid fractures in athletes, *Hand Clin* 25(3):359–369, 2009.

TABLE 16.3 Alnot Classification of Scaphoid Fracture Nonunion

Grade	Description
I	Linear nonunion without altered scaphoid form, instability, or intracarpal malalignment
IIA	Stable nonunion with incipient bone resorption at fracture line, without instability or malalignment
IIB	More or less mobile nonunion with anterior defect and proximal pole flexion on distal tubercle inducing DISI
III	More or less mobile displacement nonunion with instability or reducible malalignment with
	IIIA: isolated styloscaphoid arthritis
	IIIB: radial and/or intracarpal arthritis
IV	Proximal fragment necrosis with
	IVA: malalignment
	IVB: radioscaphoid and/or intracarpal arthritis

DISI, Dorsal intercalated segmental instability.
From Gras M, Mathoulin C. Vascularized bone graft pedicled on the volar carpal artery from the volar distal radius as primary procedure for scaphoid non-union, *Orthop Traumatol Surg Res* 97(8):800–806, 2011.

TABLE 16.4 Classification and Algorithm for Scaphoid Nonunion Management

Type of Fracture	Treatment
I. Delayed union	Mini-open rigid fixation with headless compression screw
IIA. Established waist nonunion, no deformity, no arthritis	Open repair and autogenous bone grafting Dorsal or volar
IIB. Established waist nonunion, humpback deformity, no arthritis	Volar approach Russe or Matti-Russe corticocancellous autograft Intercalated wedge autograft Hybrid Russe autograft
III. Proximal pole nonunion, viable	Dorsal approach Open bone grafting and fixation with headless screw Percutaneous bone grafting with headless screw Immobilize midcarpal joint with Kirschner wire(s)
IV. Dysvascular nonunion, waist, or proximal pole	Nonvascularized vs vascularized bone graft: dorsal or palmar approach Osteoarticular graft

8) Uma das principais vantagens do acesso medial ao cotovelo "*over-the-top*" para capsulotomia do cotovelo é:

a) Proteger o nervo ulnar
b) Possibilitar bom acesso a cabeça do rádio
c) Facilitar a remoção de osso heterotópico tanto medial quanto lateral
d) Possibilita acesso ao nervo radial

Resposta A

referência Green página 1013

method. If the patient has a simple flexion contracture related to a radial head fracture, the lateral approach is usually sufficient and is relatively simple to perform.[18,43-46] In more complex cases in which the ulnar nerve requires exposure, I usually begin with the medial "over-the-top" exposure.[8,47,48] I am always prepared to use a supplementary lateral approach in these cases if there is HO located on the lateral side, if I am concerned about the position and safety of the radial nerve, or if there is an impinging osteophyte behind the capitellum. It is therefore important to understand both the medial and lateral approaches and be able to use them as needed in the operating room. Both a transhumeral and a transolecranon approach have been described, but I have not used either.[49,50] I also no longer use the Outerbridge-Kashiwagi procedure[51] (transhumeral trephination), which is designed to treat patients with primary arthritis of the elbow. If there is a significant lack of flexion (limited to <90 degrees), evidence of ulnar nerve dysfunction, or osteophytes in the posteromedial joint line, I prefer the medial "over-the-top" approach. As described in the next section, this approach permits exposure of the ulnar nerve and access to the anterior and posterior osteophytes. If flexion is minimally limited and the ulnar nerve is palpable and mobile, I prefer arthroscopic debridement and contracture release.

Only rarely can contracture be treated with anterior capsulectomy alone. Of the more than 480 contractures that I have treated operatively over the past 10 years, only a handful were adequately freed by incising the anterior capsule alone. In most instances, you should always plan to have access to the posterior joint surface, whether from the medial or lateral side of the joint. The olecranon fossa must be free of bone and soft tissue for full terminal extension to be achieved.

The advantage of knowing and using both the medial and lateral approaches is that you can protect the anterior medial ligament on the medial side by using the medial "over-the-top" approach. From the lateral exposure, the lateral ligaments described as noted by Husband and Hastings[44] and others[18,46] can be protected.

Medial "Over-the-Top" Approach

The principal advantages of this approach are as follows:

- Allows exposure, protection, and transposition of the ulnar nerve
- Preserves the anterior medial collateral ligament
- Preserves the posterolateral ulnohumeral ligament complex
- Permits both anterior and posterior access to the joint
- Allows access to the coronoid and anterior osteophytes with an intact radial head
- Can be easily converted to the triceps-sparing exposure of Bryan-Morrey, which permits complete dislocation of the joint and a more extensile approach (for total elbow replacement)
- The disadvantages are as follows:
- Difficult to remove heterotopic bone or osteophytes on the lateral side of the joint
- Poor access to the radial head

Patient position and preparation. The patient is usually supine with the arm supported by a hand table (Fig. 24.3A). It is helpful to bring as much of the patient as possible onto the hand table. The patient's head may require support with a small foam ring because a standard pillow projects too far toward the shoulder and impedes the skin preparation. Two folded towels should be placed under the ipsilateral scapula to lift the shoulder away from the surgical table. The preparation should include the axilla to allow a sterile tourniquet to be applied. For the surgeon to visualize the anterior and posterior surfaces of the distal humerus, the patient should have fairly free external rotation of the shoulder. In some cases, with a concomitant frozen or stiff shoulder, a proper manipulation the shoulder under anesthesia preceding the elbow release can help restore shoulder motion, especially external rotation.

Skin incision and superficial exposure. The skin incision for this exposure can vary between the boundaries of a pure posterior skin incision and a midline medial incision (see Fig. 24.3B). The key to this exposure is identification of the medial supracondylar ridge of the humerus (see Fig. 24.3C). At this level one can locate the medial intermuscular septum, the origin of the flexor-pronator muscle mass, and the ulnar nerve. This location also serves as the point to begin the subperiosteal extracapsular dissection of the joint for both the anterior and posterior surfaces.

Once the subcutaneous skin is elevated, the first structure to identify is the medial intermuscular septum. If the skin incision is more posterior, the medial intermuscular septum can be found by locating the aponeurosis of the triceps tendon 2 to 3 cm proximal to the medial epicondyle and gently spreading with scissors anteriorly. Anterior to the septum and running immediately on top of the fascia (and not in the subdermal tissue) is the medial antebrachial cutaneous nerve, which usually has several branches. Generally this nerve can be traced distally and protected in this approach, but the branching pattern varies. It is occasionally necessary to divide this nerve to gain full exposure and adequately mobilize the ulnar nerve, especially in revision surgery. If nerve excision is required, the nerve should be divided as far proximally as the skin incision will allow while ensuring that the cut nerve end lies in the subcutaneous fat. If the patient has had previous surgery, the ulnar nerve should be identified proximally before proceeding distally. If a previous anterior transposition has been performed, the nerve should be fully identified and mobilized before proceeding. In this setting, the nerve is flattened over the medial flexor-pronator muscle mass. Great care is needed to dissect the nerve in this location.

Once the medial intermuscular septum has been identified proximally, the surface of the origin of the flexor-pronator muscle mass can be found by dissecting at this same level and sweeping the subcutaneous tissue laterally. In most cases the medial antebrachial cutaneous nerve will be in this flap of subcutaneous tissue. The nerve will generally cross to the posterior aspect of the elbow distal to the epicondyle and can be elevated with the flap and retracted out of harm's way.

The medial intermuscular septum can now be excised from its insertion on the supracondylar ridge to the proximal extent of the wound, usually about 5 cm. There are many veins and perforating arteries at the most distal portion that require cautery. The septum can be cleared of muscle by using a small Cobb elevator along the posterior surface above the ulnar nerve.

Anterior capsular exposure. The supracondylar ridge is located, and the anterior muscle is elevated with a wide Cobb elevator (see Fig. 24.3D). All the anterior structures in the distal humeral region are elevated sufficiently subperiosteally to allow placement of a wide Bennett retractor. The median nerve, brachial vein, and brachial artery are superficial to the brachialis muscle. Once the septum is excised, the flexor-pronator muscle mass is divided parallel to its fibers, with a span of approximately 1.5 cm of flexor carpi ulnaris tendon left attached to the epicondyle. A tag stitch can be used to help align the tissues at closure. A small cuff of fibrous tissue of the origin can be left on the supracondylar ridge as the muscle is elevated. This facilitates reattachment when closing. A proximal transverse incision in the lacertus fibrosus may also be needed to adequately mobilize this layer of muscle. The flexor-pronator origin should be dissected down to the level of bone but superficial to the joint capsule. As this plane is developed, the brachialis muscle will be encountered from the underside. This muscle should be kept anterior and elevated from the capsule and anterior surface of the distal humerus.

9) Os cinco sítios em que o nervo radial pode ser comprimido no cotovelo são:
   a) Ligamento de Struthers, arcada de Frohse, plexo venoso de Henry, ligamento de Osborne e músculo supinador
   b) Septo intermuscular lateral, arcada de Frohse, músculo supinador e *lacertus fibrosus*
   c) Cabeça lateral do tríceps, aderências fibrosas de Carpener, arcada de Frohse e músculo supinador
   d) Septo intermuscular lateral, aderências fibrosas de Carpener, plexo venoso de Henry, arcada de Frohse e músculo supinador

Resposta D

referência Green página 1116

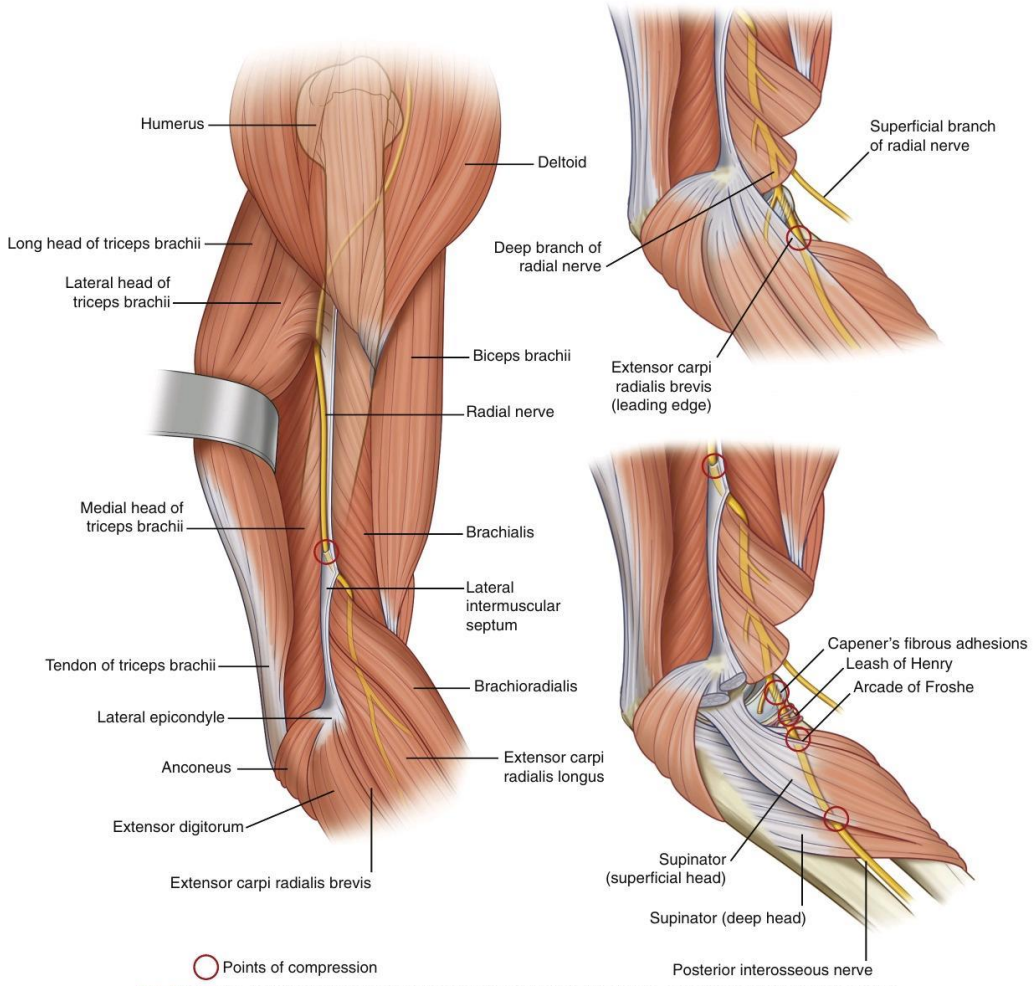

Fig. 28.31 The radial nerve pierces the lateral intermuscular septum 10 cm above the lateral humeral condyle and courses in a groove between the brachialis and brachioradialis muscles.

proximal to the quadrangular space. It lies behind the axillary artery and brachial artery anterior to the long head of the triceps muscle. The radial nerve courses laterally and posteriorly deep to the long head of the triceps and lies deep to the lateral head and superficial to the medial head of the triceps near the spiral groove. After innervating the triceps, the nerve pierces the lateral intermuscular septum and enters the anterior compartment of the arm approximately 10 cm proximal to the lateral epicondyle (Fig. 28.31). The anconeus muscle is innervated proximal to the joint, followed by the brachioradialis muscle and the extensor carpi radialis longus. The radial nerve enters the forearm anterior to the lateral epicondyle between the brachioradialis and brachialis and then divides into its superficial and deep branches just anterior to the capitellum. The takeoff of the DBRN marks the leading edge of the radial tunnel. The extensor carpi radialis brevis is generally innervated distal to the elbow joint, and the supinator branches exit from the nerve just distal to the ECRB branches. Proximal to the supinator, three potential sites of entrapment within the radial tunnel include fibrous bands originating from the lateral epicondyle and coursing superficial to the radial head, a vascular leash (the "leash of Henry") that arises from the radial recurrent artery and arches over the nerve, and the leading fibrous edge of the extensor carpi radialis brevis. Each of these structures should be released or ligated when treating patients with DBRN compression. Distal to the ECRB is the tendinous leading edge of the supinator, also known as the arcade of Fröhse. The DBRN passes

10) No conjunto das transferências tendinosas utilizadas mais frequentemente para a paralisia alta do nervo radial, a transferência que estará sempre presente é a do

a) palmar longo para extensão do polegar
b) pronador redondo para extensão do punho
c) flexor ulnar do carpo para extensão dos dedos
d) flexor radial do carpo para extensão dos dedos

Resposta B

referência Green página 1229

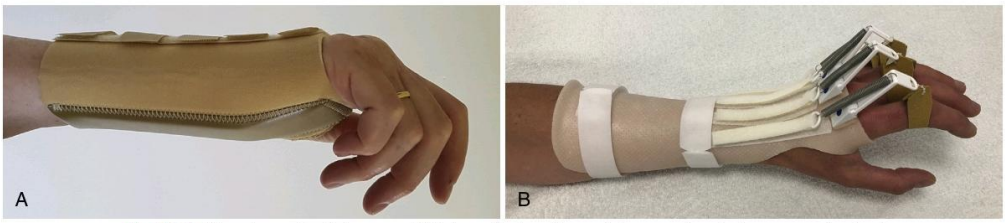

Fig. 31.29 Many types of splints are available for patients with a radial nerve palsy. **A,** For many a standard off-the-shelf wrist splint functions well and is inconspicuous. **B,** More advanced splints provide finger MCP extension and may make tasks like typing easier.

BOX 31.2 Jones Transfers

1916[162]
PT-to-ECRL and ECRB
FCU-to-EDC III–V
FCR-to-EIP, EDC II, and EPL

1921[213]
PT-to-ECRL and ECRB
FCU-to-EDC III–V
FCR-to-EIP, EDC II, EPL, EPB, and APL

APL, Adductor pollicis longus; *ECRB,* extensor carpi radialis brevis; *ECRL,* extensor carpi radialis longus; *EDC,* extensor digitorum communis; *EIP,* extensor indicis proprius; *EPB,* extensor pollicis brevis; *EPL,* extensor pollicis longus; *FCR,* flexor carpi radialis; *FCU,* flexor carpi ulnaris; *PT,* pronator teres.

a more important wrist flexor than the FCR because the normal axis of wrist motion is from dorsal-radial to volar-ulnar. Support for this concept was provided by Brand's biomechanical and clinical studies that led him to believe that the FCU should not be used as a tendon transfer for two reasons: (1) the FCU is too strong and its excursion is too short for transfer to the finger extensors, and (2) its function as the prime ulnar stabilizer of the wrist is too important to sacrifice.[5] Despite these theoretical concerns, studies have shown no functional loss of power grip with the FCU set.[170,171]

Another reason for not using the FCU (or, for that matter, the FCR) set of transfers is that it cannot provide simultaneous wrist and finger extension. Because the amplitude of the wrist flexors is only ~33 mm and the amplitude of the finger extensors is 50 mm, full active extension of the fingers with an FCU or FCR transfer can be achieved only by simultaneous flexion of the wrist, relying on the tenodesis effect of the transfer (Fig. 31.30). Boyes therefore suggested that the superficialis (sublimis) muscles, with their greater excursion (70 mm), would be better motors for finger extensors and devised a combination of transfers that also provided more independent control of the thumb and index finger:

- PT to ECRL and ECRB
- FCR to EPB and APL
- FDS long finger (III) to EDC (via interosseous membrane)
- FDS ring finger (IV) to EPL and EIP (via interosseous membrane)

Tendon Transfers

Three sets of transfers are currently favored for radial nerve palsy (Box 31.3). All use the PT to restore wrist extension. There has been much discussion as to which transfers provide the best finger and thumb extension, but despite potential theoretical benefits and drawbacks for each of the three common transfers (FCR-to-PL, FCU-to-PL, FDS III + IV), all can produce very similar outcomes.[172]

For a patient with PIN palsy, the PT transfer is unnecessary to restore wrist extension. In addition, an isolated PIN palsy provides perhaps the most compelling indication for the FCR transfer; static radial deviation postural deformity may occur when the only remaining ulnar deviator is transferred.

Flexor carpi ulnaris transfer. The first incision in FCU transfer (Fig. 31.31) is directed longitudinally over the FCU in the distal half of the forearm. Its distal end is "J"-shaped, with the transverse extension being long enough to reach the PL tendon. The FCU tendon is transected just proximal to the pisiform and freed up as far proximally as the incision allows. Separation of this muscle from its particularly dense fascial attachments may require the surgeon to extend the first incision more proximally. The muscle belly of the FCU is very long, extending usually to within a few centimeters of the insertion of the tendon on the pisiform. Many facilitate the transfer of this tendon by excising the muscle belly from the distal half of the tendon, which also makes the muscle less prominent as it passes around the ulnar border of the forearm.

The second incision begins 4 cm below the medial epicondyle and angles across the dorsum of the proximal forearm, aimed directly toward the Lister tubercle. The deep fascia overlying the FCU muscle belly is excised, and the remaining fascial attachments to the muscle are incised. It is imperative that the FCU be completely freed up so that its entire muscle belly and tendon can be transferred into the proximal wound to redirect the muscle. The limiting factor in the dissection is the innervation of the FCU, which enters the muscle in its proximal 4 cm, so the dissection must not extend this far proximally.

The third incision begins on the palmar-radial aspect of the midforearm, passes dorsally around the radial border of the forearm in the region of the insertion of the PT, and then angles back radially on the back on the dorsum of the distal forearm toward the Lister tubercle. The tendon of the PT is identified in the palmar aspect of the wound and followed to its insertion on the radius. It is vital that the PT tendon be elongated by freeing up its insertion with an attached long strip of periosteum. This ensures that it has sufficient length to create a strong tendon juncture (Fig. 31.32). Tubiana and colleagues emphasized that the PT muscle-tendon unit must be freed up proximally to divide adhesions to improve subsequent excursion.[173] The PT muscle and tendon are passed subcutaneously around the radial border of the forearm, superficial to the BR and ECRL, to be inserted into the ECRB just distal to its musculotendinous junction.

A tendon passer or large Kelly clamp is passed from the dorsal wound (third incision) subcutaneously around the ulnar border of the forearm, and the tendon of the FCU is pulled into the dorsal wound

11) Dentre os nervos abaixo, o que se origina de raiz cervical é o:

a) Torácico longo
b) Supraescapular
c) Subclávio
d) Peitoral lateral

Resposta A

referência Green página 1305

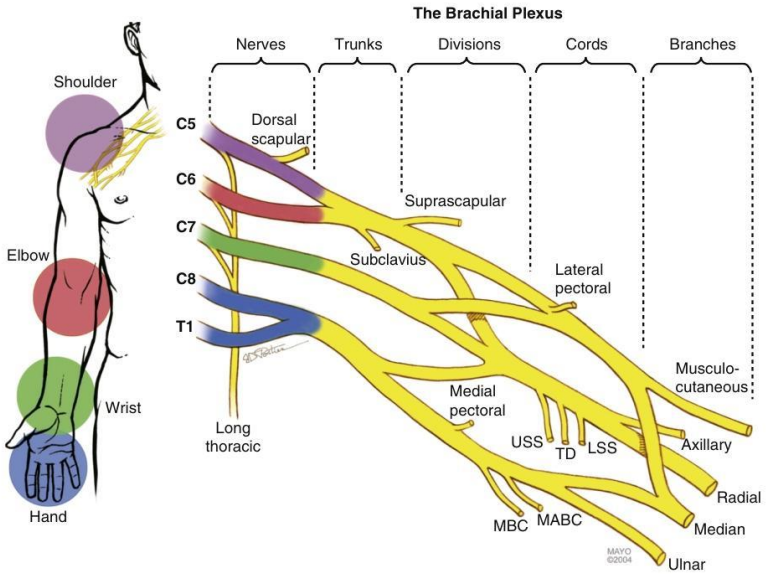

Fig. 34.1 Anatomy of the brachial plexus. Localization of brachial plexus lesions is dependent on detailed understanding of brachial plexus anatomy. This illustration is reviewed with patients at the time of their initial evaluation. *LSS,* Lower subscapular nerve; *MABC,* medial antebrachial cutaneous nerve; *MBC,* medial brachial cutaneous nerve; *TD,* thoracodorsal nerve; *USS,* upper subscapular nerve. (Used with permission of Mayo Foundation for Medical Education and Research. All rights reserved.)

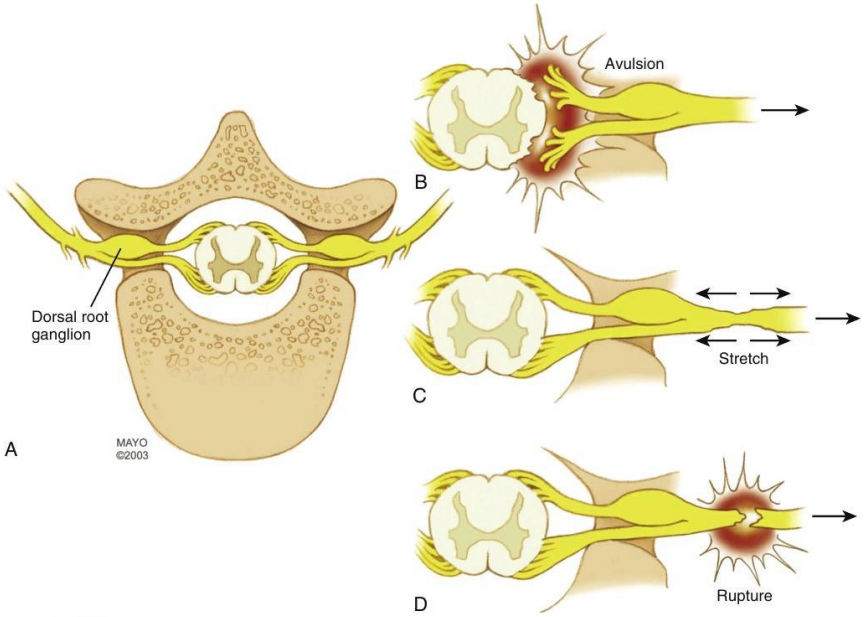

Fig. 34.2 **A** to **D,** Traction injury to the brachial plexus may cause nerve injuries of varying severity in the same patient. Such injuries include avulsion (preganglionic injury) of nerve roots from the spinal cord (for practical purposes, cannot be repaired), stretch (postganglionic injury) of different magnitudes (sometimes spontaneous recovery possible), and extraforaminal rupture of the nerve or trunk (can be repaired with surgery). (Used with permission of Mayo Foundation for Medical Education and Research. All rights reserved.)

12) É um um exemplo de deficiência (ausência) longitudinal a:

a) Simbracdactilia
b) Sindactilia
c) Ausência do polegar
d) Madelung

Resposta C

referência Green página 1402

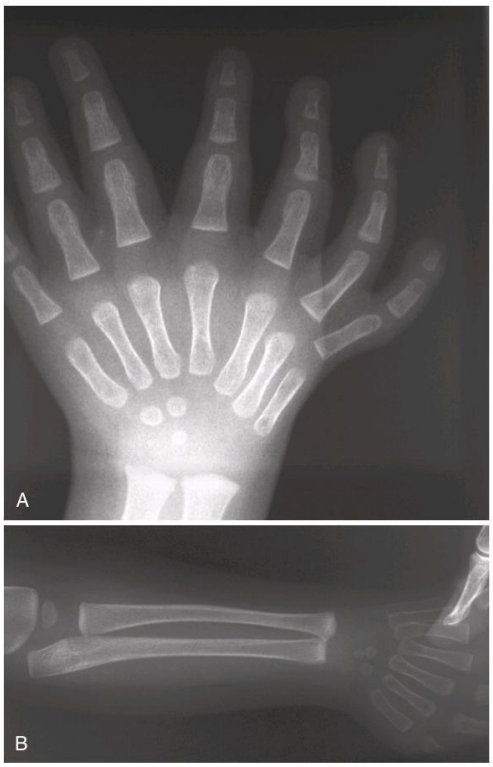

Fig. 36.47 A 2-year-old girl with a left mirror hand. **A,** Hand x-ray showing seven rays and early ossification of the ulnar carpus. **B,** Forearm x-ray showing two ulnae and no true radius. (Courtesy of Shriners Hospital for Children, Philadelphia, Pennsylvania.)

longitudinal structures that are necessary to drive a transferred toe, and the feet are often abnormal. In the cleft foot with a tibial and fibular ray, the fibular ray usually bears weight. Hence, the angulated and abnormal tibial ray may be amputated for shoe wear and is available for transfer. Experience with such free toe transfers is limited.

Surgical management of the feet. The foot deformity in cleft hand often parallels the hand deformity.[128-130] The hand surgeon may or may not be involved in the feet, but his or her opinion is often sought at the time of consultation. Blauth and Borisch have classified the foot deformities that occur with cleft formation into six types. Types I and II have only minor abnormalities without absence of metatarsals, whereas the metatarsals are progressively absent in the remaining types. Type VI is the monodactylous cleft foot with only the fibula ray remaining.[131]

Despite the quite bizarre appearance of the feet, function is remarkably good, and gait is rarely impaired. Cleft foot surgery is indicated for difficulty in footwear fitting secondary to duplication or deviation of the border digits. This may be corrected by either osteotomy or excision of trapezoidal phalanges. As in the hand, resection of a transverse bone leading to progressive widening may be necessary. Surgery may also be indicated for cosmesis with direct closure of the narrow cleft or even obturation of the cleft defect with an alloplastic prosthesis.[132]

The status of the great toe ray or tibial ray presents a challenge in surgical decision making. Commonly, patients have great toe polydactyly with deviation, and a decision is necessary regarding preservation and correction of the tibial ray. In our experience, the fibular ray is always the more important, and the tibial ray may be present but does not participate in weight bearing. In those rare cases that are candidates for a microsurgical transfer from the feet, the feet are often severely affected with only two rays remaining. In these cases, there is reluctance to sacrifice the tibial ray. Nonetheless, this ray can be transferred to the hand, although waiting until the child is older and can undergo gait analysis is prudent.

In summary, surgical treatment for children with central deficiency is challenging but can provide good functional and esthetic results.[133] In more severe forms, ingenuity of the surgeon is required. In these cases, the surgeon must discuss with parents that despite the adverse appearance, children will adapt and learn to use their hands in ingenious ways that were initially considered impossible. Surgery should improve appearance and function or both but should never downgrade either. Surgical correction should be planned according to a schedule that recognizes the urgency of some procedures and the discretionary of other treatments. The overriding determinant of hand function is the first web space, and this forms the basis of the most useful classification. Microvascular transfers from the foot can be useful in highly selected cases. If foot amputation is being contemplated, microvascular transfers of the part in the hand should be considered.

CRITICAL POINTS

Central Hand Deficiencies

- True cleft hand is distinct from the atypical cleft hand that is recognized as part of the teratologic sequence of symbrachydactyly, a transverse rather than longitudinal deficiency.
- Cleft hand is commonly inherited as an autosomal dominant trait and is associated with SHSF and EEC syndrome.
- Surgery is considered for a variety of indications, including progressive widening of the cleft secondary to transverse lying bones, a narrowed first web space, and the widened cleft.
- Indications for early surgery are separation of syndactyly between digits of unequal length, especially the thumb and index finger, and removal of the transverse bones that result in progressive widening of the cleft.
- In cases of thumb-index finger syndactyly, the first web space requires reconstruction. The technique depends on the severity of the syndactyly. Complete syndactyly can be released, and the cleft closed in a single setting. The skin from the cleft is rotated into the first web space to create supple tissue.

ABSENCE OF FINGERS

Digits that are partly or completely absent due to congenital difference can be classified as being absent in either a transverse or longitudinal direction. In a transverse absence, the digit(s) is absent, but the proximal supporting structures required to support digital function are present to a variable extent. Examples of transverse absence include congenital amputation due to CRS or the failure of digital development due to either symbrachydactyly or transverse deficiency (where no ectodermal remnants persist). In a longitudinal absence, the supporting structures are severely deficient or absent. Examples are thumb absence in radial deficiency, absence of ulnar digits in ulnar deficiency, or central absence(s) in central longitudinal deficiency.

Reconstruction of transverse absence may be achievable by replacing the absent distal part (e.g., by microvascular toe transfer), which

13) A causa frequentemente associada a deformidade de Madelung é:

a) Nanismo acondroplásico
b) Anemia falciforme
c) Encondromatose múltipla
d) Discondrosteose de Leri-Weill

Resposta D

referência Green página 1505

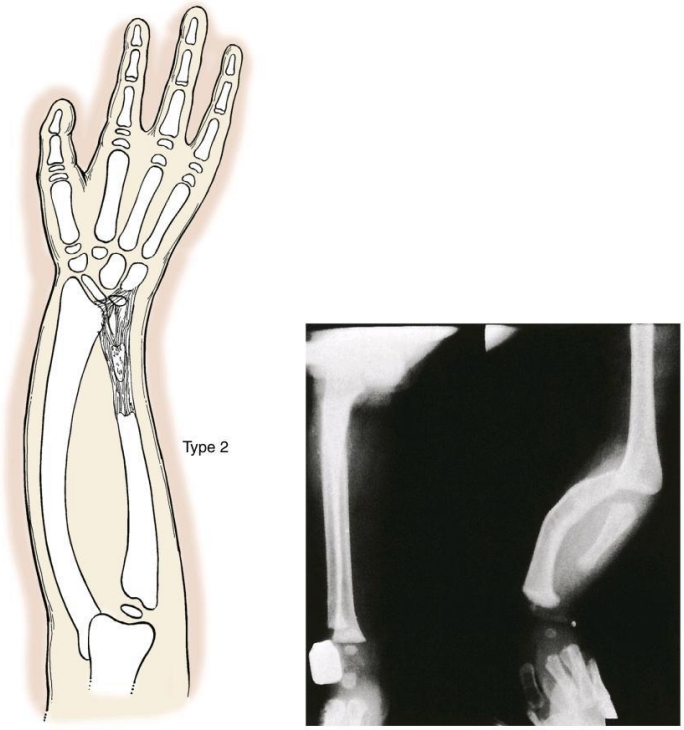

Fig. 38.15 An ulnar anlage acts as a tethering force on the distal radius and wrist.

proximal to the physis (Vickers ligament) (Fig. 38.19).[34] Madelung deformity is usually bilateral, and the deformity typically becomes clinically apparent in early adolescence. The underlying cause of this deformity is often Leri-Weill dyschondrosteosis, a genetic condition with a dominant inheritance pattern and 50% penetrance[35] that is due to a mutation in a short-stature homeobox-containing *(SHOX)* gene.[36] Repetitive loading of the wrist in a growing child may also cause partial physeal arrest. The resultant appearance is similar to Madelung deformity.[37]

The distal ulna of the affected wrist is dorsally prominent, and the distal radius appears to have a dorsal concavity in the lateral view (Fig. 38.20). Ulnar deviation and extension may be decreased. The forearm is shorter than normal. Despite the clinical appearance, there is typically minimal functional impairment. In advanced cases, however, radiocarpal alignment can be strikingly abnormal, leading to pain and functional limitations. Standard radiographic measurements have been established to characterize the severity of the deformity.[38]

Types of Operations

No treatment is necessary for painless deformities. However, physiolysis combined with release of the abnormal ligament should be considered for asymptomatic, skeletally immature patients.

A painful deformity with functional limitations is an indication for treatment. Physiolysis combined with release of the Vickers ligament[34] may reduce the pain and gradually improve the deformity during growth. However, it is unclear whether improvement in radiographic measurements from physiolysis truly translates into functional improvement and avoidance of later osteotomies.[39,40] Furthermore, most patients do not present for treatment until adolescence, when there is insufficient growth remaining for physiolysis to correct the deformity. In these instances, physiolysis and ligament resection may be combined with ulnar epiphyseodesis and/or a dome osteotomy of the radius.[41] In a skeletally mature patient with wrist pain, there are multiple options for correction of the deformity and relief of pain, including (1) ligament resection and dome osteotomy,[41] (2) radial closing wedge osteotomy and ulnar shortening,[42] (3) radial opening wedge osteotomy,[43] (4) radial osteotomy and distal ulnar resection,[42,44] and (5) radial osteotomy and the Sauvé-Kapandji procedure.[45]

For complex deformities in skeletally mature patients, three-dimensional modeling is becoming increasingly popular to help plan correction.[46,47] This technique is commercially available (Materialise®, Brussels, Belgium) and allows more precise correction than standard osteotomy techniques. A three-dimensional computed tomography (CT) scan is performed according to the company protocol. The forearm is reconstructed via virtual surgery between the surgeon and software engineer. Preoperative and postoperative bone models are manufactured along with cutting jigs. A manual is provided with step-by-step instructions on placement of the jigs, cutting of the bone, and

14) O sinal de Putti na criança com problemas musculoesqueléticos secundários a PBO (Paralisia Braquial Obstétrica) é caracterizado por:

a) Atrofia dos músculos supra e infra espinal
b) Protrusão superior do ângulo superior-medial da escápula
c) Bloqueio da rotação interna do ombro
d) Proeminência da cabeça do úmero anteriormente

Resposta B

referência Green página 1578

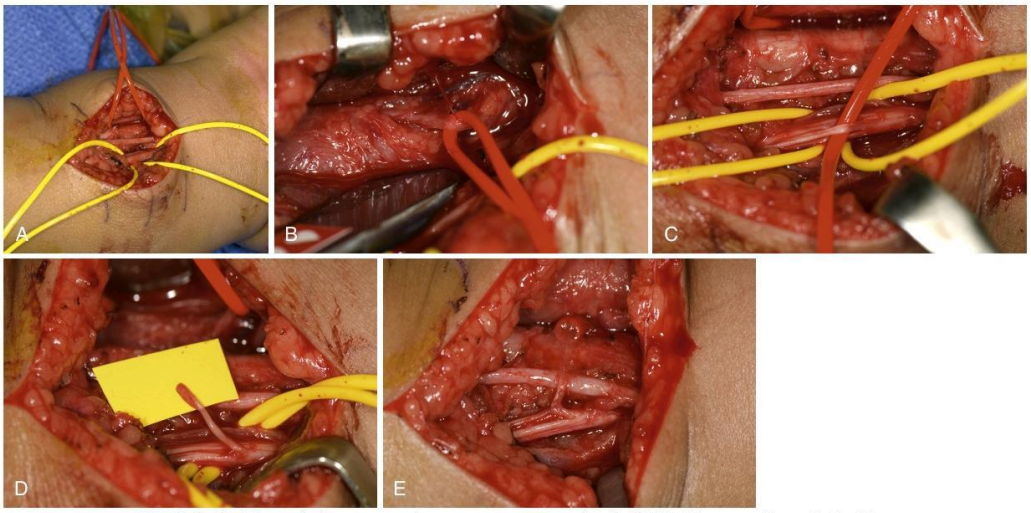

Fig. 40.18 Technique of ulnar-to-musculocutaneous nerve transfer. **A,** Child's right arm with medial incision. Red vessel loop is around biceps motor branch from musculocutaneous nerve; yellow vessel loop is around ulnar nerve. **B,** Motor branch from musculocutaneous nerve to biceps muscle. **C,** A longitudinal epineurotomy along the ulnar nerve to identify the individual group fascicles and to isolate an expendable motor component. Adjacent parallel nerve is medial antebrachial cutaneous. **D,** Group fascicle of ulnar nerve to extrinsic muscles is divided and transferred toward the biceps motor branch. **E,** The group fascicle of the ulnar nerve is coapted to the biceps motor branch using 9-0 nylon suture and fibrin glue. In this case a nerve tube was placed around the repair site for augmentation. (Courtesy of Shriners Hospitals for Children, Philadelphia, Pennsylvania.)

reconstruction (nerve transfers if donor is available) or secondary regional tendon or free muscle transfers[75,162] are warranted to improve outcome. Prior to primary nerve surgery, it is imperative for parents to understand that normal range of motion, strength, posture, and function are unachievable.[160] However, functional improvement compared with the natural history is possible. Recovery of hand function is variable, depending on the original injury and microsurgical reconstruction. The reported mean Raimondi hand function score was 4.57 (out of 5 maximum possible points) for C5-6, 4.26 for C5-7, and 2.16 for total plexus patients (Table 40.4).[65] In addition, even with a positive outcome of hand function and strength, the majority of these patients require secondary tendon transfers to further improve arm function.[141,160]

SECONDARY MUSCULOSKELETAL PROBLEMS

Neurologic injury during the neonatal period disturbs normal postnatal growth and development of the musculoskeletal system. Unless the nerve injury recovers within the first few weeks of life, such disturbances cause permanent and progressive secondary musculoskeletal problems. The two main manifestations of such disturbed development include joint contractures and bony deformity. The contractures substantially impair function and quality of life[70,163,164] and are the most common reason for surgery following BPBI. Contracture development is especially troublesome at the shoulder, where residual paralysis of muscles innervated by the upper trunk leads to restriction of passive glenohumeral motion and resulting glenohumeral dysplasia. The most conspicuous restriction of passive glenohumeral motion is the internal rotation contracture, which has been recognized and treated for more than a century.[165] One theory for the development of the shoulder internal rotation contracture is muscle imbalance between functioning internal rotators and paralyzed external rotators, leading to static internal rotation joint posturing and ultimate joint contracture.[78,135,166]

However, more recent investigations suggest that denervated rather than functioning muscles are responsible for contracture development. MRI studies have demonstrated that the degree of the internal rotation contracture correlates with atrophy of the subscapularis, an internal rotator.[167,168] Furthermore, simple muscle imbalance cannot explain paradoxical contractures, where the joint becomes tight in the direction of the paralyzed muscles. The most notably paradoxical contracture is the elbow flexion contracture that occurs in the setting of initial elbow flexor paralysis.[169-171] In fact, the elbow flexion contracture has been shown to correlate on MRI only with atrophy of the brachialis.[172] At the shoulder, one such paradoxical contracture is glenohumeral abduction that occurs following paralysis of the shoulder abductors.[79,173,174] Because patients with this contracture cannot fully adduct the glenohumeral joint, adducting the arm to the side requires rotation of the scapula on the chest wall.[175] The resulting superior protrusion of the superior-medial angle of the scapula has been termed the Putti sign, after its initial description in 1932.[176] This abduction contracture exists in the setting of abductor muscle atrophy,[173] again consistent with tightness of denervated muscle being responsible for the contracture. Furthermore, physical assessment[177] and motion analysis[178] studies have demonstrated external rotation contractures as well as a greater than normal contribution of scapulothoracic motion to global shoulder motion, suggesting a functional ankylosis of the glenohumeral joint in all directions, consistent with contractures of all the denervated rotator cuff muscles.

Uncertainty regarding the precise etiology of glenohumeral contracture and dysplasia has led to attempts to investigate the pathophysiology

15) O retalho abaixo que é considerado bipediculado é o de

a) Moberg
b) Littler
c) Brunelli
d) Kutler

Resposta A

referência Green página 1719

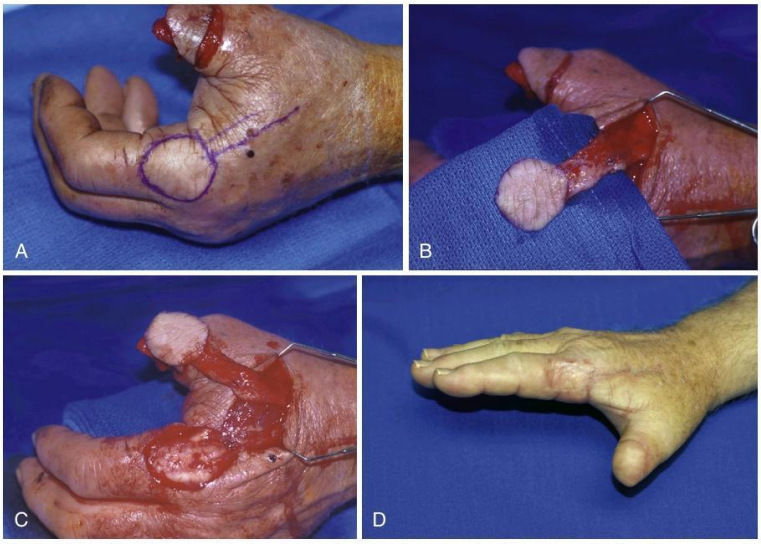

Fig. 44.21 **A,** Patient with amputation of distal thumb and markings for harvesting a kite flap for coverage. **B,** Flap elevated; note wide margin of tissue taken with vessels. **C,** Showing rotation of flap to defect, flap will be placed under skin bridge. **D,** Hand of patient 6 months after flap transfer showing good stability of flap and healing of skin graft at donor site.

injured finger: This flap is most useful in the middle or ring fingers, as the digital vessels are codominant in these fingers, and loss of one is unlikely to cause problems with flow. The index and little fingers, in contrast, may have very small vessels on their radial and ulnar sides, respectively, which theoretically could lead to problems with cold intolerance if the flap is harvested on the opposite dominant vessel.

When used for fingertip coverage, a pattern is made of the defect first. Subsequently, an outline of the proposed flap is drawn near the base of the involved digit centered over the digital vascular pedicle. The majority of the flap is taken from the lateral side of the finger to avoid loss of the important palmar skin near the MCP joint crease. The anterior border of the flap is incised down to the level of the tendon sheath. The distal portion of the incision is made along the midaxial line. The digital bundle is identified, and the digital vascular pedicle is dissected free from the digital nerve. The veins present the greatest challenge in dissection of this flap, as they are quite small and easily damaged. They may be entwined around the digital nerve and must be carefully removed, using bipolar cautery on a low setting to control side branches. The vascular pedicle should not be skeletonized but is rather taken with a small amount of surrounding tissue to avoid damaging the veins. The dissection is basically one of taking the nerve in a volar direction away from the vessels, leaving a cuff of tissue around the artery that should preserve the small veins. This dissection is carried to a level just proximal to the DIP flexion crease, at which level there is usually adequate pedicle to allow easy rotation of the flap to the fingertip defect. The skin incision is carried all the way out to the tip, and the pedicle is carefully placed in this incision. If fascial fibers cause kinking of the pedicle, they must be released while avoiding damage to the venous structures. The donor site is covered with a small split-thickness skin graft, usually taken from the medial upper arm (Fig. 44.23).

This flap has several advantages over other pedicle flaps for fingertip coverage: The damage is confined to a single finger, the finger may be mobilized sooner, and the cosmetic defect is minimal. I limit its use to the middle and ring fingers for the reasons outlined earlier. The flap provides excellent coverage when there is considerable loss of the distal palmar pulp.

Advancement Flaps

A simple advancement flap for use in thumb tip amputation was described by Moberg[59] (Fig. 44.24), which is a bipedicled flap (based on the two neurovascular bundles of the thumb). This is reserved for amputations through the distal phalanx because flexion of the interphalangeal joint may be required for closure of the defect. The two parallel incisions to create the flap are made just dorsal to the two neurovascular bundles of the thumb, which are carefully preserved throughout dissection. The flap is elevated from the flexor tendon sheath. Because the bundles are included in the flap, there is theoretically no limit to the length of the flap. Customarily, the base is placed at the MCP joint skin flexion crease. The flap is best designed with the base as a "V"-shaped incision, which allows the flap to be advanced further and closed as a "V-Y" advancement flap (Fig. 44.25). Alternatively, a full-thickness graft may be applied to the secondary defect overlying the neurovascular bundles and tendon sheath. This advancement flap is safe in the thumb as the dorsum is well perfused by dorsal branches from the radial artery. If the base of the flap is too proximal or the patient is a smoker, necrosis of a portion of the distal dorsal thumb skin can occur. The dorsal neurovascular branches of the digital vessels should be preserved on one or both sides of the flap, which will obviate any vascular problems of the distal dorsal skin. This preservation, however, will decrease the length that the flap can be advanced.

16) Em relação a rigidez articular:

a) o tratamento apresenta boa resposta se for encontrado apenas mau alinhamento articular
b) artroplastia tem bom resultado devido a manutenção do arcabouço ligamentar
c) a artroplastia de distração tem resultado limitado
d) artrose pós traumática tem pouco resultado com liberação capsular, mas bom resultado com artroplastia com implante

Resposta C

referência Green página 392

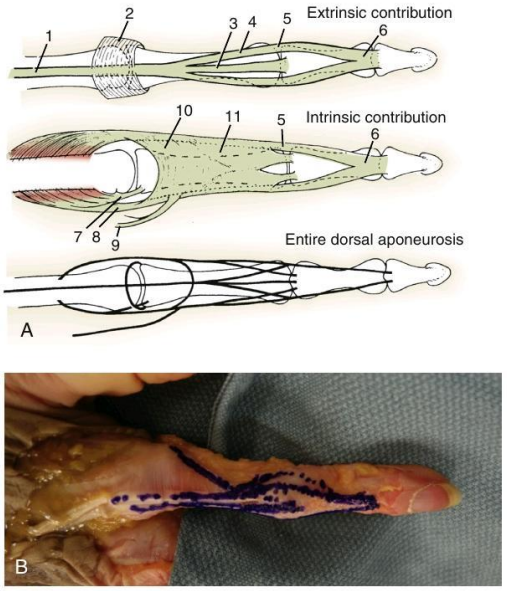

Fig. 10.6 Lateral view of the dorsal aponeurosis of the finger. **A,** Diagrammatic representation of the extrinsic contribution, the intrinsic contribution, and the entire dorsal aponeurosis of the finger. *1,* Extensor tendon; *2,* sagittal band; *3,* central slip; *4,* lateral slip; *5,* conjoined lateral band; *6,* terminal tendon; *7,* superficial head and medial tendon of the dorsal interosseous; *8,* deep head and lateral tendon of the dorsal interosseous; *9,* lumbrical muscle and tendon; *10,* transverse fibers of the dorsal aponeurosis; *11,* oblique fibers of the dorsal aponeurosis. **B,** Dissected specimen showing the dorsal aponeurosis of the finger. The *cardboard arrow* points to the lateral band lying between the lateral tendon and the conjoined lateral band. The transverse and oblique fibers are *dotted.* The central slip, lateral slip, lateral band, and conjoined lateral band are identified by the *continuous dark lines.* The sagittal bands lie proximal to the *dotted* transverse fibers of the dorsal aponeurosis.

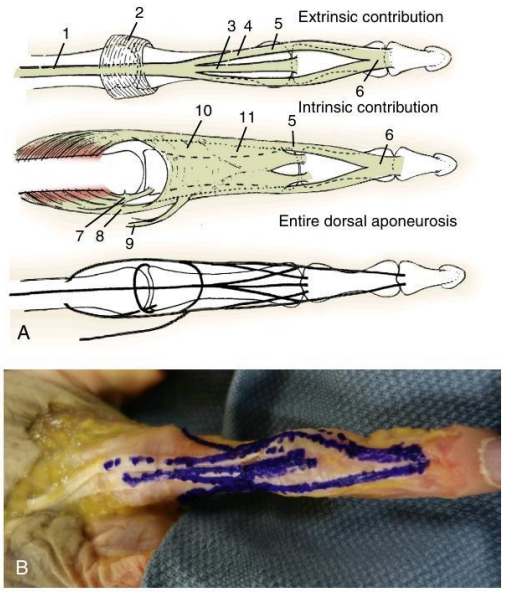

Fig. 10.7 Dorsal view of the dorsal aponeurosis of the finger. **A,** Diagrammatic representation of the extrinsic and intrinsic contributions of the dorsal aponeurosis. *1,* Extensor tendon; *2,* sagittal band; *3,* central slip; *4,* lateral slip; *5,* conjoined lateral band; *6,* terminal tendon; *7,* superficial head and medial tendon of the dorsal interosseous; *8,* deep head and lateral tendon of the dorsal interosseous; *9,* lumbrical muscle and tendon; *10,* transverse fibers of the dorsal aponeurosis; *11,* oblique fibers of the dorsal aponeurosis. **B,** Dissected specimen showing the dorsal aponeurosis of the finger. The central slip, lateral slips, lateral band, and conjoined lateral band are identified by *solid lines* over the proximal phalanx. The conjoined lateral bands and terminal tendons are identified by *continuous lines* over the middle phalanx. The *dotted lines* represent the transverse fibers (proximally) and oblique fibers (distally) of the dorsal aponeurosis overlying the proximal phalanx.

The highest priority of function combined with the highest probability of success is seen with attempts to improve *flexion* at the MP and PIP joints following trauma. Improvement of active and passive flexion of the joints is more likely than improvement of extension (e.g., patients with fixed contractures resulting from intrinsic tightness are excellent candidates for improvement following surgery).

Musicians present a unique and interesting challenge, because different instruments place vastly different demands on the fingers and hands and require an individualistic analysis. Pianists, who play with both hands, can adapt so that little PIP motion is needed, as long as the joint is pain-free. In contrast, musicians who play string instruments need both strength and mobility, especially of the fingering or fretting hand, even including the DIP joint.

TREATMENT

Evaluation

Status of the Articular Surface

If a joint shows signs of posttraumatic arthritis or articular malalignment, there is minimal chance of improvement with capsular release. Therefore, if the joint is in poor condition, contracture release surgery should be avoided. Although implant arthroplasty following posttraumatic stiffness has been successful in the hip, knee, and elbow, this has not been the case for the MP or PIP joints. The reported motion gain is minimal, and implant failure is quite common.[25] Although some limited success has been reported for distraction arthroplasty, at this time a general recommendation regarding this procedure cannot be made.[26]

Nomenclature (Table 10.1)

When evaluating a joint, one must differentiate between a contracture, meaning the joint is fixed, and a lag, meaning the passive motion is better than active motion. For example, a PIP joint may have a flexion contracture where the joint lacks full extension passively and actively or an extension lag, where the joint cannot be actively extended but has full passive extension.

Capsular Contracture, Extrinsic Tendon Adherence, and Intrinsic Function

The examination of the stiff joint requires a fundamental understanding of the interdependence and relative roles of the joint capsule, extrinsic tendon adherence, and intrinsic function. It is vital to distinguish between active and passive motion and to determine the position of the adjacent joint in which these parameters are measured.

17) Na espasticidade secundária a paralisia cerebral, levando em consideração a hierarquia da função da mão, a segunda prioridade de reconstrução é

a) preensão palmar
b) extensão do punho
c) abertura da mão
d) pinça lateral

Resposta D

referência Green página 1248

TABLE 32.6 Reconstructive Ladder for Hand Function

Priority	Function	Task
1	Wrist extension	Tenodesis grasp and pinch
2	Lateral pinch	Activities of daily living
3	Grasp	Holding
4	Opening	Object acquisition
5	Coordinated hand function	Dexterity

muscle) and are not amenable to fractional lengthening. In addition, if substantial lengthening is required, fractional lengthening would exceed the length of the muscle-tendon junction, resulting in discontinuity between the muscle and tendon. Lastly, certain muscles are amendable to release of the origin and allowing the muscles to slide in a distal direction (e.g., flexor pronator mass and thenar muscles).

Hierarchy of Upper Limb Function

Proximal muscle stability and control is mandatory for hand function. Evaluation of the upper limb requires synthesis of the assessment of each anatomic segment of the limb. The spastic shoulder is usually positioned in internal rotation and adduction. The shoulder must be stable and well positioned, allowing the arm, forearm, and hand to function. With reference to the elbow, flexor spasticity is commonplace. In mild hemiparesis, this yields elbow flexion posturing during walking and times of excitement. In more severe cases, a myostatic contracture develops that limits elbow extension. The forearm, referred to as "the forgotten joint," is, however, a frequent source of discontentment. The common forearm position is spastic pronation that is initially supple (dynamic) and develops a myostatic contracture over time. Excessive pronation impedes supinations activities, such as feeding, carrying a tray, obtaining soap from a dispenser, catching a ball, and wiping one's buttocks. Tendon releases and transfers can improve forearm position (discussed below). Surgical management tends to focus on the wrist flexion with a variety of options available. The management of the spastic wrist and hand in CP follows the concepts of "hierarchy of hand function" or the "reconstruction ladder" (Table 32.6).[57]

The pivotal fundamental movement is wrist extension, which yields tenodesis for grip as the fingers flex into the palm and tenodesis for lateral pinch as the thumb adducts against the index finger. Wrist extension also aligns the finger flexors along Blix's length-tension curve for maximum active grip. The second most essential movement is lateral pinch, which is necessary to perform numerous activities of daily living. Most daily activities are performed using lateral pinch, such as holding an object, turning a key, or using a fork. The third essential motion is grasp, which allows the holding of objects. The fourth and last movement is digital opening for object acquisition. The reason to place this function lowest on the ladder is that wrist flexion yields passive digital opening, which is often adequate for object procurement. In addition, synchronous digital opening is difficult to achieve via surgery as metacarpophalangeal joint extension requires both extrinsic function (extensor digitorum communis, extensor indicis proprius, and extensor digiti quinti) and intrinsic function (interphalangeal joint extension with interossei and lumbricals). Providing a comprehensive plan of all involved joints is necessary, as outlined in Table 32.5.

Fig. 32.3 A 22-year-old male with spastic quadriplegia and marked shoulder external rotation that prohibited passage through a doorway. (Photos courtesy of Shriners Hospital for Children, Philadelphia, Pennsylvania.)

Shoulder Reconstruction

The spastic shoulder is usually positioned in internal rotation and adduction. The child may be bothered by the posture and the inability to access his or her axilla. Severe internal rotation and adduction can make the axilla inaccessible, leading to stench and intertriginous infections. Treatment requires release of the offending spastic muscles based upon the clinical examination. The potential culprit spastic muscles include the pectoralis major and subscapularis. However, additional muscles such as the latissimus dorsi and teres major can contribute to the position. Clinical examination can often discern the most spastic muscles. These muscles can be treated by lengthening or release depending on their anatomy. For example, a tight spastic pectoralis major can be addressed by simple fractional lengthening via a small incision, as there is ample muscle-tendon junction on its undersurface. In contrast, the subscapularis requires a more extensive deltopectoral approach with release of the upper tendinous portion. The goal is to provide ample access to the axilla. The procedure is performed via a deltopectoral approach extended into the axilla. The deltopectoral approach allows access to the pectoralis major and the subscapularis. The approach can be extended through the axilla if the latissimus dorsi and teres major are contributing. Following surgery, the arm is positioned in an abduction pillow for 3 weeks followed by passive range of motion.

The shoulder can also be positioned in excessive external rotation (Fig. 32.3). This awkward position can negate the child in a wheelchair from entering through a doorway. The offending muscle(s) are usually the infraspinatus, teres minor, and/or posterior deltoid. These muscles can be released from their insertions to lessen the shoulder external rotation. If the contracture is fixed and severe, a shoulder derotation osteotomy can be performed. This has been an effective treatment in the adult with fixed shoulder external rotation deformities.[58] The muscles can also be denervated by selective neurectomy of their motor nerve (Case Study 32.1).

AUTHORS' PREFERRED METHOD OF TREATMENT: SHOULDER RECONSTRUCTION

Severe internal rotation and adduction contractures prohibit access to the axilla. We prefer lengthening or releasing the tight spastic muscles. We do not recommend tendon transfers, as the results are unpredictable. In patients with spasticity but without contracture, selective neurectomies are preferred.

18) No tratamento conservador da fratura do rádio na criança, é fator para perda de redução:

a) 40 graus de translação
b) fratura isolada do rádio distal
c) 25 graus de angulação
d) lado dominante

Resposta B

referência Green página 1625

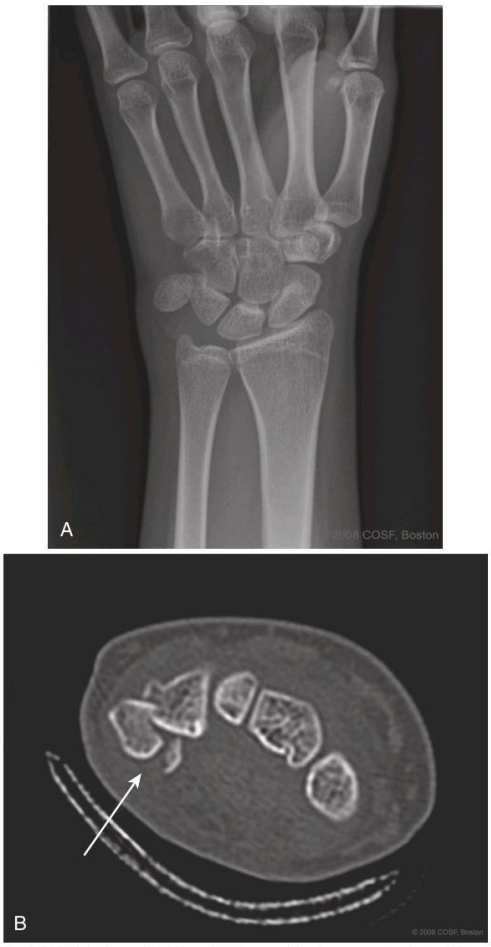

Fig. 41.29 Radiograph **(A)** and CT scan **(B)** of a comminuted pisiform fracture in a 15-year-old girl. After 4 weeks of cast immobilization, the patient's symptoms resolved, and she returned to full activities. (Courtesy of the Children's Orthopaedic Surgery Foundation.)

stabile. Likewise, no follow-up clinical evaluation is necessary after cast immobilization is discontinued.

Bicortical Metaphyseal Fractures

Bicortical fractures of the distal radial metaphysis occur secondary to bending, rotational, or shear forces imparted on the wrist. Fractures may be transverse, spiral, or oblique and may present with considerable displacement (Fig. 41.31). While bayonet apposition will remodel reliably in young children, fractures with unacceptable angulation or translation are typically treated with closed reduction and cast immobilization.[133] Depending on the patient and care setting, this may involve hematoma block, conscious sedation, or even general anesthesia. Because of the thick periosteum in younger patients, reduction maneuvers consist of exaggeration of the deformity, followed by longitudinal traction and reversal of the mechanism of injury (Fig. 41.32). The thick, intact periosteum acts as a tension band in facilitating reduction and conferring stability. However, exaggerating the deformity slackens the periosteum and allows restoration of length and alignment. Straight traction alone will not suffice. Application of a well-molded cast with three-point bending or an appropriate interosseous mold is critical in maintaining reduction and minimizing the risk of later displacement. Excessive wrist flexion should be avoided.[88]

The optimal position of forearm rotation in a long-arm cast remains controversial.[60] Some advocate pronation, given that pronation may better correct rotational malalignment and maintain fracture reduction in the more common apex volar injury. Others advocate supination to allow improved fracture molding and relaxation of the brachioradialis. Still others advocate immobilization in neutral, citing an improved ability to apply an interosseous mold and theoretically minimize loss of motion at the extremes of forearm rotation.

Two prospective, randomized clinical trials compared the efficacy of short- versus long-arm casts in maintaining reduction following closed fracture manipulation.[134,135] Both investigations concluded that short-arm casts are as efficacious in maintaining fracture alignment as long-arm casts; however, careful analysis of the data reveals a number of important points. First, more important than the length of cast is the quality of fracture reduction and cast molding. Indeed, in one study of 103 patients, risk for loss of fracture reduction was higher in patients with a cast index greater than 0.7.[135] In addition, fractures that were incompletely reduced (i.e., had residual displacement or angulation following manipulation) were at higher risk for subsequent loss of reduction, emphasizing the importance of the reduction maneuver over the type of immobilization.[134] Patients with concomitant fractures of the distal ulna were at higher risk for loss of reduction, regardless of casting technique. Finally, the effect of long-arm casting on the ability to perform activities of daily living is not inconsequential. Short-arm casts were associated with fewer days of missed school and less assistance required during daily activities.[135] Subsequent studies and meta-analyses have confirmed these findings.[136]

Despite successful initial closed reduction and cast immobilization, late displacement of fractures is common. Prior published series reported loss of reduction rates between 10% and 91%.[137-146] In general, approximately one-third of all distal radial fractures requiring reduction will demonstrate late displacement. Factors implicated in the loss of reduction include initial displacement (bayonet apposition, >50% translation, >30 degrees of angulation), isolated distal radial fracture, associated same-level ulnar fracture, inadequate initial closed reduction, poor casting technique, muscle atrophy, and resolution of initial soft tissue swelling while in the cast. Hence, serial radiographic evaluations must be performed, initially on a weekly basis, to assess bony alignment and rule out loss of reduction.

Efforts have been made to characterize the quality of fracture reduction and casting techniques to predict which injuries might be more prone to later displacement (Fig. 41.33). The cast index refers to the ratio between the diameters of the cast at the level of the fracture, as measured on lateral and AP projections.[147,148] Used as a measure of the quality of the cast mold, cast indices greater than 0.7 have been associated with an increased risk of loss of fracture reduction.[135,147] A gap index has also been proposed to assess the quality of cast molding, as well as excessive cast padding and resolution of soft tissue swelling.[149] The gap index is calculated by dividing the aggregate distance between the skin and cast material by the overall diameter of the cast. If the sum of the gap indices as measured on both AP and lateral radiographs is greater than 0.15, there is a higher risk of loss of fracture reduction with a sensitivity of 88%. Three-point index has recently been proposed as a more sensitive and specific radiographic measure of cast mold and

19) A figura abaixo representa a utilização de um enxerto ósseo vascularizado para doença de Kienböck. Ele é nutrido pela artéria:

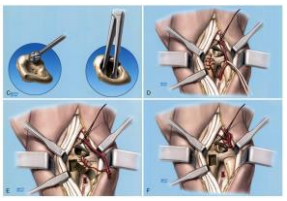

a) Intercompartimental supra retinacular 1-2
b) Intercompartimental supra retinacular 2-3
c) Do quarto compartimento extensor
d) Do quinto compartimento extensor

Resposta C
referência Green página 1807

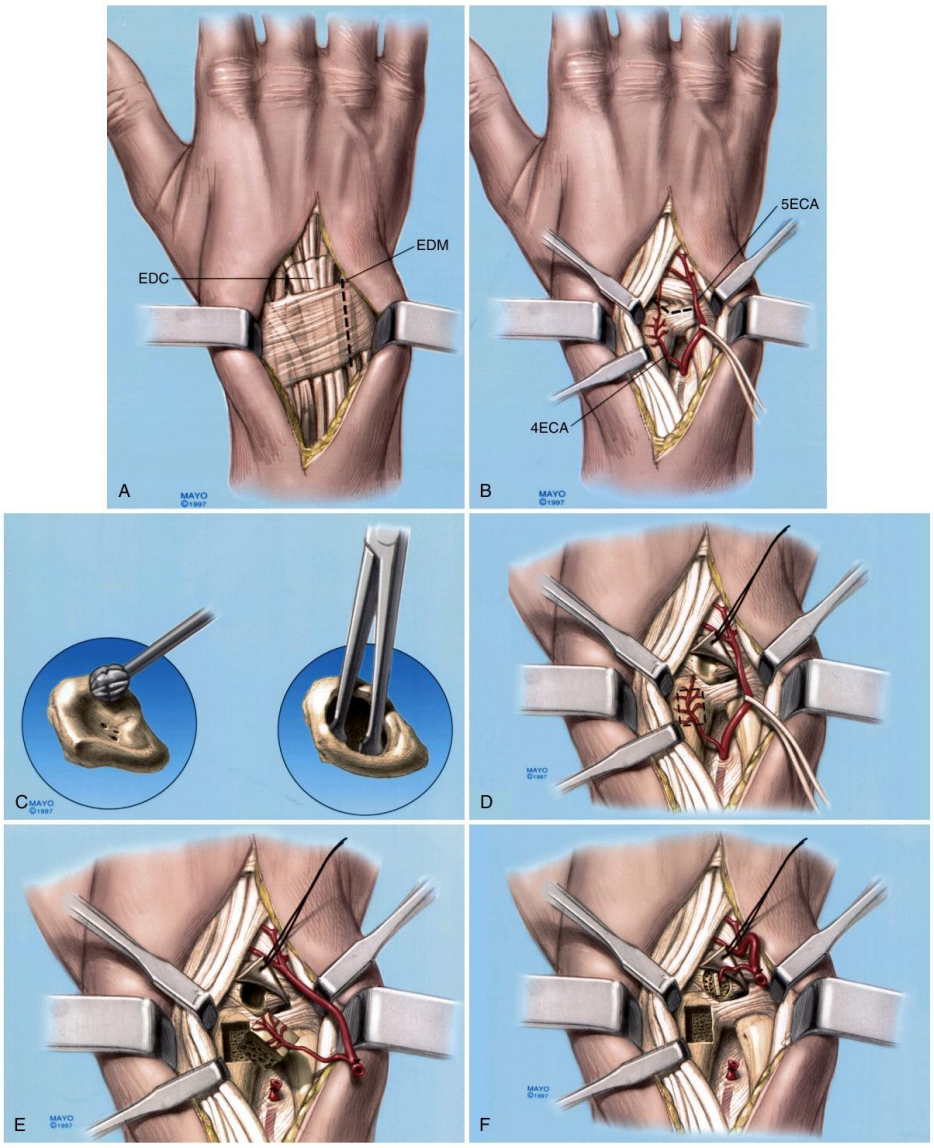

Fig. 46.16 Vascularized graft for Kienböck disease using the 4 extensor compartment artery (ECA) pedicle graft. **A,** The fifth ECA is exposed by opening the fifth extensor compartment. **B,** The fifth ECA is traced proximally to its origin from the posterior division of the anterior interosseous artery. A radial-based retinacular flap exposes the fourth compartment tendons, which are retracted radially to expose the fourth ECA. A ligament sparing capsulotomy is performed, protecting the fifth ECA and exposing the lunate. **C,** The lunate necrotic bone is removed with a bur and expanded. **D,** The site of the bone graft, including the fourth ECA. **E,** The graft is elevated, providing retrograde blood flow through the fifth ECA into the fourth ECA with attached radius bone. **F,** The graft is inserted vertically into the lunate. *EDC,* Extensor digitorum communis; *EDM,* extensor digiti minimi. (Used with permission of Mayo Foundation for Medical Education and Research. All rights reserved.)

20) Na reconstrução do polegar hipoplásico, é opção preferencial para transferência tendinosa na oponentoplastia, o uso do tendão

a) abdutor do dedo mínimo
b) flexor superficial do dedo médio
c) extensor ulnar do carpo
d) extensor próprio do dedo indicador

Resposta B

referência Green página 1457

Fig. 37.5 A 1-year-old with type V thumb hypoplasia, and a small skin nubbin present in complete absence of the thumb. (Courtesy of Shriners Hospital for Children, Philadelphia, Pennsylvania.)

radial deficiency is the same. Pollicization is indicated and is the preferred procedure for marked thumb hypoplasia. The surgical technique for pollicization is similar, with minor modifications, such as skin design.

The standard indications for pollicization can be expanded to include a thumb that is just too small to make a useful thumb despite having a stable CMC joint.[6] This decision to ablate the small thumb and pollicize the robust index finger requires a prolonged conversation with the parents about the rationale for this recommendation. Parents generally come to understand that "function trumps form" and that thumb ablation and index finger pollicization will result in a thumb which is more functional than the small, scrawny thumb even after reconstruction.[9] When in doubt, parents are given a list of other parents who have made a similar difficult decision regarding thumb ablation. This parent-to-parent communication is invaluable.

Treatment for Thumb Hypoplasia

An experienced hand therapist is invaluable in the evaluation of the child with a hypoplastic thumb. Although there is little need for nonoperative management, the hand therapist's input is essential and can provide support for the family and facilitate the decision-making process. Following surgery, the therapist becomes a primary care provider who directly affects the success of the procedure.

The classification schema guides treatment. Type I hypoplasia usually does not warrant surgical intervention because the functional impairment is negligible. Type II or IIIA hypoplasia diminishes function and often requires surgery to provide stability, improve motion, and enhance function. Type IV or V hypoplasia requires index finger pollicization if the index finger is "suitable" for becoming a thumb. A stiff index finger will be a stiff thumb and may not enhance hand function. Therefore determining the risk-benefit ratio of pollicization requires ample thought and consideration. The operation should follow the Peter Carter 2-4 rule: For some children, surgery can indeed be done "to" them, but it may not necessarily be "for" them. We have slightly modified the Carter 2-4 rule to state that the operation should be done "to" the patient and "for" the patient.

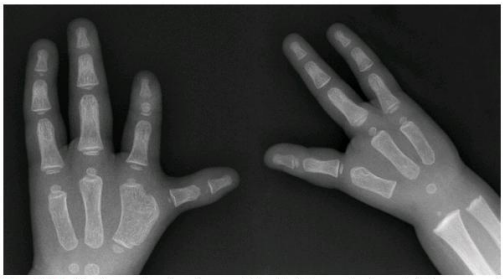

Fig. 37.6 Radiograph of a 4-year-old with bilateral ulnar deficiency and marked left thumb hypoplasia. (Courtesy of Shriners Hospital for Children, Philadelphia, Pennsylvania.)

Thumb Reconstruction

Thumb reconstruction for type II and IIA hypoplasia requires addressing all the deficient elements. The narrowed thumb/index finger web space, MCP instability, and thenar muscle absence all require treatment. Thumb/index finger web space narrowing is treated with skin rearrangement and soft tissue release. A four-flap Z-plasty lengthens the tight skin and provides a rounded contour to the web space. The theoretical increase in length is 150%.[10] The deeper soft tissue release includes the investing fascia around the adductor pollicis. The princeps pollicis artery and its branches must be identified and protected before division of the fascia. An extremely tight web space may also require partial release of the adductor muscle and/or first dorsal interosseous muscle to obtain adequate breadth. An extremely tight web space may require more extensive skin rearrangement, such as a dorsal rotation flap or Ghani flap.[11]

MCP instability necessitates stabilization. Unidirectional instability with an incompetent UCL is the most common finding. Ligament reconstruction can be performed with local tissue or preferably the residual length of donor tendon from the opposition transfer. Bidirectional or global instability is more challenging to manage. Reconstruction of both the radial and UCLs with a tendon graft is an option. MCP joint chondrodesis is preferred, however, to achieve firm stability and provide a stable platform for the opposition transfer to function. The details of MCP joint chondrodesis are discussed in Chapter 39 (Arthrogryposis). UCL insufficiency can be secondary to an anomalous connection between the flexor pollicis longus and extensor pollicis longus muscles (i.e., *pollex abductus*).[12-14] The pollex abductus attenuates the UCL over time and prevents active thumb IP joint motion. The key to determining its presence is the physical examination prior to surgery. During attempted thumb IP flexion, the MCP joint deviates into valgus rather than bending the IP joint. Surgery must release the pollex abductus during the surgery to reconstruct the UCL.

Thenar absence requires a tendon transfer to provide thumb opposition. There are a variety of donor muscle-tendon units to choose from, including the flexor digitorum superficialis (FDS) (long or ring finger), abductor digiti minimi, extensor carpi ulnaris, and extensor indicis proprius.[15] Each donor muscle-tendon unit has its advocates and its advantages and disadvantages. The long or ring finger FDS is preferred because of its length, power, expendability, and synergism and the technical ease with which it can be used. If the FDS is unavailable, the other donor options are considered.

Flexor digitorum superficialis opponensplasty with ulnar collateral ligament reconstruction. The patient is placed supine on the operating room table (Box 37.1 and see Videos 37.2 and 37.3). The procedure is performed under general anesthesia. A single dose of intravenous

21) Em relação ao carcinoma basocelular:

a) a forma esclerosante é frequente na mão
b) o tipo adenóide apresenta ilhas de tumor cercada por estroma mixóide
c) a forma superficial tem baixa taxa de recorrência
d) a forma nodular sólida é tipo menos frequente

Resposta B

referência Green página 2167

the trunk and upper extremities (Fig. 58.30). Overall, the superficial spreading type is the next most common form of BCC.

Solid (nodular) BCC is the most common form. It may ulcerate, and this is called nodular ulcerative. It is dome-shaped with well-defined borders, is often a pink-red papule, and has a "pearly" appearance with telangiectasias. Although nodular BCCs may be histologically poorly differentiated, their growth pattern is circumscribed.

Adenoid BCC has strands of tumor islands that resemble tubular structures surrounded by myxoid stroma. *Cystic BCC* has cystic spaces in the tumor island secondary to degeneration of tumor cells. When "adenoid" areas are also present, the lesion is called adenoid cystic. These large lacunae give a distinct macroscopic appearance. Cysts rupture fluid to the lesion surface (see Fig. 58.29).

Diffuse BCCs have a higher recurrence rate than circumscribed lesions because they extend insidiously in the dermis beyond the clinically visible or palpable border. *Superficial BCC* has been called multicentric BCC because discrete foci seem to be present. However, three-dimensional histologic reconstruction reveals that the apparent multiple foci are actually connected. They are not easily treated and have a higher recurrence rate because of their extension beyond clinically apparent borders. They are scaly, crusted, erythematous, and flat with the skin surface. They may be ringed by a raised "pearly" border that slowly expands. Confusion may arise with eczema, actinic keratosis, psoriasis, and fungal infection.

Fig. 58.21 Extremity porokeratosis of Mibelli.

Morpheaform (sclerosing) BCC is quite rare on the hand and more common on the face. It is a firm plaque surrounded by "scar" tissue and lateral spread has been reported as much as 7 mm beyond the clinically apparent tumor border.[28] Dense, fibrous stroma precludes treatment by curettage.

Curettage and electrodessication is the most common method of treating BCC. This technique is reserved for primary lesions less than 1 cm in diameter. Hand extremity lesions are amenable to this form of treatment. Well-defined lesions may also be treated by cryosurgery.[29] Potential risk is neuropathy due to uncontrolled depth of freeze, and this form of treatment should be avoided on digits and around the ulnar nerve at the elbow.

Although cure rate for curettage and electrodesiccation and for cryosurgery for small lesions has been reported as high as 97%, an inherent disadvantage is lack of microscopic verification of complete tumor removal.[30,31] Surgical excision offers greater than 90% cure rate[4,32] (Fig. 58.31). Loupe magnification allows more accurate visual assessment of tumor borders. Mark out the tumor borders before local anesthetic injection to avoid tumor distortion. A 2-mm surgical margin may be sufficient for less than 1-cm diameter nodular lesions. However, for lesions up to 2 cm, a 3 to 5 mm margin is more appropriate and extending deeply into subcutaneous fat. Lesions greater than 2 cm and those with aggressive growth patterns, such as morpheaform and superficial "multicentric" BCC, may require resection margins of 10 mm (where practically possible)[33,34] but reserved for larger and infiltrative lesions. Frozen section of tumor margins is expensive and not recommended for every suspected BCC. If microscopic margins are found to be involved on permanent pathologic assessment, reexcision will not affect the likelihood of cure. However, for the higher risk lesions already discussed, frozen sections of margins are recommended and even a potential recourse to Mohs micrographic surgery. If flap reconstruction is planned, always ensure margins are uninvolved by tumor through either frozen section or awaiting the results of permanent section, meanwhile maintaining a moist dressing (Fig. 58.32). Therapeutic topical 5-fluorouracil or imiquimod does not offer acceptable cure rate for treatment of BCC.[35]

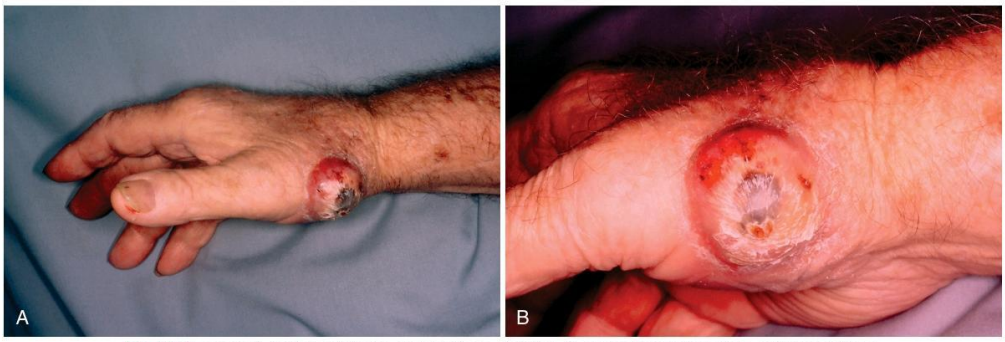

Fig. 58.22 **A** and **B,** Keratoacanthoma at dorsal base of thumb. It shows the characteristic central keratinous plug.

22) Sobre a síndrome compartimental neonatal:

a) a abordagem precoce da contratura de Volkmann se traduz em bom prognóstico
b) apresenta lesão típica sentinela no braço
c) está associada a banda amniótica
d) o comprometimento típico é na mão

Resposta B

referência Green página 1967

51

Compartment Syndrome and Volkmann's Ischemic Contracture

Milan V. Stevanovic, Frances Sharpe

These videos may be found at ExpertConsult.com:

51.1 Surgical Technique of Upper Extremity Fasciotomy, Cadaver Demonstration
51.2 Ten-Year Follow-Up on Flexor Origin Slide for "Moderate"-Type Volkmann's Contracture
51.3 Six-Month Follow-Up on Functional Free Muscle Transfer for Volkmann's Ischemic Contracture
51.4 Eighteen-Month Follow-Up on Functional Free Muscle Transfer for Finger Flexion for "Severe"-Type Volkmann's Contracture

Acknowledgment: The authors gratefully acknowledge the contributions of Dr. Ayan Gulgonen and Dr. Kagan Ozer, who authored the chapter on compartment syndrome in the sixth edition of Green's Operative Hand Surgery.

COMPARTMENT SYNDROME

Acute compartment syndrome (ACS) of the extremity is a diagnosis requiring emergent surgical intervention. ACS is characterized by sustained elevation of tissue pressure within an osseofascial or fascial compartment that exceeds tissue perfusion pressure. This results in local circulatory impairment, ischemia, cellular anoxia, and ultimately tissue death. ACS occurs in the acute phase following injury during which time surgical intervention can reduce the extent of irreversible muscle and tissue injury. Timely diagnosis and treatment are critical to reduce the extent of permanent changes within muscle and nerve tissue. Even with emergent treatment, there may be permanent disability in the affected extremity and a subsequent need for additional surgery, including amputation.[1,2] Volkmann's ischemic contracture represents the late sequelae of compartment syndrome. This disorder has a spectrum of fixed muscle contractures and neurologic impairments. Numerous authors have contributed to our understanding and treatment of this condition. Table 51.1 summarizes some of the historical events in the recognition of this entity including etiology, pathologic findings, and sequelae.

Types of Compartment Syndromes

Acute Compartment Syndrome

ACS occurs when tissue pressures rise high enough within an osseofascial compartment to cause tissue ischemia. The resultant tissue injury can range from reversible muscle swelling to permanent tissue necrosis depending on the magnitude and duration of tissue pressure elevation. When pathologic tissue pressure elevation has been present for less than 4 hours, ACS is in the early stage[3]; when pathologic tissue pressure elevation has been present for more than 4 hours, ACS is in the late stage.

Impending Compartment Syndrome

Impending compartment syndrome represents a clinical setting in which a compartment syndrome is at risk of developing; however, tissue pressure is not yet sufficiently elevated to cause muscle ischemia. Clinical scenarios in which this may occur include limb reperfusion after prolonged ischemia, posttraumatic swelling of a limb, or high-energy injuries.

Exercise-Induced or Exertional Compartment Syndrome

Both acute and chronic exercise-induced compartment syndrome have been described (AECS and CECS). Most exercised-induced compartment syndrome is chronic and represents a reversible tissue ischemia due to a noncompliant fascial compartment that is unable to accommodate muscle expansion occurring during exercise. It has been described in both the upper and lower extremities and is different from ACS in that the symptoms are reversible after cessation of exercise. Emergent surgery is not usually indicated unless symptoms do not abate with cessation of the activity as can be seen in AECS.[4-6] Traditional fasciotomy and endoscopic fasciotomy have been used to treat exercise-induced compartment syndrome.

Crush Injury or Crush Syndrome

Crush injury is the external compression of an extremity, as might occur in a building collapse or in an obtunded patient who lays on an extremity for a prolonged period. The compression of the extremity leads to muscle ischemia and reperfusion injury once the compression is relieved. This process of events can lead to compartment syndrome. *Crush syndrome* is a localized crush injury with systemic manifestations. Reperfusion of the affected extremity can rapidly release muscle breakdown products (rhabdomyolysis) into the system, which can lead to renal failure or death.[7,8]

Neonatal Compartment Syndrome and Neonatal Volkmann's Contracture

Both neonatal compartment syndrome and neonatal Volkmann's contracture have been reported. Awareness of this diagnosis is important because early recognition and treatment can improve the functional outcome and growth in neonatal compartment syndrome. The forearm is most commonly affected. In addition to forearm swelling, there is often a characteristic skin lesion on the proximal lateral arm, known as the *sentinel lesion of neonatal compartment syndrome*.[9] Established neonatal Volkmann's contracture cannot be improved by early intervention. The infant is frequently misdiagnosed with an arterial injury or amniotic band. A correct diagnosis helps the family cope with the injury and eliminates any underlying questions, concerns, and guilt (Fig. 51.1A and B).

Volkmann's Ischemic Contracture

Volkmann's ischemic contracture is the end result of prolonged ischemia and is associated with irreversible tissue necrosis. The ischemic contracture has a spectrum of presentations.

23) A figura abaixo representa um paciente acometido por:

a) Gota
b) Artrite reumatoide
c) Artrite psoriática
d) Artrite séptica

Resposta C

referência Green página 2041

Fig. 55.1 Typical appearance of a psoriatic hand that includes the psoriatic skin rush, pitting nail deformity, joint destruction with significant bone loss (cup-in-pencil deformity), and shortening of the fingers (opera glass deformity).

formation, nail dystrophy, and seronegativity.[12] The specificity is 99% and the sensitivity is 92% using this classification system.

Psoriatic arthritis is a severe form of joint disease and spontaneous remission is extremely rare. The current treatment follows the similar approach as in RA. The pyramid of treatment includes nonsteroidal antiinflammatory drugs (NSAIDs), disease-modifying antirheumatic drugs (DMARDs) including Hydroxychloroquin, methotrexate, leflunomide, and biologics or biosimilars. The biologics in particular, if given early in the disease, proved to have a suppressive effect on skin and joint inflammation and may retard radiographic joint destruction.[13] In cases of severe bone erosions in the finger joints, the bridging of bone defects is a challenge in treating the psoriatic patient.

Systemic Lupus Erythematosus

SLE is a multisystem autoimmune disease affecting different organ systems including the skin and the joints. The course of the disease is variable and often starts in childhood. It is a potentially fatal inflammatory disease involving inner organs like the heart, lungs, and kidneys. Ninety percent of the patients suffering from SLE are females. The disease is much more common in African Americans and Asian Americans and in the Hispanic population. Although the cause of SLE is unknown, sun exposure, infection, and some medications have been identified as triggers of the disease. The butterfly-like rash on the face is a typical manifestation but may not be present in all patients. In the hand, an erythematode maculopapular rash might be present, especially after sun exposure. In the fingers, Raynaud phenomenon is often observed.[14]

The typical finger joint deformity in SLE is often called Jaccoud disease, which consists of metacarpophalangeal (MCP) joint subluxation and ulnar deviation with or without swan neck deformity and Z-deformity of the thumb.[15]

In contrast to RA, erosive destruction of the bone is not present, and there is little or no synovitis (dry joints) with passively correctable deformities. The disease seems to affect mainly the ligaments and the periarticular soft tissue.

The diagnosis of SLE involves a combination of clinical observations and additional laboratory markers. The most common but nonspecific sign of the disease is fatigue, fever of unknown origin, the typical skin rash, and arthralgia. The antinuclear antibodies (ANA) have a high sensitivity, and a titer of 1:80 is a sufficient criterion to make the diagnosis.[16]

The treatment of SLE requires a team approach. Besides NSAIDs, hydroxychloroquine, with or without a glucocorticoid, is the first medical treatment of choice for patients diagnosed with SLE. Newer biologic medications are available, but because of the complexity of the disease, none of the current medications have been established as a standard treatment option.[17] Treating the serious internal medical complications often takes priority over the arthritis symptoms.

When the patient's medical conditions are stable, the hand surgeon can participate in treatment by correcting or preventing ongoing joint destruction in the hand. There is a limited role for conservative treatment. Passively correctable deformities can be treated with protective devices, especially during the day and in activities, with soft antiulnar drift straps. However, progressive deformity is not averted with these conservative measures. There is very little information about surgical joint preserving procedures in the literature, but it seems that there is high recurrence of joint deformity after such procedures at the MCP joint level.[18,19]

Systemic Sclerosis

Systemic sclerosis (SSc) is an autoimmune disease in which hand involvement is common. It affects females more often than males and

24) Sobre o bloqueio anestésico interescalênico:

a) é a abordagem mais proximal ao plexo braquial, sendo o ponto de referência a artéria subclávia
b) é ideal para procedimentos no antebraço e mão
c) paralisia do nervo frênico e bloqueio espinhal total são complicações possíveis
d) a distância relativa do nervo frênico e o gânglio simpático cervical explicam porque é pouco frequente a paralisia do nervo frênico e a Síndrome de Horner nesse tipo de bloqueio

Resposta C

referência Green página 5

the clavicle, such as infraclavicular and axillary locations.[42] The advantages include time-extended, opioid-sparing, and site-specific analgesia with only minimal side effects.[74,75] There is also some data to suggest that the incidence of chronic postsurgical pain may be decreased with a short-term postoperative CPNC.[76] Disadvantages include increased anesthesia performance time and catheter dislodgement or misplacement leading to ineffective analgesia. Complications also include ipsilateral diaphragmatic paralysis, technical problems involving the infusion pump leading to dosing inconsistency, infection due to the indwelling catheter, and catheter coiling leading to block failure or catheter retention.[75] Rarely, brachial plexus peripheral nerve catheters have led to epidural and even intrathecal blockade.[77,78] The incidence of brachial plexus catheter failure on postoperative day 1 is between 19% and 26%.[79] The rate of dislodgement is low (<5%) but is directly correlated with the length of time the catheter is maintained and the extent of upper extremity movement.[80] There appears to be a modest clinical benefit to the use of nerve-stimulating catheters over nonstimulating catheters to confirm tip placement; however, this advantage has been largely supplanted by ultrasound guidance, which vastly improves placement accuracy.[81,82] In contrast to epidural catheters, the choice of end-orifice versus multiple-orifice catheters in CPNC does not affect analgesic quality.[83]

Once the patient is at home, peripheral nerve infusion pumps for ambulatory surgery patients are safe and effective for extending the duration of nerve blocks from hours to days. Evidence supports the use of these catheters in children as well as adults.[30]

Minimum Effective Volume

Efforts have been made to determine the minimum effective volume (MEV) of local anesthetic required to produce an adequate block to reduce the dose-dependent adverse effects of neurotoxicity and systemic absorption without sacrificing time to block onset and overall analgesic duration. These efforts have been helped enormously by the use of ultrasound. For the upper extremity, low local anesthetic volumes have been established for interscalene blocks and axillary blocks using ultrasound guidance. Although the absolute effect of type and concentration of local anesthetic on minimal volume has not been elucidated, the MEV to elicit an interscalene blockade that is 95% successful (MEV_{95}) can be less than 1 mL.[69,84] Reducing the anesthetic volume in interscalene blocks has the potential advantage of reducing the incidence of hemidiaphragmatic paresis.[85] For axillary blocks, MEV_{95} averages 2 mL per nerve.[86,87] On the contrary, the MEV_{95} for supraclavicular and infraclavicular blocks ranges from 17 to 32 mL and 23 to 35 mL, respectively.[88-91] We postulate that the higher volume required in the latter blocks may be related to increased variations in injection techniques and nerve anatomy.

Elderly patients generally require lower local anesthetic volumes, an effect likely related to a decrease in the cross-sectional area of the brachial plexus as we age.[92] Similarly, diabetic patients are more likely to have a successful and longer duration nerve block for a given local anesthetic dose.[93,94] The authors postulate that this is due to either an increased sensitivity of diabetic nerve fibers to local anesthetic, an inadvertent intraneural penetration due to a decreased ability to elicit paresthesias, or a preexisting neuropathy leading to decreased baseline sensation to pain. Surprisingly, although associated with a higher performance difficulty, an increased body mass index does not necessitate an increased local anesthetic volume.[95,96]

In general, in the absence of additives, decreasing the dose of local anesthetic in the peripheral block results in a reduction of block duration.[97,98] Despite the advantage of decreasing dose-dependent complications and reducing neurotoxicity, our establishment of the MEV should be tailored with the surgical procedure, the patient's particular risk factors, and the expected postoperative pain. In the end, it is also important to remember that the practitioner and his or her ability to optimally deposit the local anesthetic heavily influence the MEV for any given block.

Brachial Plexus Blocks

The goal of regional anesthesia for upper extremity surgery is to provide anesthesia at the site of surgery. Other potential painful stimuli require consideration, including positioning and the tourniquet. There are many different approaches to nerve blockade, and all involve the brachial plexus that provides sensory and motor innervation to the upper extremity. The brachial plexus is formed by the ventral rami of C5-T1, occasionally with small contributions by C4 and T2 (Fig. 1.1).

There are multiple approaches to blockade of the brachial plexus, beginning proximal at the interscalene interval and moving in a distal direction with the supraclavicular, infraclavicular, axillary, midhumeral, and forearm approaches. The uniting concept is the existence of a sheath encompassing the neurovascular bundle extending from the deep cervical fascia to slightly beyond the borders of the axilla.[99]

Our preferred technique, using ultrasound guidance, involves an in-plane view of the needle at its point of entry just under the skin to its location near the plexus. The needle choice is probably less critical, although we use short bevel, noninsulated needles, which are less likely to injure the nerve and more echogenic. The goal is to get close to the nerve (plexus or cord) without actually contacting the nerve. Once the fascial plane adjacent to the nerve is reached, a small amount of local anesthetic is injected. The anesthetic will hydrodissect the area and demonstrate local filling in the desired location of the nerve.

Interscalene Block

The interscalene block is the most proximal approach, performed as the brachial plexus courses between the anterior and middle scalene muscles, traditionally at the level of the cricoid cartilage (Fig. 1.2).[100] At this level, the nerve roots of C5, C6, and C7 are visualized and course in a longitudinal direction. Between 5 and 10 mL of local anesthetic can be injected between C5 and C6 using a lateral-to-medial approach, avoiding injury to the phrenic nerve. This block is well suited for procedures of the shoulder, the lateral two-thirds of the clavicle, and the proximal humerus. Advantages of this block include rapid and reliable blockade of the shoulder region, as well as relative ease of landmark palpation. Disadvantages of this block traditionally include incomplete coverage of the lower trunk of the plexus (C8 and T1 nerve roots) resulting in insufficient ulnar nerve anesthesia. This problem makes the interscalene block less reliable for forearm or hand procedures. The interscalene block commonly causes transient ipsilateral diaphragmatic paralysis and ipsilateral Horner's syndrome because of the proximity of the phrenic nerve and the cervical sympathetic ganglion, respectively. Rare but serious complications include permanent phrenic nerve palsy and cervical epidural and total spinal blockade.[101]

Selective Superior Trunk Block

In recent years, efforts to increase block target precision for shoulder procedures and reduce the incidence of hemidiaphragmatic paralysis have led to the introduction of selective blockade of the upper trunk.[102] Placement necessitates identification of the upper trunk of the brachial plexus under ultrasound and circumferential injection of 5 to 10 mL of local anesthetic. This technique provides precise motor and sensory blockade to the shoulder while sparing the forearm and hand. Less local anesthetic is injected, which reduces the probability of local toxicity, phrenic nerve paresis, and Horner's syndrome.

25) A prega formada pela flexão das articulações metacarpofalangiana dos dedos médio, anelar e mínimo é a:

a) prega palmar média
b) prega palmar distal
c) prega metacarpofalangiana
d) prega palmar proximal

Resposta B

referência Ed Caetano página 11

A palma da mão apresenta três pregas principais. A de situação proximal é a prega tenar, que se forma pelos movimentos do polegar. A prega palmar média forma-se pela flexão simultânea das articulações metacarpofalângicas dos dedos indicador, médio, anular e mínimo, sendo também chamada de prega dos quatro dedos, e termina unindo-se à prega tenar na borda radial da mão. A prega palmar–distal inicia-se ao nível da comissura entre os dedos indicador e médio e termina na borda ulnar da mão; cruza a área correspondente ao colo do quinto metacarpiano, sendo formada pela flexão metacarpofalângica dos dedos médio, anular e mínimo, e por esta razão é chamada de prega dos três dedos. As pregas do punho são consequência dos movimentos de flexoextensão que ocorrem nesta articulação.

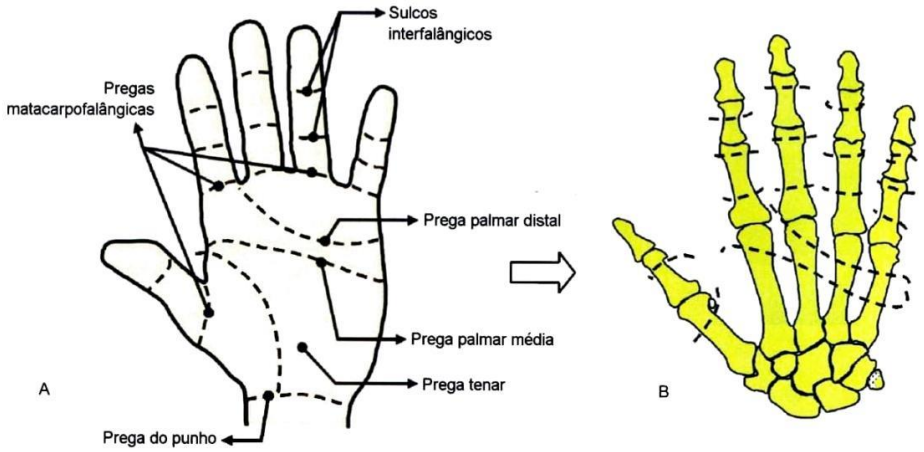

■ **Fig. 1-11A.** Pregas cutâneas digitais e palmares de mão e punho. **B.** As pregas cutâneas digitais e palmares não coincidem com as linhas das articulações.

Podem ser traçadas certas linhas superficiais na mão que permitem a identificação de estruturas nobres situadas profundamente. Assim, palpa-se o osso pisiforme e marca-se um ponto 2cm distalmente a este; outro ponto é marcado na união da prega metacarpofalângica do polegar com a primeira comissura interdigital, e a união desses dois pontos forma a chamada linha cardinal. A linha que acompanha a borda radial do dedo médio e prolonga-se na palma da mão cruza a linha cardinal. Este cruzamento forma o ponto que corresponde à penetração do ramo motor tenar do nervo mediano na musculatura tenar. O prolongamento palmar da linha que passa pela borda ulnar do anular cruza a linha cardinal em um ponto onde está situado o hâmulo do hamato. O meio da linha entre este ponto e aquele marcado 2cm distal ao pisiforme marca o ponto de divisão do nervo ulnar em ramos superficial e profundo e o local de penetração dos fascículos motores deste na eminência hipotenar. A linha cardinal representa também o percurso aproximado do ramo profundo do nervo ulnar na palma da mão, acompanhando o arco arterial palmar profundo.

26) O cruzamento da linha cardinal de Kaplan com a linha que passa na borda radial do dedo médio é ponto de referência da seguinte estrutura anatômica:

a) ramo sensitivo digital do polegar
b) ramo motor do nervo mediano
c) limite distal do arco palmar superficial
d) ramo sensitivo digital radial do dedo indicador

Resposta B
referência Ed Caetano página 12

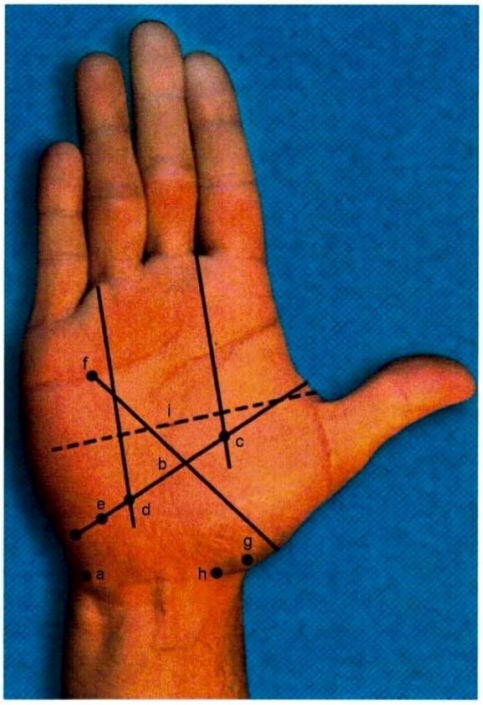

■ **Fig. 1-12.** Pisiforme (a). Linha cardinal (b). Ponto de penetração do n. mediano na musculatura tenar (c). Ponto correspondente ao processo unciforme do hamato (d). Ponto correspondente à divisão do nervo ulnar em ramos superficial e profundo (e). Ponto de cruzamento entre a prega palmar distal e o percurso aproximado dos tendões flexores para o dedo mínimo (f). Tubérculo do trapézio (g). Tubérculo do escafoide (h). Linha correspondente à localização do arco arterial palmar superficial (linha de Kaplan) (i).

Outra linha-guia muito importante pode ser traçada na palma da mão. Marca-se um ponto na prega palmar distal ao longo do percurso dos tendões flexores do dedo mínimo. Este ponto corresponde ao colo do quinto metacarpiano. Outro ponto é marcado 2cm distal ao tubérculo do trapézio. A união desses dois pontos marca uma linha que, ao nível da base da eminência tenar, indica, exatamente, a linha articular da articulação trapeziometacarpiana. O acesso cirúrgico a essa articulação deve ser feito do lado radial do tubérculo do trapézio, pois o ramo cutâneo palmar do nervo mediano passa do lado ulnar, junto ao tubérculo do trapézio. A presença deste ramo cutâneo palmar deve ser lembrada nas incisões cirúrgicas na face ventral do punho, para abertura do túnel carpiano, abordagem do semilunar, ou para reparações de tendões e nervos neste nível. O tubérculo do trapézio pode ser palpado distalmente ao tubérculo do escafoide, que está situado abaixo do tendão do músculo flexor radial do carpo.

Uma linha que passa pela polpa digital do polegar, estando este dedo em abdução e extensão, e que seja perpendicular à linha de prolongamento palmar da borda ulnar do anular, marca a localização do arco arterial palmar superficial. O arco arterial palmar profundo localiza-se 1,5 a 2cm proximal a este.

No dorso da mão também existem certos pontos e linhas superficiais que permitem a identificação de importantes estruturas. Assim, a linha que passa pelo centro do dedo médio em extensão prolonga-se proximalmente, passando exatamente sobre a articulação escafossemilunar e seguindo do lado ulnar em relação ao tubérculo de Lister.

27) O ângulo escafolunar varia da flexão máxima a extensão máxima, respectivamente:

a) 80° a 46°
b) 70° a 61°
c) 76° a 35°
d) 52° a 71°

Resposta C

referência Cooney página 90

According to the experiments by Ruby et al.,[143] from full flexion to full extension of the wrist, the scaphoid rotates an average of 80 degrees with respect to the radius, whereas the lunate rotates only 58 degrees and the triquetrum, 71 degrees. Horii et al.[72] found somewhat different relative values for the scaphoid, lunate, and triquetrum rotations during wrist flexion-extension (111 degrees, 76 degrees, and 88 degrees, respectively) (Table 4.4). The fact that the scaphoid has a larger amount of rotation than the lunate during wrist flexion-extension can be easily checked if one compares the relative alignment of these bones on lateral radiographs during flexion-extension: the average scapholunate angle in full wrist flexion averages 76 degrees; it decreases to 35 degrees in full extension (Fig. 4.17).[122,145] The different radii of curvature of the proximal aspects of these bones may explain the differences in angular rotation.

The relative motion at the scapholunate and lunotriquetral joints from flexion to extension of the wrist averaged 24 degrees and 18 degrees, respectively, in the experiments performed by Ruby et al.[143] experiments. According to the data of Horii et al.,[72] however, there is almost three times as much motion at the scapholunate interval than at the lunotriquetral joint (34 degrees and 12 degrees, respectively). Also Smith et al.,[162,163] de Lange et al.,[42,43] Savelberg,[146] and Garcia-Elias et al.[56] found a scapholunate relative motion larger than 30 degrees during wrist flexion-extension. Despite differences in absolute values of angular rotation, however, the direction of motion found by all the authors is quite consistent: during wrist flexion, the bones of the proximal carpal row go into flexion and ulnar deviation, whereas during wrist extension, they go into extension and radial deviation (Fig. 4.18).[17,42,56,72,143,162] Such a kinematic behavior essentially remains the same even when changing the axial rotation of the forearm.[81]

The contribution of the midcarpal joint to normal wrist flexion-extension is also an interesting issue. Patterson et al.[135] showed that during global wrist motion, the radiolunate joint contributes more to the motion during wrist flexion than the capitolunate joint, while

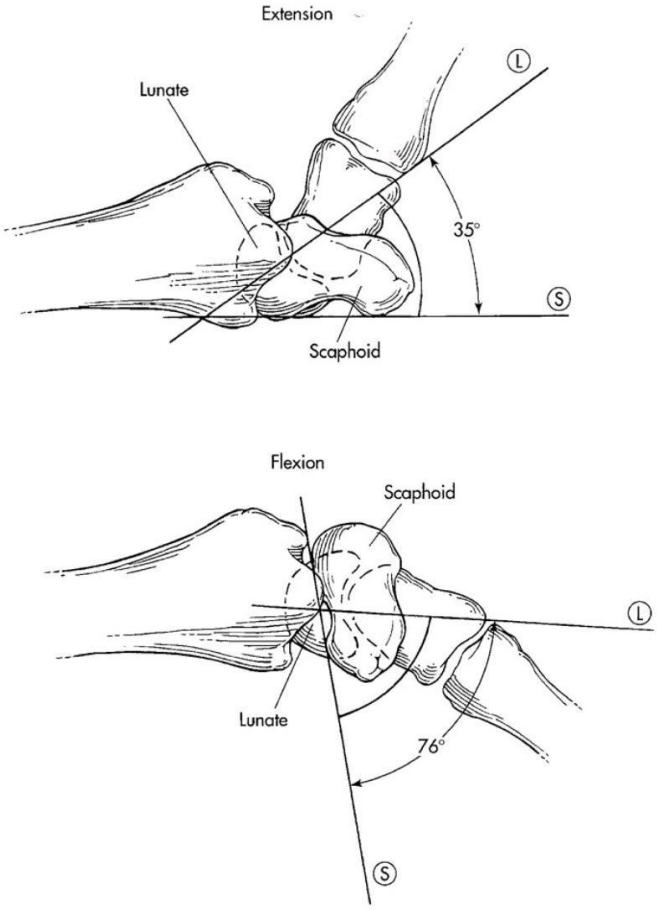

FIGURE 4.17. The scaphoid has a larger amount of rotation than the lunate during wrist flexion-extension. According to Nakamura et al.,[122] the scapholunate angle, determined by the axes of the scaphoid (S) and lunate (L), varies from an average 76 degrees with wrist flexion to 35 degrees in extension.

28) O teste de Berger consiste em:

a) paciente se mostra incapaz de fazer preensão de um cartão ou folha entre os dedos, para diagnóstico de lesão do nervo ulnar
b) abdução contra resistência entre o polegar e o dedo anelar do paciente provoca dor na cabeça da ulna, para diagnóstico de tendinite do tendão extensor ulnar do carpo
c) manter os dedos fletidos por 60 segundos provoca parestesia no território do nervo mediano, para diagnóstico de Síndrome do túnel do carpo
d) flexão do punho contra resistência provoca dor no epicôndilo medial, para pesquisa de epicondilite medial

Resposta C

referência Cooney página 1109

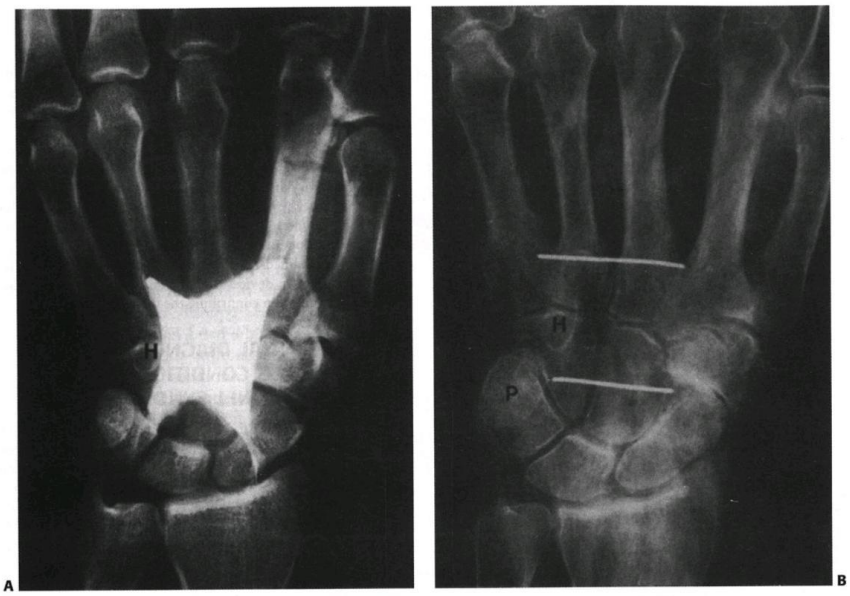

FIGURE 56.5. A. Radiographic contrast material outlining the borders of the carpal tunnel. **B.** Lines representing border of carpal tunnel superimposed on radiograph. *H,* hamate; *P,* pisiform. (From Cobb TK, Dalley BK, Posteraro RH, et al. Anatomy of the flexor retinaculum. *J Hand Surg Am.* 1993;18:91–99. Copyright, American Society for Surgery of the Hand, by permission of Churchill Livingstone.)

the motor branch to the thenar eminence, resulting in no muscle changes in severe CTS, or a proximal median to ulnar sensory crossover (or vice versa), resulting in an atypical sensory distribution.

Sensory examination may be performed in various ways from simple light touch or temperature recognition to pinprick, vibration, two-point discrimination, and monofilament fiber testing. Although the results of all of these tests are significant, actual objective sensory loss is identified only in advanced cases of CTS, and subjective paresthesias or dysesthesias in the median nerve distribution are a significant clinical finding. In instances of advanced sensory loss, diminished sweat pattern in the median nerve distribution may be found.

Atrophy of the opponens muscle is a finding in advanced CTS (Fig. 56.8A). It may be inaccurately diagnosed in the presence of thumb carpometacarpal arthritis in which metacarpal subluxation stretches the opponens muscle, leaving a flat appearance adjacent to the metacarpal. Opponens muscle weakness alone can be an earlier finding in CTS but is difficult to identify. To test for motor weakness associated with CTS, the opponens muscle only should be examined. To do this, the patient is asked to place the back of the hands on a table and point the thumb tip at the ceiling (Fig. 56.8B). The examiner then attempts to flatten the thumb on the table with two fingers. Most people with normal opponens power are able to prevent the force of the examiner's two fingers from flattening the thumb to the table. Opponens weakness is more commonly a sign of advanced CTS.

Several provocative signs for CTS have been discovered and are extremely useful in diagnosing the condition. First, the nerve should be located just ulnar to the palmaris longus tendon (Fig. 56.9A). The Tinel sign demonstrates irritability of a nerve, as evidenced by direct tapping with a mallet or finger directly on the median nerve. If struck vigorously, any peripheral nerve responds by sending sensible electrical shock sensations in the distribution of the nerve. In CTS, tapping the median nerve at the wrist causes tingling or paresthesias (or both) in part or all of the distribution in the hand.[75] Occasionally, an electric shock sensation also is transmitted proximally toward the elbow along the course of the median nerve.

Phalen's test (Fig. 56.9B) is performed by asking the patient to maximally palmar flex the wrist for 60 seconds (or possibly doing it yourself). The test is considered positive if paresthesias occur in the median nerve distribution of the hand.[62] Instant or early paresthesias are consistent with more severe CTS. Modifications of this test include placing the hand in maximum dorsiflexion with the fingers extended (reverse Phalen's) (Fig. 56.9C) or holding the fingers flexed (Berger's test)[7] (Fig. 56.9E), which may crowd lumbrical muscles into Guyon's canal.

29) A melhor indicação para transferência do dedo do pé para mão é na

a) Mão torta radial
b) Hipoplasia de polegar tipo IIIb de Blauth
c) Síndrome da banda de constrição
d) Hipoplasia de polegar tipo IIIa de Blauth

Resposta C

referência Green página 1823, 1825

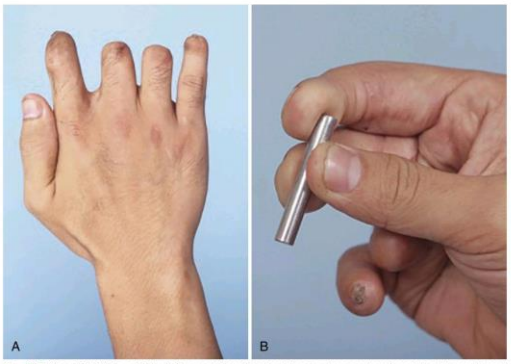

Fig. 47.4 **A** and **B,** With multiple-digit amputation, it is best to aim at reconstructing at least two adjacent fingers to provide useful tripod pinch, stronger hook grip, lateral stability, and handling precision.

is available to achieve the aforementioned goals of digital reconstruction. A combination of toe transfer, ray amputation, and lengthening procedures may be necessary. To simplify management, the hand is converted into an acceptable one (del Piñal classification) by means of toe transfer to the distally amputated finger and ray amputation to the proximally amputated finger with great effort to provide three functioning fingers whenever possible.[3,73]

Reconstruction of the Metacarpal Hand

A more severe functional deficit and deformity are present when mutilating hand injuries involve all digits at a proximal level, with or without thumb amputation—a condition referred to as metacarpal hand.[13] The senior author (F-C Wei) and his colleagues have proposed a practical classification of metacarpal hands and defined specific reconstructive options for toe transplantation (Tables 47.1 and 47.2).[18,27,31,74,75] This classification divides the metacarpal hand into two types for reconstructive purposes.

In type I, amputation has occurred in all fingers proximal to the middle of the proximal phalanx, and the thumb is either intact or amputated distal to the IP joint (considered the minimum functional length required for precise prehension). In type II, amputation of all fingers is proximal to the middle of the proximal phalanx, with thumb amputation proximal to the IP joint. For the type I metacarpal hand, it is recommended that at least two adjacent digits be replaced. Depending on the finger amputation level relative to the MCP joint (subtypes IA, IB, and IC), bilateral lesser toes or combined second- and third-toe transplantation can be used for reconstruction. For the type II metacarpal hand, a systematic strategy must be followed for the selection of donor toes and reconstructive stages.

If thenar muscle function is adequate (subtypes IIA and IIB), simultaneous reconstruction of the thumb and two adjacent fingers in one stage is preferable (Fig. 47.6). If thenar muscle function is inadequate (subtype IIC), a staged reconstruction is appropriate; the fingers are reconstructed first, and a prosthetic thumb post is used temporarily to assist in determining the length and position of the transferred toe for thumb reconstruction during the second stage (Fig. 47.7). Even more complex are conditions in which both hands are involved because the selection of donor toes should take into account functional impairment and deformity of the feet.[27,31]

In the bilateral type II metacarpal hand, the dominant hand can be reconstructed with three toes to achieve tripod pinch, and the nondominant hand can be reconstructed with two toes to provide key or pulp-to-pulp pinch.[74-76] The five toes harvested can be the right second and third toes and the left great, third, and fourth toes, sparing the second toe for foot balance.[76] Our experience has revealed good functional recovery of the hands and no significant donor site morbidity with such an approach (Fig. 47.8).

Congenital and Traumatic Loss of Digits in a Pediatric Hand

O'Brien and colleagues described the first toe-to-hand transfer for a congenital hand anomaly in 1978 and several series on different hand malformations, including but not limited to thumb hypoplasia, adactylous hand, symbrachydactyly, and so on.[77-82,85]

For traumatic amputation of fingers in the pediatric population, management is similar to what has been described thus far. Replantation should always be attempted even in single-digit amputation. In nonreplantable digit(s), toe-to-hand transfer should be discussed with the parents extensively, and this complex procedure is clearly indicated even in the setting of a single-digit amputation. However, timing is affected by the child's age (2 years old), and primary transfer is usually avoided in children younger than this.

For congenital absence of fingers, constriction ring syndrome is the ideal indication because the joints, muscles, and tendons proximal to the amputation site are typically present and normal. However, aplastic or hypoplastic conditions, including symbrachydactyly, have also been addressed successfully with toe transfers (Fig. 47.9).[3,79] Thumb hypoplasia,

TABLE 47.2 Type II Metacarpal Hand

Subtype	Level of Thumb Amputation	Level of Finger Amputation	Recommendations
IIA	Distal to metacarpal neck	Four fingers at any level proximal to middle of proximal phalanx	Whole or trimmed great-toe transfer (transproximal phalanx transfer)
IIB	Proximal to metacarpal neck with adequate thenar muscle function	Four fingers at any level proximal to middle of proximal phalanx	Preliminary distraction lengthening or interpositional bone graft, followed by whole or trimmed great-toe transfer *or* Transmetatarsal second-toe transfer
IIC	Any level with inadequate thenar musculature	Four fingers at any level proximal to middle of proximal phalanx	Thumb reconstruction in a second stage after finger reconstruction *and* Tendon transfer to restore opposition
IID	Any level with damaged carpometacarpal joint	Four fingers at any level proximal to middle of proximal phalanx	Same as for IIA and IIB, but aiming at reconstruction of an immobile thumb post

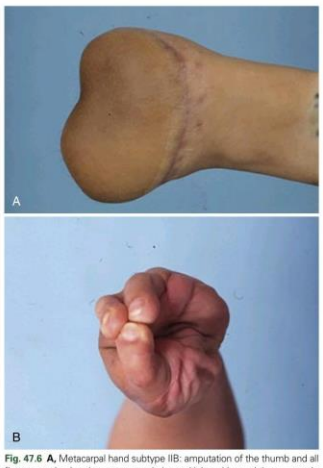

Fig. 47.6 **A,** Metacarpal hand subtype IIB: amputation of the thumb and all fingers proximal to the metacarpophalangeal joint with good thenar muscle function. **B,** Tripod pinch after reconstruction of the thumb by trimmed great-toe transplantation and reconstruction of the two radial fingers by combined transplantation of the second and third toes from the contralateral foot.

in particular, remains controversial because many surgeons believe that results obtained by pollicization are better than toe transfers.[3] Reconstruction of the adactylous hand is usually a staged procedure; although reconstructing the thumb is suggested for the first stage followed by ulnar digit reconstruction in the second stage, it can be done in reverse order.[82]

Technical considerations in congenital reconstructions are similar to those outlined elsewhere in this chapter with a few notable exceptions. Although Lister described performing successful transfers in children as early as 6 months to 1 year old, toe transfer should usually not be attempted until the patient is around 2 years old, when the vessels are of adequate caliber for microvascular anastomosis. Another consideration regarding timing is the unilateral type of the anomaly. It is best to treat children with unilateral malformations early, before adaptive patterns are developed and the use of the abnormal hand is superseded by the normal hand. This situation does not occur in children with bilateral deficiencies.

In aplastic cases, the recipient vessels, nerves, and tendons must be identified before toe harvesting. The toes themselves also may be abnormal in patients with congenital hand abnormalities. As with adults, the first dorsal metatarsal artery (FDMA) is usually dominant and provides the pedicle for the flap. When multiple digits are required, flaps combining two or three toes can be transferred based on the plantar arch. Bony fixation must preserve the epiphyseal plates. Recipient tendons in the aplastic hand may be absent, and primary tendon transfers may be required.[9]

Success rates as high as 96% have been reported. Sensory recovery is usually quite good, with moving two-point discrimination of 5 mm in the series of studies of Foucher and coworkers.[3] However, the most commonly encountered problem is the unpredictable range of motion of the transplanted toe. Transferred toes usually have minimal active DIP motion, an extension deficit at the PIP joint, and a fixed-flexion deformity. Foucher and colleagues reported on 58 children with 65 toe-to-hand transfers with a mean active range of motion of 38 degrees and a mean extension lag of 25 degrees.[3] Nevertheless, children appear to incorporate the transferred toe into their hand function quite well. Growth of the transferred toe is 60% to 100% of the normal toe.[3,77]

ANATOMY FOR TOE DISSECTION

Most surgical procedures involved in partial or total toe transplantation use the arterial pedicle to the great and second toe. Several authors have proposed various classifications of the vascular anatomy in the first metatarsal space.[7] All of them describe anatomic variations in the origin of the FDMA; in the relationship between the FDMA and the interosseous muscle; and intermetatarsal ligament, FDMA diameter, and branching patterns. These descriptions have created an image of a complex and highly variable network of vessels in the first–second metatarsal interspace, making the vascular anatomy difficult to understand.

Classically, with most surgical techniques, vascular dissection begins proximally in the dorsum of the foot to identify and follow the

30) Levando em consideração o novo algoritmo para o tratamento da doença de Kienbock proposto por Litchman, quando a doença se manifesta na infância a melhor conduta é:

a) encurtamento do rádio
b) enxerto vascularizado
c) tratamento conservador (imobilização)
d) encurtamento do capitato

Resposta C

referência Green página 731, 733

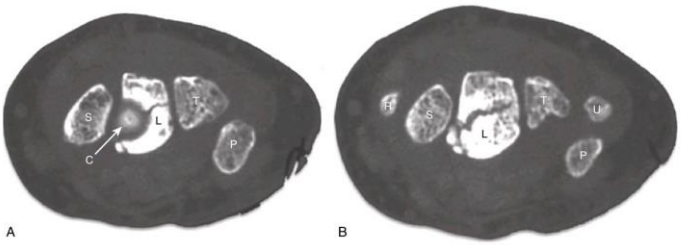

Fig. 16.64 Capitate nutcracker. **A,** The capitate is seen at the center of the "target sign" on the radial aspect of the lunate. **B,** A coronal fracture propagating across the lunate. (From Bain GI, MacLean SBM, Yeo CJ, et al. The etiology and pathogenesis of Kienböck disease, *J Wrist Surg* 5[4]:248–254, 2016. Copyright © Dr. Gregory Bain.)

BOX 16.2 New Algorithm for the Treatment of Kienböck Disease

A. Patient's Age?
A1. <15 years A2. 16–20 years A3. >70 years
Good natural history: Extended nonoperative management

B. State of the Lunate?
B1. Lunate intact (Lunate intact: Lichtman 0, I, II, Bain 0)
Protect lunate: Lunate unloading procedure
B2. Lunate compromised (Localized lunate disease: Lichtman IIIA, Bain 1)
Protect lunate and reconstruction: Unloading, VBG, Osteochondral graft
B3. Lunate not reconstructible (Advanced lunate disease: Lichtman IIIC, Bain 2b)
Motion preserving procedure: PRC, SC fusion

C. State of the Wrist?
C1—Carpal instability: Scaphoid flexion: RSA > 60 degrees (Lichtman IIIB)
C2—Localized degeneration (Lichtman IIIA, Bain 2a)
Motion preserving procedure: PRC, SC fusion (RSL fusion)
C3—Advanced degeneration (Lichtman IV, Bain 4)
Salvage: Wrist fusion

PRC, Proximal row carpectomy; *SC*, scaphocapitate; *VBG*, vascularized bone graft.
Modified from Lichtman DM, Pientka WF, Bain GI. The future of Kienböck's disease: a new algorithm. In: Lichtman DM, Bain GI (eds). *Kienböck's Disease: Advances in Diagnosis and Treatment*, New York, Springer, 2016:307–320.

Recommended technique includes using a 3.0T MRI with the following sequences: proton density (PD) weighted fast spin echo (FSE) with fat-saturation (coronal and axial planes), T1-weighted FSE unenhanced coronal images, T1-weighted FSE fat-saturation after IV gadolinium contract (coronal and sagittal).[284]

MRI with gadolinium enhancement. The perfusion state of the bone marrow can be better assessed with gadolinium-enhanced MRI on fat-saturated T1-weighted sequences (contrast-enhanced MRI [ceMRI]).[270] Areas of enhancement are characteristic of the repair zone in Kienböck disease and normal unaffected bone marrow remains unenhanced.

The Schmitt classification outlines three patterns suggestive of a viable lunate based on ceMRI[270,282] (Fig. 16.67):

- a: Normal. Homogenous enhancement of entire lunate
- b: Ischemic. Homogenous proximal enhancement, indicating perfusion (Fig. 16.68)
- c: Partially necrotic. Heterogenous contrast with three different perfusion zones[270,282]
  - Proximal: Decreased signal with no T1 enhancement indicates osteonecrosis.
  - Middle: Hyper-enhancement indicates repair.
  - Distal: normal signal in normal marrow
- d: Necrotic (viability lost). Generalized signal loss; absence of perfusion

Other imaging. New advanced imaging techniques, such as four-dimensional CT and SPECT, may prove to have a greater place in the assessment of complex cases.[271]

Arthroscopic assessment. Arthroscopy allows a detailed inspection and palpation of the articular and ligamentous structures of the joint with minimal risk of soft tissue disruption.

Diagnostic arthroscopy is performed with traction and a 2.7-mm, 30-degree arthroscope. Routine portals (3-4, 6R, midcarpal radial [MCR], and midcarpal ulnar [MCU]) are used. Since fluid pressure can collapse the capillaries, dry arthroscopy provides superior visualization of articular surfaces and synovitis. Inspection and probing of the articular surfaces of the lunate and surrounding carpus need to be performed.

Key arthroscopic findings include the following:

1. "Functional" articular surfaces appear smooth and glistening and firm to palpation. Minor fibrillation is still considered a functional articulation.[268]
2. "Nonfunctional" articular surfaces include extensive fibrillation, fissuring, floating chondral surface, or fracture[266,268] (Fig. 16.69).
3. Synovitis is identified in all patients with Kienböck disease, and the extent of the synovitis is related to the severity of the condition.[266]

Fig. 16.66 Sagittal and coronal views on a CT scan clearly showing a coronal fracture and fragmentation of the lunate. (From MacLean SBM, Bain GI. Hand and wrist avascular necrosis. In: Weiss APC [ed]. *The Textbook of Hand & Upper Extremity Surgery*, 2nd ed, Chicago, American Society for Surgery of the Hand, 2020. Copyright © Dr. Gregory Bain.)

contrast-enhanced MRI.[282] The Bain and Begg classification assesses the articular surfaces of the lunate and wrist during wrist arthroscopy.[266,288]

The new algorithm developed by Lichtman and Bain incorporates the osseous, chondral, and vascular status of the lunate as well as the secondary effects on the wrist and combines elements of the three main classification systems[230,291] (see Box 16.2 and Fig. 16.71).

Management. The choice of management of Kienböck disease has been controversial since Robert Kienböck first described the condition.[230] The natural history remains poorly understood, but we do know that the disease occurs along a spectrum from minimal changes to advanced collapse and degeneration. The associated pain may range from minor to debilitating. Therefore management should be based on specific treatment aims.

Aims of treatment. The aims of treatment are to:

1. Improve the patient's pain.
2. Protect the lunate from collapse.
3. Protect the wrist joint from collapse and degeneration.
4. If the lunate is compromised, consider reconstruction.
5. If the lunate is not reconstructible or the wrist is unstable or degenerate, consider a motion-preserving reconstructive procedure.
6. If the wrist is not reconstructible, consider a salvage procedure.

Factors for consideration. There are many factors to consider in individualizing the management plan including patient characteristics and the state of the lunate and wrist (Table 16.6).

Age. Age is an important prognostic factor in Kienböck disease, and the vast majority of pediatric Kienböck disease patients will experience complete radiographic and clinical improvement following a period of immobilization in a splint or cast.[292] In the older child or teenager with "juvenile osteomalacia," recalcitrant cases do occur.[293] Patients with ulnar-negative variance may benefit from a radial shortening osteotomy. Ulnar-neutral or ulnar-negative patients may benefit from radial closing wedge osteotomy or temporary STT joint pinning.[293-296]

Intact lunate. For the intact lunate (B1), the lunate can be protected with a lunate unloading procedure.

Reconstructible lunate. The reconstructible lunate (B2) is usually compromised with collapse of the proximal osseous lunate, but with intact articular cartilage. In this case a bone graft can be used to help fill the void in the proximal lunate. A lunate unloading procedure may also be included to protect the compromised lunate.

A scaphocapitate wire will reduce loading of the lunate to facilitate healing, especially for the type B2 lunate.

Unreconstructible lunate. With severe fragmentation and collapse (B3), the unsalvageable lunate requires excision. If there is a fixed secondary carpal instability (C1) or degenerative changes in the central column (C2), then a motion-preserving procedure should be considered.

What can the surgeon offer in the health care system?. This is an important question, with each surgeon and health system having different challenges. There are many variables including the surgeon's experience and skills, hospital facilities, cost of health care, insurance status, and government restrictions (e.g., U.S. Food and Drug Administration [FDA]). These factors in part explain the considerable variability in recommended treatment.

Advanced techniques. The above concepts are aimed to provide care for the majority of patients with Kienböck disease. There are some

31) Sobre o procedimento de Leechavengvongs:

a) é necessário haver força de tríceps M3 para indicar esse procedimento
b) é esperada reinervação do deltóide em até 3 meses
c) utilizamos o ramo tricipital da cabeça lateral do nervo radial para neurotização com o nervo axilar
d) busca-se neurotizar todo o nervo axilar mirando a reinervação do deltóide e do redondo menor

Resposta D

referência Green página 1329

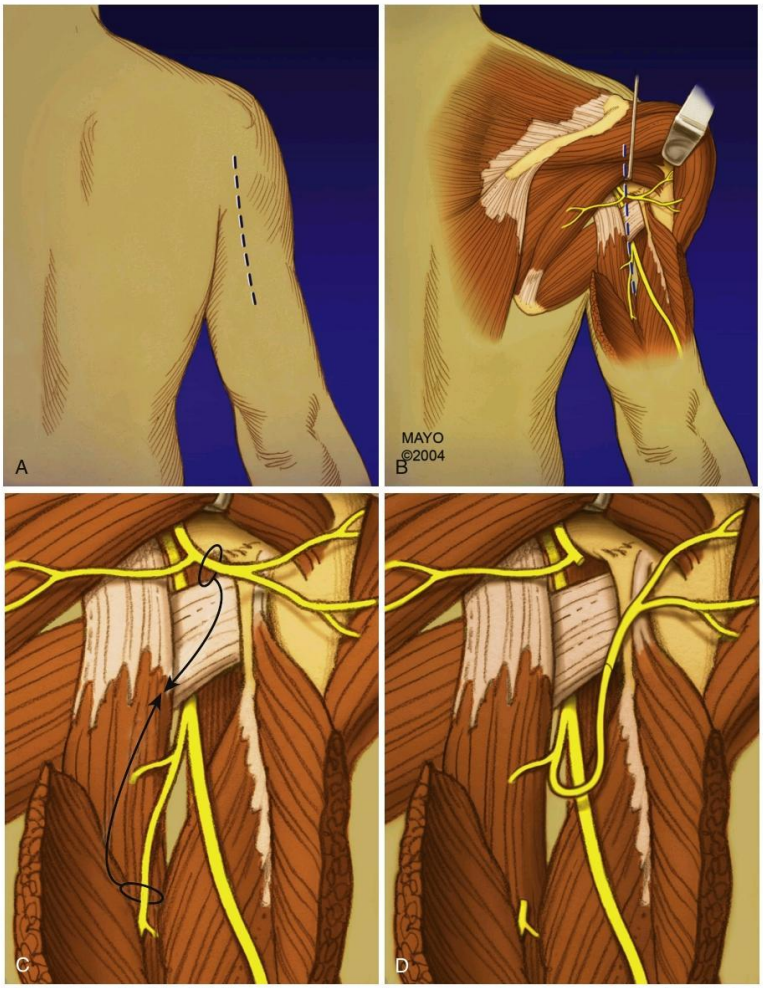

Fig. 34.28 Transfer of the right triceps branch to the axillary nerve (Leechavengvongs procedure). **A,** Skin incision. **B,** Identification of the axillary nerve in the quadrilateral space and the radial nerve and triceps branches in the triangular interval. **C,** The long head triceps motor branch is selected and transferred to the anterior division of the axillary nerve. **D,** Direct nerve repair without tension. (Used with permission of Mayo Foundation for Medical Education and Research. All rights reserved.)

the quadrilateral space. It is useful to identify and trace the axillary sensory branch back toward the quadrilateral space to help identify the main nerve. The anterior division of the axillary nerve is selectively targeted. It is dissected toward the quadrilateral space and transected as far proximally as possible. Depending on the size match, the axillary nerve proper is occasionally reinnervated by one or more triceps motor branches; more commonly, we perform reinnervation of only the anterior division of the axillary nerve. A theoretical rationale for targeting the entire nerve is to simultaneously reinnervate the teres minor muscle, which is an important external rotator of the humerus.[91]

Next, the interval between the long and lateral heads of the triceps is deepened to expose the radial nerve and its branches to the three heads of the triceps. We typically select the triceps long head motor branch, as originally described by Leechavengvongs and colleagues,[92] and confirm its identity and function with stimulation. The chosen triceps motor branch is mobilized proximally and distally, including all subbranches to the muscle. One should determine how long the triceps branch needs to be to reach the anterior division of the axillary nerve before distal transection of this branch. If needed, release of the teres major fascia is performed to increase proximal mobilization of the

32) Os microrganismos que estão relacionados, respectivamente, com mordida de animais, mordidas humanas e diabéticos ou usuários de drogas intravenosas são

a) Eikenella corrodens, Pasteurella multocida e fungos
b) Pasteurella multocida, Eikenella corrodens e anaeróbicos
c) Eikenella corrodens, fungos e Pasteurella multocida
d) Pasteurella multocida, Eikenella corrodens e fungos

Resposta B

referência Green página 17, 18

2

Acute Infections of the Hand

Milan V. Stevanovic, Frances Sharpe

To paraphrase Hans Zinsser, the prolific bacteriologist and epidemiologist: No matter how clean and regulated our society becomes, bacteria, viruses, and protozoa will always lurk in the shadows, ready to pounce when neglect, poverty, or famine weakens one's defenses.

GENERAL PRINCIPLES

Hippocrates' principles for the treatment of hand infections are fundamentally valid today. Wounds were kept clean with frequent changes of wine-soaked dressings. Dressings were kept loose "so as not to intercept the pus, but to allow it to flow away freely."[1] Coupled with these early principles is the pioneering work of Dr. Alan Kanavel, a Chicago general surgeon who treated hand infections in the preantibiotic era. Much of our current understanding of the pathogenesis and treatment of hand infections must be credited to his extensive dissections and innovative injection studies. Through these studies, he demonstrated the potential spaces of the hand and the pathogenesis of infection. From this data, he developed the surgical principles that remain the cornerstone of modern treatment of hand infections.[2]

Hand infections can result in severe disabilities, including stiffness, contracture, and amputation. These complications have been substantially reduced through the introduction of antibiotic therapy in conjunction with surgical treatment. Although antibiotics have dramatically reduced the morbidity associated with hand infections, their use does not supplant the need for expedient and proper surgical intervention. Several factors influence the outcome of hand infections. These include the location of the infection, infecting organism, timing of treatment, adequacy of surgical drainage, efficacy of antibiotics, and health status and immunocompetence of the host. In the words of one of the preeminent U.S. public health officials, Dr. Charles V. Chapin: "As it takes two to quarrel, so it takes two to make a disease, the microbe and the host."

Host factors play a determining role in the severity and duration of infection. Many medical conditions reduce host defenses. Malnutrition, alcoholism, autoimmune diseases, chronic corticosteroid use, hepatitis, and human immunodeficiency virus (HIV) infection are some of the comorbidities to be considered. The most prevalent disease associated with immunosuppression is diabetes mellitus, which affects approximately 10% of the adult population of the United States.[3,4]

Early and superficial infections may respond to nonsurgical management. However, most acute infections of the hand represent surgical emergencies. Swelling and edema associated with an infection result in increased tissue pressure and can cause ischemia and tissue necrosis by a process resembling compartment syndrome.[5] Furthermore, toxins produced by the offending pathogen can cause vascular thrombosis and tissue death. Patients with necrotizing fasciitis and gas gangrene need *immediate* surgical care.

Types of Infections

Cellulitis is an infection of the subcutaneous tissue, which is often diffuse and can be associated with lymphangitis. It is caused by a single organism, usually *Staphylococcus aureus* or β-hemolytic *Streptococcus*. Lymphangitic streaking is more commonly seen with β-hemolytic streptococcal infections. It generally has a more distal nidus and spreads in a proximal direction. Cellulitis is a non–pus-forming infection and as such is initially treated nonsurgically. If the cellulitis is not responding to intravenous therapy over 12 to 24 hours, this often suggests the formation of pus *(abscess)* and more serious infection. Even in the absence of abscess formation, cellulitis associated with substantial swelling may require surgical decompression (e.g., necrotizing fasciitis). Cellulitis often requires hospital admission and close monitoring to assess the response to antibiotic therapy. A specific type of staphylococcal infection is the *staphylococcal scalded skin syndrome*, primarily a disease of young children that results from an exfoliative toxin-producing staphylococcal organism.[6,7] A high index of suspicion and early differentiation of this process from other skin conditions are important to treatment outcome. Although this syndrome is extremely rare in adults, it is associated with a high mortality rate, usually because of serious underlying illness, such as kidney failure or immunosuppression.[7] Detection of the exfoliative toxin is required for diagnosis. Immunologic methods allow for more rapid detection.[8] Prompt antibiotic therapy and local wound care are the mainstays of management. Both staphylococcus species and streptococcal species can produce toxins that can cause shock and multiorgan system failure. Streptococcus pyogenes, group A *Streptococcus* (GAS), can cause sepsis, shock, and rapid demise. *Necrotizing fasciitis* is a serious life-threatening infection that may initially resemble cellulitis. Although purulence is not present, a watery discharge often described as "dishwater-like fluid" may be seen superficial to the fascia. Most other hand infections are generally pus forming and are discussed in detail throughout the chapter.

The most common infecting organisms are *Staphylococcus* and *Streptococcus* species, with staphylococcal organisms predominating. Many infections, especially those associated with bite wounds, those associated with gross contamination, or those seen in diabetic patients, are often polymicrobial infections. *Pasteurella multocida* should be considered in most animal bites, and both streptococcal species and *Eikenella corrodens* should be considered in human bite wounds. Anaerobic infection is less common

but should be considered in diabetic patients or intravenous drug users. Empirical antibiotic therapy should be tailored toward the most likely offending pathogen. The local prevalence of antibiotic-resistant organisms should be considered when starting empirical treatment. An infectious disease specialist familiar with the hospital-specific patterns of antibiotic resistance can be invaluable in directing antibiotic therapy and in managing outpatient intravenous therapy.

Methicillin-Resistant *Staphylococcus aureus* Infections

The increasing incidence of infection with methicillin-resistant *S. aureus* (MRSA) has been recognized throughout the surgical and infectious disease literature. A strain of *S. aureus* resistant to methicillin was mentioned in reports from the United Kingdom in 1961. This strain was soon identified worldwide and was associated with hospital-acquired infections (HA-MRSA).[9] Only a handful of successful HA-MRSA clones are responsible for the majority of infections, and different clones dominate in different geographic locations.[10] However, MRSA infections have been increasingly identified as community-acquired infections (CA-MRSA). There are unique microbiologic and genetic properties distinguishing the hospital-acquired and community-acquired strains. A community-acquired infection is defined as occurring in patients with MRSA identified by culture who have no history of a hospital or medical facility stay within the past year, who have no history of dialysis or surgery occurring within the past year, and in whom no indwelling catheters are present.

CA-MRSA is now the predominant strain in hand infections, found in up to 40% to 60% of *S. aureus* infections.[11-14] The majority of CA-MRSA infections in the United States have been caused by a single clone (USA300). One of the distinguishing features in CA-MRSA is the frequent gene sequence encoding for Panton-Valentine leukocidin (PVL), a potent toxin that leads to the characteristic tissue necrosis commonly seen in the clinical setting.[15] Of recent concern is the increased incidence of multidrug-resistant MRSA, with resistance to clindamycin and levofloxacin. Kistler et al. reported on the patient factors associated with specific drug resistance. Risk factors for clindamycin resistance included nosocomial infections, a history of intravenous drug use, and hepatitis C. Risk factors for levofloxacin resistance included a history of diabetes and a fever upon initial presentation.[14,16,17]

MRSA infections frequently have a characteristic appearance of a dermonecrotic skin lesion (Fig. 2.1). They are often mislabeled by patients as "spider bites" due to their appearance.[18] Recently, we have not seen the extensive tissue necrosis with MRSA infections that we have in the past. Empirical treatment of hand infections has also changed to address potential MRSA infections.[12,14,17,19] Successful treatment requires surgical debridement with excision of necrotic tissue in conjunction with appropriate antibiotic therapy.

Nosocomial Infections

The hand is a very well-vascularized region, making it less vulnerable to postoperative infection than other anatomic sites, with an incidence of deep postoperative infection of less than 1%.[20-22] *S. aureus* is the most common pathogen in clean surgical procedures.[23-25] The use of perioperative intravenous antibiotics within 1 hour preceding surgery has greatly reduced the incidence of postsurgical infections in general orthopedic practice.[26] The benefit of perioperative intravenous antibiotics in the total joint population was generalized to all orthopedic procedures, leading to antibiotic overuse for clean soft tissue procedures. In particular, the use of perioperative antibiotics in elective hand surgery

Fig. 2.1 Characteristic appearance of MRSA infection with central skin necrosis and surrounding erythema. Purulence is not always present. Soft tissue necrosis is often more extensive than would be expected from a localized infection. (Copyright courtesy of Milan Stevanovic and Frances Sharpe.)

has been overused despite strong support that it does not decrease the incidence of surgical site infections in elective soft tissue procedures of the hand.[21,27-32] The use of antibiotics may be related in part to institutional policies rather than to surgeon preference. Ultimately, the whole patient and any underlying comorbidities must be considered. Prophylactic antibiotics in patients with joint arthroplasties have been recommended to protect the prosthesis more than to prevent surgical site infection, although one recent study has demonstrated no difference in prosthetic joint infection with or without prophylactic antibiotic therapy.[30] Patients with an altered immune response may have a potentially greater benefit from prophylactic antibiotics than an immunocompetent host. For surgical procedures that involve exposure of the bone or joint or those involving implants, we routinely administer intravenous prophylaxis.

Surgical site preparation has transitioned predominantly to the use of prep sticks to clean the surgical site. Recent studies suggest that the use of DuraPrep and Betadine were better than ChloraPrep for skin decontamination in the hand, with the majority of pre and post-prep colonies consisting of *Bacillus* species.[33] Beredjiklian and colleagues showed a five times greater area of unprepped skin surface when comparing a prep stick to soaked 4 × 4 gauze sponges. However, both methods demonstrated <1% unprepped skin surface area.[34] Given the low rate of infection following clean surgery of the hand, the clinical implications remain unknown.

Patient Evaluation

Clinical examination remains the hallmark of diagnosis in hand infections. Pain (dolor) and increased temperature (calor), with or without erythema (rubor), and tenderness remain the prime features of hand

33) As vias de acesso preconizadas na abordagem para correção da contratura em flexão da interfalangiana proximal são

a) dorsal ou volar
b) dorsal ou medioaxial
c) volar ou medioaxial
d) volar ou longitudinal

Resposta C

referência Green página 400

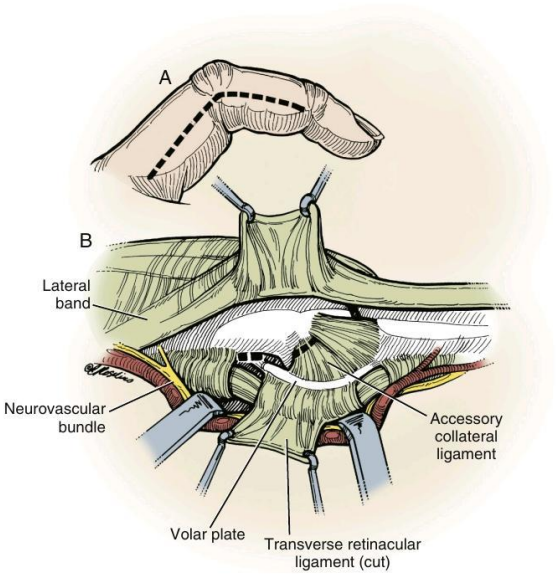

Fig. 10.17 **A,** Flexion contracture release at the proximal interphalangeal joint as depicted via a midlateral approach. **B,** The transverse retinacular ligament is divided and the lateral aspect of the joint is visualized. The volar plate checkrein ligaments are released, as well as the accessory collateral ligament at its origin on both the radial and ulnar aspects of the joint. If motion is not improved, the proper collateral ligament is also released. (Copyright © Elizabeth Martin.)

function of the extensor mechanism. If there is attenuation of or injury to the extensor, release of the volar contracture tissue alone will not restore active extension. Instead, a plan to release the joint, including the volar plate and collateral ligaments, and reconstruction of the extensor mechanism must be considered.[41,42] The MP joint should also be evaluated, and if hyperextension is present, consideration can be given to blocking the MP hyperextension, such as with relative motion flexion splinting, to allow the full extension force to be directed to PIP joint.[43]

Surgical approaches to the PIP joint have been well described in the literature. All use either the volar zigzag Bruner incision or a midaxial approach. The use of local anesthesia with or without intravenous sedation is preferred to allow the patient to actively flex and extend the joint after release of contractures. This enables immediate evaluation of the efficacy of the procedure, and the ability to perform any fine-tuning or additional releases if full extension is not achieved. If local anesthesia with sedation is not possible, an arm block or general anesthesia can be used, but in this case, passive extension can be evaluated while active extension cannot.

Volar surgical approach. A standard Bruner (or midlateral incision with transverse extensions) incision is made from the distal phalangeal crease to the palmar digital crease, and the skin flaps are elevated while care is taken not to devitalize the corner. The radial and ulnar neurovascular bundles are identified and protected (Fig. 10.17). The flexor tendon sheath is opened on a lateral hinge from the distal aspect of the A2 pulley to the proximal aspect of the A4 pulley, and the flexor tendons are carefully retracted. While it may not be possible, one should make an attempt to preserve the vincula if feasible. The checkrein ligaments are identified (Fig. 10.18).[9] An anatomic landmark for identifying the checkrein ligaments is the transverse digital artery, which passes underneath the checkrein ligament 3 mm proximal to the joint. The checkrein ligaments are released while the transverse digital arteries are spared. An attempt at passive extension of the joint is then made. If full passive extension is not achieved, a capsular release is performed to release the volar plate complex from the proximal phalanx and accessory collateral ligaments from the volar plate. If the contracture still persists, the rest of the collateral ligament is detached from the proximal phalanx. Alternatively, Diao and Eaton described total excision of the collateral ligaments through radial and ulnar midlateral incisions.[44] The need for an extensor tenolysis cannot be predicted in the presence of a flexion contracture. Thus active extension always needs to be checked after flexion contracture release, and the patient must be advised preoperatively of the possible need for extensor tenolysis.

Careful attention to hemostasis is essential as any hematoma will encourage the formation of a new contracture, and the swelling will impair postoperative rehabilitation. The vascularity of the digit must be carefully monitored during closure and postoperative positioning because overstretching of neurovascular tissues may result in spasm and an ischemic digit.[4] The finger should be splinted in the maximum safe extension position for 3 to 5 days. Kirschner wire fixation of the joint in extension is occasionally used to maintain the release while the soft tissues accommodate to the new position. If there is excessive pressure to maintain extension on the joint, placement of a Kirschner wire can result in cartilage necrosis or cartilage overgrowth on the distal end of the proximal phalanx.[45-47]

After the dressings are removed, a light dressing is applied, and active motion exercises are begun. Dynamic and static resting orthotics are fabricated and used for 3 to 4 months or until the correction plateaus.

34) Nas fraturas do rádio distal, o sinal da lágrima (“teardrop”) representa a:

a) projeção da margem distal volar da faceta do escafóide do rádio distal
b) projeção da margem distal do estilóide radial
c) projeção da margem volar da faceta do semilunar do rádio distal
d) projeção da margem volar do semilunar no carpo

Resposta C

referência Green página 604

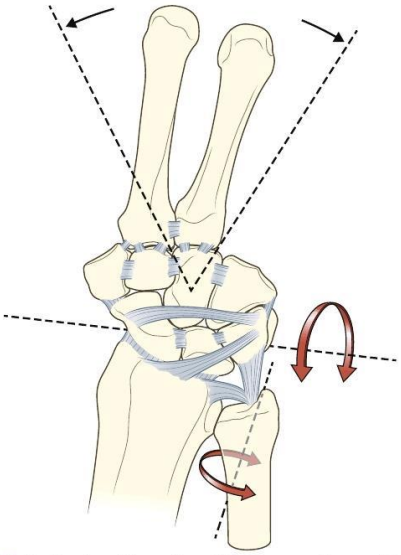

Fig. 15.3 The hand and the radius rotate as one unit around the ulna. The primary stability is provided by the shape of the distal radioulnar joint surfaces and the stabilizing ulnoradial and ulnocarpal ligaments. (Redrawn from Hagert CG: Current concepts of the functional anatomy of the distal radioulnar joint, including the ulnocarpal junction. In Büchler U [ed]: *Wrist Instability*. London, Federation of European Societies for Surgery of the Hand, Martin Dunitz, 1996: 15–21.)

the largest range of motion and the SLiL is prone to injury. The interosseous ligaments in the distal carpal bone row, in contrast, are taut and stable, allowing only limited mobility. The proximal carpal bone row moves as a unit; 50% of the wrist mobility in flexion/extension occurs in the joint between the radius and the proximal carpal bones (radiocarpal joint) and 50% between the carpal bones. Ulnar and radial deviation of the wrist is accompanied by translation/rotation of the lunate and the distal row, combined with flexion/extension of the scaphoid. Forearm rotation takes place mainly in the DRUJ but also to some extent in the carpal bones. There are no tendons or muscles attaching to the carpal bones, and thus the joint motion is controlled by the skeletal geometry and the stabilizing ligaments and only indirectly by the muscles.

From the radius and ulna, strong extrinsic ligaments run longitudinally into the wrist joint capsule (see Fig. 15.5B and C), partly securing stability of the carpal bone rows to each other and partly securing the carpal bones to the forearm bones. Dorsally, the ligaments are organized in a V shape, converging toward the dorsal side of the triquetrum. Volarly, the ligaments also extend in a V shape but converge toward the waist of the capitate, which forms the center of rotation for radial and ulnar deviation.

If stability is provided by the ligaments, wrist motion is mainly controlled by the forearm muscles. The radial nerve innervates virtually all extensor muscles, while the median nerve and the ulnar nerve control the flexor muscles. The ulnar nerve innervates the flexor carpi ulnaris, the strongest of the wrist flexors, and the median nerve the pronator quadratus, the main dynamic stabilizer of the DRUJ.

RADIOGRAPHIC PATHOANATOMY

Three radiographic measures are used to describe the changed position of the distal articular surface of the fractured radius, the dorsal/volar compression (tilt), the radial compression (radial inclination), and the axial compression (ulnar variance) (Fig. 15.6). The dorsal/volar tilt is measured by the angle created by a line drawn between the dorsal and palmar lips of the lunate facet and the longitudinal axis of the radius. This angle is best seen on a *facet lateral* radiograph, performed with the beam inclined approximately 10 to 30 degrees distal-to-proximal to profile the articular surface of the lunate facet and eliminate the bony overlap of the radial styloid (Fig. 15.7). The radial inclination is average 23 degrees and measured by the angle formed by a line drawn tangential to the distal radial articular surface on a posteroanterior (PA) radiograph and one perpendicular to the shaft of the radius. Ulnar variance averages just under 1 mm negative[3] but ranges widely, and a comparison to the nonfractured contralateral side is often helpful. The variance is the axial difference between the subchondral bone of the midpoint between the volar and dorsal rim (central reference point) of the lunate facet at the distal margin of the sigmoid notch and the most distal articular surface of the ulna, which is measured along the forearm's longitudinal axis.

The identification of the radiographic landmarks is essential, particularly in intraarticular fractures. The classic landmark of the distal radius is the “teardrop,”[3] which represents the volar projection of the *lunate facet* of the distal radius (Fig. 15.8). The lunate facet constitutes an important mechanical buttress preventing subluxation of the lunate and is together, with the short radiolunate ligament, important for the stability in comminuted fractures. In radiographs, the teardrop is identified by the rounded contour of the metaphysis toward the distal 3 to 4 mms, forming the drop-like appearance. In contrast, the distal part of the radius forming the scaphoid facet is flatter. During surgery, the two surfaces are easily identified, and when gently rotating the radius in the lateral view, a double contour with the two volar cortices, the rounded and the flat can be visualized.

The teardrop angle may be useful, both preoperatively and during surgery, and represents a line drawn tangential to the subchondral bone of the articular surface through the tip of the teardrop (Fig. 15.9). The teardrop normally forms an angle of 70 degrees with the longitudinal axis of the radius.[3] Even a subtle dorsal rotation of an extraarticular fractured radius alters this relationship and decreases the teardrop angle. Similarly, an impaction injury that splits the lunate facet may drive the lunate into the metaphysis of the radius and rotate the teardrop. The teardrop is narrow and measures just 5 mm at its greatest width, which together with the rounded shape sometimes makes stable fixation difficult with traditional volar implants.[4]

Another useful facet measurement on the lateral film is the anteroposterior (AP) distance, measured between the distal dorsal and volar rims of the lunate facet (Fig. 15.10). The average AP distance is 18 to 20 mm, but if possible, the AP distance on the injured side is compared with that on the uninjured side. A widening raises suspicion of a split of the radius fossa in the coronal plane, which can be difficult to appreciate in the lateral view without computed tomography (CT). Therefore in addition, the position of the lunate relative the lunate fossa can be examined (Fig. 15.11). In a normal wrist, the curvature of the lunate facet of the radius and the curvature of the lunate bone in the lateral projection are virtually concentric. In an uninjured wrist, the AP distance is essentially equal to the diameter of a circle that represents the best fit to the proximal articular surface of the lunate. Nonconcentric articular contours or an altered AP–lunate diameter ratio suggests a

35) O tratamento preconizado para a pseudo-recorrência pós ressecção de cistos sinoviais via artroscópica é

a) massagem digital
b) infiltração com corticoide
c) Imobilização por 03 semanas
d) abordagem via aberta

Resposta A

referência Green página 773

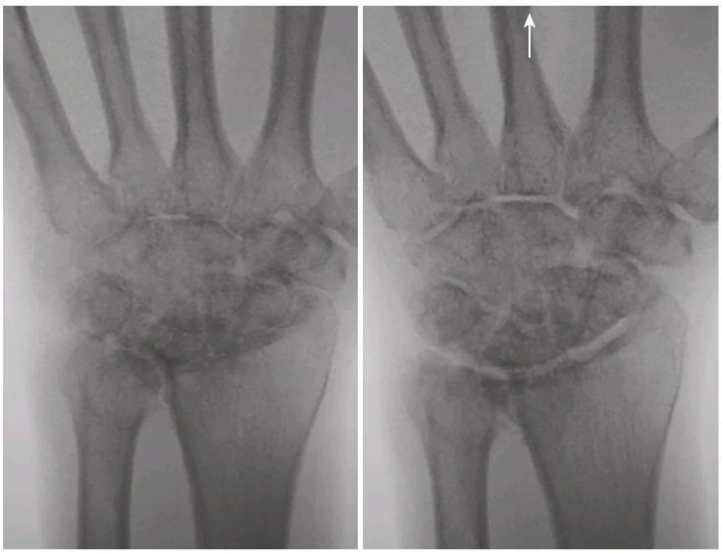

Fig. 17.8 Feasibility for arthroscopic synovectomy can be predicted by performing traction test under fluoroscopic guide preoperatively to assess the joint distractibility.

ganglia will rupture after 1 to 3 minutes of shaving. After successful decompression of the ganglion, further resection of the capsular junction is performed under arthroscopic vision. To ensure resection of the potential one-way valve structure at the stalk, a sizable capsular resection of 5 to 10 mm in diameter should be made in the dorsal capsule. At this juncture of shaving, care is taken to avoid damaging important structures like the intracapsular dorsal wrist ligaments and extensor tendons. All wounds are then closed with Steri-Strips only. No suture is required. Bulky dressing and bandaging is applied for 1 to 2 days to reduce swelling and then light dressing is followed to allow full mobilization of the wrist and fingers. The patient is encouraged to perform self-massaging of the original ganglion site for 3 weeks to prevent pseudorecurrence formation due to regurgitation of joint fluid into the empty cyst remnant before the abolished valve is completely healed (Fig. 17.12).

Volar Wrist Ganglion

Indications. The best indication is sessile type of volar wrist ganglion arising from the radiocarpal joint and centered on the proximal wrist crease. Mobile ganglia with long pedicle are poor candidates for arthroscopic surgery. Preoperative ultrasound scanning helps to confirm the articular origin and nature of the cystic mass. Arthroscopic drainage of a ganglion from the STT joint is feasible with the addition of new portals as described later.

AUTHOR'S PREFERRED METHOD OF TREATMENT: ARTHROSCOPIC VOLAR WRIST GANGLIONOTOMY

For arthroscopic treatment of the volar wrist ganglion arising from radiocarpal joint, we first described the technique and arthroscopic pathoanatomy in 2003.[99] Technically it is much easier and more straightforward than performing a dorsal ganglionotomy. The author prefers to perform the operation under PSLA without the use of a tourniquet as this can help monitor any possible iatrogenic damage to the radial artery and its branches during the surgery.

A wrist arthrogram can be performed immediately prior to the arthroscopic intervention or as a separate investigative procedure. The use of an intraoperative arthrogram can facilitate the confirmation and identification of the stalk of a ganglion as arising from the radiocarpal joint. Absence of demonstrable contrast filling the stalk with communication from the radiocarpal joint may preclude the use of the technique. With the patient lying supine and with the arm supported by hand table, 3 to 5 cc of nonionic contrast solution is admixed with 2% lidocaine and injected into the radiocarpal joint at the 3-4 portal site under fluoroscopic guidance. Typically, the stalk of the ganglion, and occasionally the cyst itself, can be identified at one of the volar radiocarpal ligament intervals (Fig. 17.13). Ganglia arising from the interval between the RSC and the LRL ligament will show up at the more lateral aspect of the distal radius, while those arising from the interval between the LRL and SRL ligaments will show up at a more central position of the distal radius. The relative position of the contrast-filling stalk can aid the identification of the true stalk during the actual arthroscopic procedure and hence facilitate subsequent decompression. As a rule, ganglia arising from the midcarpal joint or STT joint will not be revealed by arthrogram of the radiocarpal joint, unless one of the interosseous ligaments at the proximal carpal row is ruptured and creates a free communication between the radiocarpal and the midcarpal joint.

Standard radiocarpal joint arthroscopy is performed. For a right-handed surgeon operating on the right wrist, the scope entry site is typically 1-2, and working portal is 3-4, thus the name "1234" technique that we coined. For the left wrist, the sites are reversed. The outflow portal is 6U. Routine diagnostic arthroscopic examination of the radiocarpal joint is performed, followed by localization of the ganglion. Synovial and

36) Na neurotização das lesões crônicas do nervo radial utilizamos os ramos

a) motores do flexor superficial dos dedos para extensor radial curto do carpo e flexor radial do carpo para Interósseo posterior
b) motores do flexor profundo dos dedos para extensor radial longo do carpo e flexor radial do carpo para interósseo posterior
c) motores do flexor superficial dos dedos para extensor radial curto do carpo e flexor ulnar do carpo para interósseo anterior
d) motores do pronador redondo para extensor radial curto do carpo e Interósseo anterior para interósseo posterior

Resposta A

referência Green página 1172

transfers are effective for restoring function for these injuries; however, nerve transfers have the potential to restore individual native muscle function, which includes independent finger extension.[188,194] The obvious disadvantage of nerve transfers is the time required for nerve regeneration and muscle reinnervation. Evidence of reinnervation after radial nerve transfers is usually observed by 9 months, and continued motor reeducation and strengthening are required thereafter to maximize functional recovery.

Median to radial nerve transfers. Conceptualized in a way that capitalizes on tenodesis and synergism, the standard transfers to address functional loss in radial nerve palsy include coaptation of the flexor digitorum superficialis (FDS) motor nerve to the extensor carpi radialis brevis (ECRB) motor nerve to restore wrist extension, and the flexor carpi radialis (FCR) motor branch to the PIN to restore finger and thumb extension. Sukegawa demonstrated in a cadaver model that these transfers have the necessary "swing distance" to easily reach the target nerve. Average axon counts for the FDS branch (885 axons) are similar to the average axon count for the ECRB (548 axons), though a large discrepancy exists between the FCR branch (1501 axons) and the PIN (5162 axons), suggesting that the observed clinical success may be related to collateral sprouting.[195]

The decision to proceed with median to radial nerve transfers is based on frank discussions with the patient and must include consideration of time to recovery, occupation, access to hand therapy, and injury pattern. The median and ulnar nerves must be intact to prevent finger or wrist dysfunction.

Outcomes. Many have reported success with the median to radial nerve transfers; however, reports are limited to small patient series. In 2011 Ray and Mackinnon reported on the largest series of 19 patients. Though 9 patients underwent simultaneous pronator teres (PT) to the side of ECRB tendon transfer, 18 recovered MRC grade 4 wrist extension strength. For finger and thumb extension, 12 recovered MRC grade 4 or better results, 2 had MRC grade 3 strength, and 5 had MRC grade 0 to 2 recovery.[194] Ukrit et al. reported MRC grade 4 wrist extension strength after FDS to ECRB nerve transfer.[196] Garcia-Lopez et al. transferred a branch of PT to extensor carpi radialis longus and FCR to PIN in 6 patients, and reported M3 or greater wrist extension, thumb extension, and finger extension at 20 months after surgery.[197] Bertelli, in a clever modification, flipped the distal anterior interosseous nerve (AIN) (after the flexor pollicis longus [FPL] motor branch) proximally to reach the ECRB motor branch and combined this with a more conventional FCR motor branch to the PIN transfer.[198] Out of 14 patients, all had functional wrist extension (13 with MRC, 4 and 1 with MRC 3) and 12 had functional finger extension (with 2 failures). Though every patient in a matched cohort of tendon transfer recipients achieved functional wrist and finger extension, average wrist extension was 35 degrees (versus 67 degrees in nerve transfer group) and finger extension frequently required a tenodesis effect of wrist flexion, which was not necessary in the successful nerve transfers.

Technique. A 15-cm curvilinear incision is made over the proximal radial forearm (Fig. 30.21A). The cephalic vein and, just medially, the accompanied lateral antebrachial cutaneous (LABC) nerve are identified and preserved. The muscle fascia is incised and the radial vessels and brachioradialis (BR) muscle are identified. The BR is elevated and the radial superficial sensory nerve (RSN) is identified. The superficial sensory nerve branch is followed proximally under the BR, and just dorsal/lateral to the RSN, branches to the ECRB are identified adjacent to the muscle belly. The ECRB usually has two branches, and the longer distal branch is encountered first. The dissection then continues proximally to identify the other branches of the radial nerve (the PIN and then supinator branches). The supinator branch often arises more posterior and lateral to the PIN (see Fig. 30.21B). During this dissection, "leash of Henry" vessels must be ligated and the

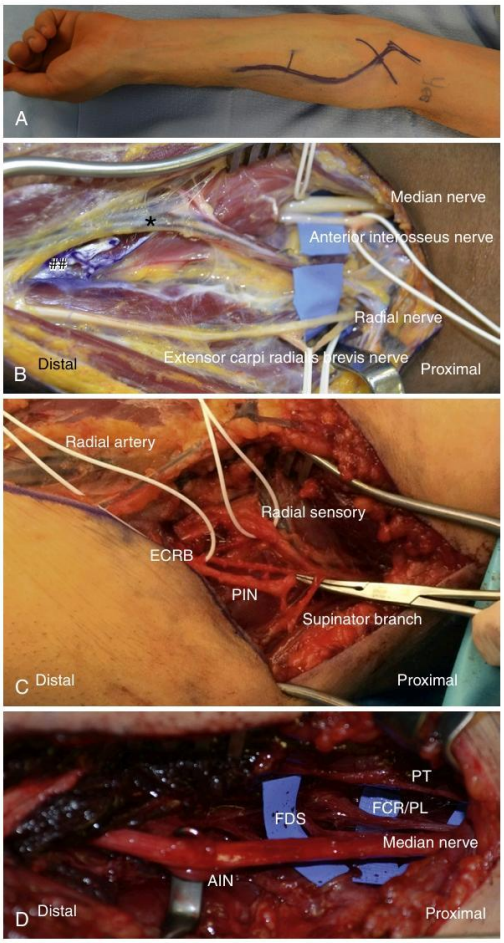

Fig. 30.21 Median to radial nerve transfers. **A,** A curvilinear incision is made over the proximal radial forearm that provides access to both the median and radial nerves. **B,** Exposure of the median and radial nerves of the left arm. The vessel loops are around the AIN and the nerve branches to the ECRB (*, radial artery; ##, pronator teres tenotomy). **C,** Branches of the radial nerve of the left arm. **D,** Branches of the median nerve of the left arm. The branches of the median nerve are dissected and labeled by their target muscle (*AIN,* Anterior interosseous nerve; *FCR/PL,* nerve to the flexor carpi radialis muscle/palmaris longus muscle; *FDS,* nerve to the flexor digitorum superficialis; *PIN,* posterior interosseous nerve; *PT,* nerve to the pronator teres muscle). (Courtesy Amy Moore, MD.)

tendon of the ECRB incised. A handheld nerve stimulator set at 2 mA is used to confirm complete denervation. This is an important last step before transecting these recipient nerves. Microdissection of the ECRB branches away from the parent nerve proximally will ensure as much length as possible to facilitate a tension-free coaptation.

Once the recipient nerves have been identified, the median nerve is exposed in the forearm. In the interval between the radial vessels

37) Nos pacientes com espasticidade do membro superior é comum observamos a deformidade de

a) rotação externa do ombro
b) extensão do cotovelo
c) pronação do antebraço
d) extensão do punho

Resposta C

referência Green página 1250

portion of the nerve is preferred. Partial neurectomy of approximately 50% to 80% of the nerve innervating the muscle is necessary to prevent recurrence via reinnervation from sprouting of adjacent motor units.[66] The neurectomy can be performed anywhere along the nerve (main trunk, main motor nerve, primary branching of main motor nerve, or secondary branches of motor nerve). A nerve stimulator is necessary to isolate the motor branches and to preserve sensory branches.

CRITICAL POINTS

Elbow Muscle Release and Lengthening for Dynamic Spasticity or Fixed Flexion Contracture

Indications

- Dynamic elbow spasticity that has not been responsive to therapy
- Fixed flexion contracture greater than 40 degrees that interferes with function or hygiene

Preoperative Evaluation

- Individualize patient goals.
- Perform repeated clinical examinations.
- Maximize nonoperative modalities and consider botulinum toxin to predict surgical outcomes.

Pearls

- Apply a sterile circular tourniquet (HemaClear, OHK Medical Devices, Grandville, MI) that exsanguinates during application and allows complete access to the elbow.
- Always identify and protect the neurovascular structures early in the procedure. The radial nerve and lateral antebrachial cutaneous nerves may be displaced by the spastic muscles and/or contracture.

Technical Points

- Make a transverse antecubital incision for dynamic spasticity and a Z-plasty incision for a fixed deformity.
- Identify the lateral antebrachial cutaneous (lateral to the biceps tendon) and radial nerves (between the brachioradialis and brachialis muscles).
- Minimal biceps lengthening can be performed via fractional technique (short musculotendinous junction); however, more extensive lengthening requires Z-lengthening of the tendon.
- Mobilize the neurovascular bundle from the anterior surface of the brachialis prior to brachialis fractional lengthening.
- Brachialis fractional lengthening and brachioradialis myotomy.

Pitfalls

- Avoid joint capsular release in long-standing contractures.
- Failure to identify the neurovascular structures can lead to iatrogenic injury.
- Inadequate hemostasis can lead to postoperative hematoma.

Postoperative Care

- Cast application is preferred to allow for wound and tendon healing.
- Cast removal in a month is followed by active and passive range-of-motion exercises.

AUTHORS' PREFERRED METHOD OF TREATMENT: ELBOW RECONSTRUCTION

The initial treatment for dynamic spastic elbow flexion posturing without contracture is therapy with or without botulinum toxin injection. Recalcitrant or recurrent elbow flexion spasticity is treated by surgery. The elbow is approached via a transverse antecubital incision. The brachioradialis is released by myotomy and the deeper brachialis is fractional lengthened. In severe contractures, therapy is ineffective and surgery is the only treatment option. The elbow is approached via a longitudinal incision lengthened with a Z-plasty to overcome the skin deficiency. The brachioradialis is released by myotomy, the biceps is lengthened by Z-plasty, and the brachialis undergoes fractional lengthening.

Forearm Reconstruction

Forearm pronation deformity is common in patients with hemiparesis, which can impede supinations activities (feeding, carrying a tray, obtaining soap from a dispenser, catching a ball, and wiping during toileting). However, the surgeon must avoid losing pronation in nondominant hands as tabletop activities predominate modern day culture (typing, cutting food, holding papers, and turning pages in a book). The deformity is primarily due to spasticity of contracture in the pronator teres, impeding forearm supination. The pronator quadratus can also be spastic and the biceps/supinator can be weak, worsening the deformity.

Pronator teres release is the most common surgical treatment for dynamic pronation deformity.[69] Surgery is performed via a radial incision along the midportion of the radius (Fig. 32.6). The radial sensory nerve is identified emanating from beneath the brachioradialis. Just proximal to this exit point and beneath the brachioradialis, the pronator tendon is identified and released from the radius.[70] A long-arm cast in supination is applied for 4 weeks. The elbow, wrist, and hand position depends on the concomitant procedures performed. Following cast removal, therapy is instituted and the arm is mobilized. A nighttime splint is worn for at least 3 months.

Several tendon transfers have been described to provide supination of the forearm.[71,72] Pronator teres rerouting around the radius is the most common tendon transfer used to provide supination.[73-75] However, if one transfers a spastic pronator teres, this can lead to a subsequent supination deformity.[76] Therefore, we favor simple release of the pronator teres without tendon transfer, avoiding the spastic pronator rotating the forearm into a secondary supination deformity.

In limbs with severe excessive pronation, simple release of the pronator teres will not resolve the underlying contracture. This position can also lead to radial head dislocation.[77,78] Treatment options include radial head resection if the radial head becomes painful. Other bone procedures would include osteotomy of the radius and/or ulna[79] or making a one-bone forearm with transposition of the distal radius onto the proximal ulna.

AUTHORS' PREFERRED METHOD OF TREATMENT: FOREARM RECONSTRUCTION

We favor simple release of the pronator teres for a forearm pronation deformity. We avoid pronator rerouting as the spastic pronator can rotate the forearm into a supination deformity. Severe deformities are best managed with osteotomy of the radius and ulna, preferable creating a one-bone forearm with transposition of the distal radius onto the proximal ulna.

Wrist Reconstruction

The spastic wrist typically lacks active extension, which is the fundamental motion for finger tenodesis and grip strength (see hierarchy of

38) A maioria das malformações embrionárias dos membros superiores ocorre durante a gestação entre a

a) 1 e 4 semana
b) 4 e 8 semana
c) 8 e 12 semana
d) 12 e 16 semana

Resposta B

referência Green página 1363

35

Embryology of the Upper Extremity

Scott H. Kozin

Congenital anomalies affect 1% to 3% of newborns, and approximately 10% of these children have upper extremity abnormalities.[1,2] The incidence of congenital anomalies has not changed appreciably over the last decade. Congenital limb anomalies are second only to congenital heart disease in the incidence of birth malformations.[3] Most anomalies occur spontaneously or are inherited.[4] Few malformations are attributed to teratogens.[5-7] Limb anomalies can be produced in animal models; this has increased our knowledge of and insight into limb development.[8]

Recent advancements in understanding limb anomalies are directly related to our increased understanding of embryogenesis. Knowledge of hominoid limb development has been greatly expanded by the experimental embryologists. Animal models with limb patterning similar to that of humans have been used to dissect and manipulate crucial signaling centers that affect limb development and orientation.[9-11] Research on gene misexpression and loss of function has enhanced our understanding of limb formation.[3,9] There is intense work focusing on genotype-phenotype correlations that may have substantial clinical implications. The hand surgeon is uniquely positioned between clinical care and genetic research. He or she must possess a basic comprehension of embryogenesis and limb formation to comprehend congenital limb anomalies and to communicate relevant knowledge to the family of an affected child. Parents may initially bear a tremendous amount of guilt, and the role of disseminating reliable information is the responsibility of the physician caring for the family.

EMBRYOGENESIS

Limb development begins during embryogenesis with events that affect the position and orientation of each limb and the number of limbs that appear (Table 35.1).[12] The limb bud is first visualized at 26 days after fertilization when the embryo is about 4 mm in length (crown-rump length), or about the size of a piece of rice.[13,14] The bud rapidly develops through 47 days of life until the embryo is close to 20 mm in length, or the size of a lima bean. Fifty-two to 53 days after gestation, the embryo is 22 to 24 mm long and the fingers are entirely separate.[15] Eight weeks after fertilization, embryogenesis is complete and all limb structures are present.[3,10,11] At this point, the joints form as condensation of the chondrogen creates dense plates between future bones.[16] Joint cavitation further forms the articulation, although proper joint development requires motion for modeling of the ultimate joint surface. Most upper extremity congenital anomalies occur during this 4- to 8-week period of rapid and fragile limb development. After 8 weeks' gestation, the fetal period commences, with differentiation, maturation, and enlargement of existing structures.

The limb bud represents an outgrowth of the mesoderm into the overlying ectoderm. Two sources of cells migrate from their origins into the limb bud.[3,16] The cells from the lateral plate mesoderm become bone, cartilage, and tendon. The cells from the somatic mesoderm form the muscular, nervous, and vascular elements of the limb bud (Fig. 35.1).

In order to comprehend limb development and to explain it to families, the physician must appreciate the signaling centers that control the three spatial axes of limb development: proximodistal, anteroposterior, and dorsoventral.[16] Each of these limb growth axes contains a signaling center (i.e., a group of cells) that is responsible for establishing the corresponding axes; they are the apical ectodermal ridge (AER), the zone of polarizing activity (ZPA), and the Wingless type (Wnt) signaling centers (Table 35.2).[3,10,11] A coordinated effort between the AER, ZPA, and Wnt pathways is necessary for proper limb patterning and axes development.[16-18] The three signaling centers are interdependent so that the loss of one signal results in compromise of the entire system.[19] There is considerable cross talk between these signaling pathways during limb development.

Programmed cell death plays an important part in limb development. Programmed cell death is an active process that is genetically controlled to eliminate unwanted cells during embryogenesis.[20] Apoptotic cells undergo a degeneration process with DNA fragmentation and are eventually engulfed by phagocytic cells. Genetic control of cell death is necessary during limb bud formation. For example, the digits initially develop as webbed fingers. Extraneous tissue between fingers must undergo apoptosis and interdigital necrosis for finger separation. Failure of interdigital apoptosis results in syndactyly.[21] Interestingly, bone morphogenetic proteins (BMPs), widely recognized for their role in chondrogenesis and osteogenesis, trigger apoptotic pathways of the interdigital mesenchyme to produce separated fingers.[20] BMP antagonist can block BMP signaling and prevent apoptosis and interdigital necrosis. For example, bats have web limbs, and BMP is blocked during their limb embryogenesis.[22] Similarly, altered signaling of fibroblast growth factors, such as occurs in Apert syndrome, can negate BMP-mediated apoptosis, resulting in syndactyly (Fig. 35.2). Apert syndrome is inherited in an autosomal dominant pattern and can be passed on to future generations (Fig. 35.3).

Spatial Axes of Limb Development and Their Signaling Centers

Proximodistal Limb Development

The limb develops in a proximal to distal direction, with the shoulder forming before the elbow and the elbow before the wrist (shoulder →

39) “Uma mão para comer e outra para se limpar” é um dos princípios do tratamento da

a) artrogripose
b) paralisia cerebral
c) tetraplegia
d) sinostose radio ulnar

Resposta A

referência Green página 1534

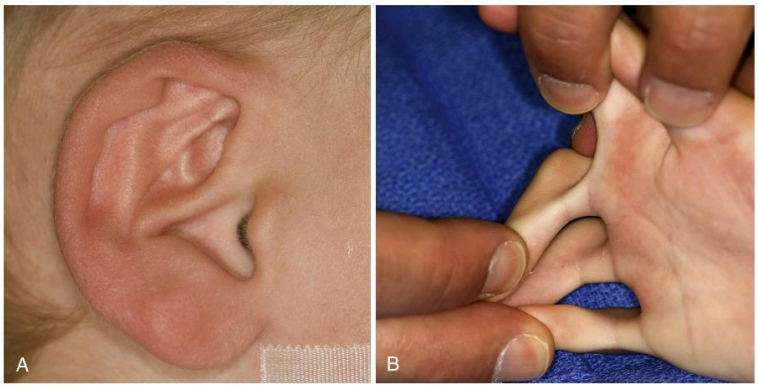

Fig. 39.3 Distal arthrogryposis type 9A (Beals syndrome). **A,** Characteristic crumpled appearance of the upper helix of the external ear. **B,** Contractural arachnodactyly and proximal interphalangeal joint contractures. (Courtesy of Shriners Hospitals for Children, Philadelphia, Pennsylvania.)

Fig. 39.4 Distal arthrogryposis type 8A (Escobar syndrome) with multiple pterygia. (Courtesy of Shriners Hospitals for Children, Philadelphia, Pennsylvania.)

PERTINENT ANATOMY

Arthrogryposis affects the entire musculoskeletal system. Children with arthrogryposis have absent or hypotrophic muscles but may retain the associated tendons and overlying fascia. As the child grows, these noncontractile tissues can tether the joints leading to joint contractures. The bones may be osteopenic because they do not have the normal load of muscle activity or weight bearing. Cortices in children with arthrogryposis tend to be quite thick, but the bones are small in diameter and the medullary canal is nearly absent. The motor and mixed nerves are also small in caliber compared with other unaffected children of the same size. With thin bones and a hypoplastic musculature, the subcutaneous fat encompasses a large percentage of the bulk of the arms.

Historical Review

A historical review of milestones in the treatment of AMC is detailed in Table 39.3.

SURGICAL PROCEDURES

The goal of any treatment plan for a child with arthrogryposis is to maximize function and independence. For the lower extremities, the goals are ambulation and sitting. Traditionally, ambulation has trumped all other treatment goals. In many centers, the lack of expertise and familiarity with upper limb surgery relegates upper limb function to an afterthought. This dismissal is a disservice to these children and to their caregivers. Basic upper limb function is equally as important to the well-being of these children as ambulation.

If the child does possess limbs and joints in optimal position for function by the first or second year of life, surgery should be performed to reorient and/or increase joint motion (Fig. 39.8). For nearly all children, shoulder rotation should be centered at 15 to 30 degrees of internal rotation. If this shoulder position is not present, the surgeon should consider a humeral rotational osteotomy. If elbow flexion is insufficient to reach the mouth, a release the posterior elbow should be performed. Elbows should be released within the first 2 years of life to provide maximal passive motion, with an optimal range between 30 degrees of extension and at least 100 degrees of flexion. For the minority of children that lack sufficient extension, soft tissue releases, osteotomies, and tendon transfers may be required.

For the upper extremity, the primary goals are to have “one hand to eat and one to wipe.” These goals can be achieved by the same hand. The rate-limiting step in optimizing the child’s independence is uniformly finger and thumb motion. Independent self-feeding requires at least some hand function. The child must be able to acquire the food, grip firmly enough to bring food to the mouth, and release the food by opening the digits. In addition, the wrist and the elbow combined must have enough extension to reach the plate or the table and sufficient flexion to allow the hand to reach the mouth. Forearm and shoulder rotation need to allow the hand to face the plate and then the mouth.

40) No retalho de Kite o suprimento arterial principal é dado pela artéria

a) radial volar do indicador
b) ulnar dorsal do indicador
c) radial dorsal do indicador
d) ulnar volar do indicador

Resposta C

referência Green página 1851

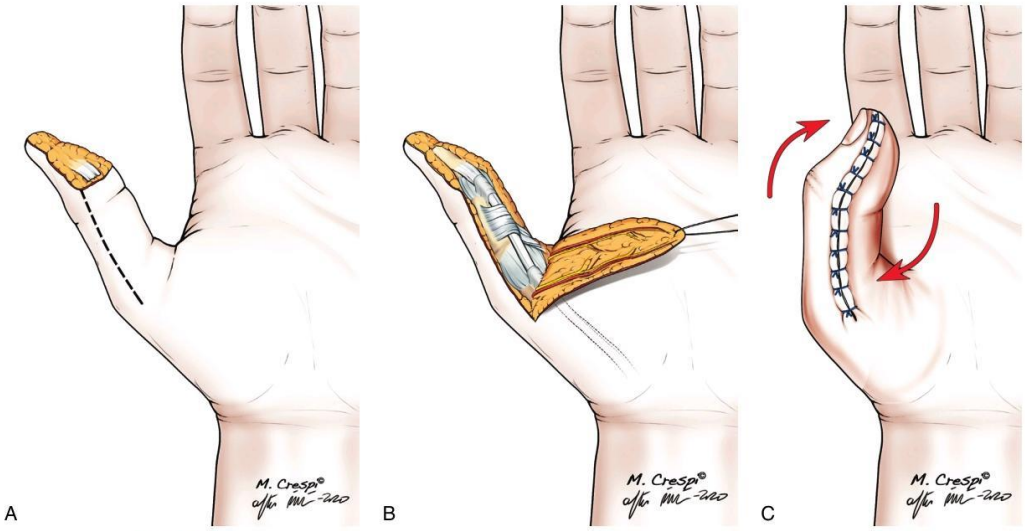

Fig. 48.3 **A** to **C,** The flap is raised through two midaxial incisions. Both neurovascular bundles are included in the flap. Some flexion contracture is permitted temporarily for closure. (Copyright © 2020, Dr. F. Piñal.)

Several variations of this flap have been presented, including an adipofascial extension to reduce donor site morbidity[17] and the possibility of carrying bone, probably in doubtful conditions.[18,19]

Irrespective of the fact that this flap represents a considerable advance in thumb coverage (Fig. 48.6), and it obviates the need for cross-finger flaps and all two-stage methods, it should, nevertheless, be used with caution. The surgeon should only raise the flap when the area of the cross anastomoses is intact, otherwise arterial failure will occur. Furthermore, the flap suffers from venous congestion if the skin over the pedicle is closed; skin-grafting is thus recommended.[13,17] In addition, because the skin at the site of the flap is elevated and is quite loose—nature provided it to permit thumb abduction—the surgeon may be tempted to close primarily excessively large donor sites. This will cause iatrogenic first web contracture and reduced MCP joint motion. Skin grafting is again recommended if large flaps are raised.[13,17]

A major drawback of this flap is the lack of sensory recovery, even when the dorsal branch of the radial nerve is connected to the ulnar digital nerve. For this reason, the flap is not recommended when there are defects involving more than 50% of the pulp. However, it may be indicated for larger defects in the elderly, where sensory recovery is frequently poor irrespective of the reconstructive option selected. For these reasons, this flap should probably only be utilized by those with experience in its application.

Dorsoradial homodigital flap. A similar flap based on the radial dorsal digital artery was described by Moschella and Cordova to solve radial and dorsal thumb defects.[14,20]

This flap's artery originates from the radial artery itself at the level of the anatomic snuffbox and passes deep to the extensor pollicis brevis tendon. It travels over the proximal phalanx at about 1 cm from the midline in the suprafascial plane. The rotation point of this flap is always the middle of the proximal phalanx. The reason for this is that it has a different arterial communicating pattern than the ulnar counterpart. Indeed, it constantly communicates with the palmar vasculature at the level of the middle third of the proximal phalanx (see Fig. 48.5), but the communication with the distal arcade is present in only about 20%.

Elevation. The skin island to be transferred is drawn on the axis of the artery. The flap can be quite large (up to 3 × 4 cm) and still achieve primary closure, as there is no risk of contracture.[20] As for the dorsoulnar flap, a sufficiently wide strip of subcutaneous tissue must be included in the pedicle. Likewise, visible larger veins should be preserved to secure adequate venous drainage of the flap.[21] Tight closure over the pedicle is to be avoided and skin grafts should be used freely. One recommendation is to add a cutaneous tail to facilitate direct skin closure after rotation of the flap.[21]

Although a branch of the radial nerve can be included and sutured, the originators did not recommend this flap for major pulp defects. Notwithstanding, the flap is a quick and safe solution for many lateral and dorsal defects of the thumb.

First dorsal metacarpal flap (kite flap). One of the most popularly employed procedures for thumb defects is the first dorsal metacarpal artery (FDMA) flap, also known as the "kite flap," described by Foucher and Braun in 1978.[22] This flap is an evolution of the innervated cross-finger flap described by Hilgenfeldt[13] and refined by Holevich.[23] The flap was devised for dorsal defects and as a vein carrier for thumb replantation. However, the fact that it can include a sensory branch from the radial nerve has made it useful for covering palmar defects, particularly in older people.[24]

The arterial supply of the flap is based on the radial dorsal artery of the index. This branch originates from the FDMA, which takes off from the radial artery between the crossing of the extensor pollicis longus and its penetration into the apex of the first interosseus space.

The radial dorsal artery of the index is constant[22] and travels on top of, or at times in, the aponeurosis of the first dorsal interosseous muscle. After providing a few branches, including one to the joint, the artery terminates supplying vascularity the dorsal skin of the proximal phalanx. There are a number of subcutaneous veins that can be

41) O ramo da artéria circunflexa femoral lateral responsável pela vascularização do retalho antero lateral da coxa é o

a) superficial
b) profundo
c) descendente
d) transverso

Resposta C

referência Green página 1777

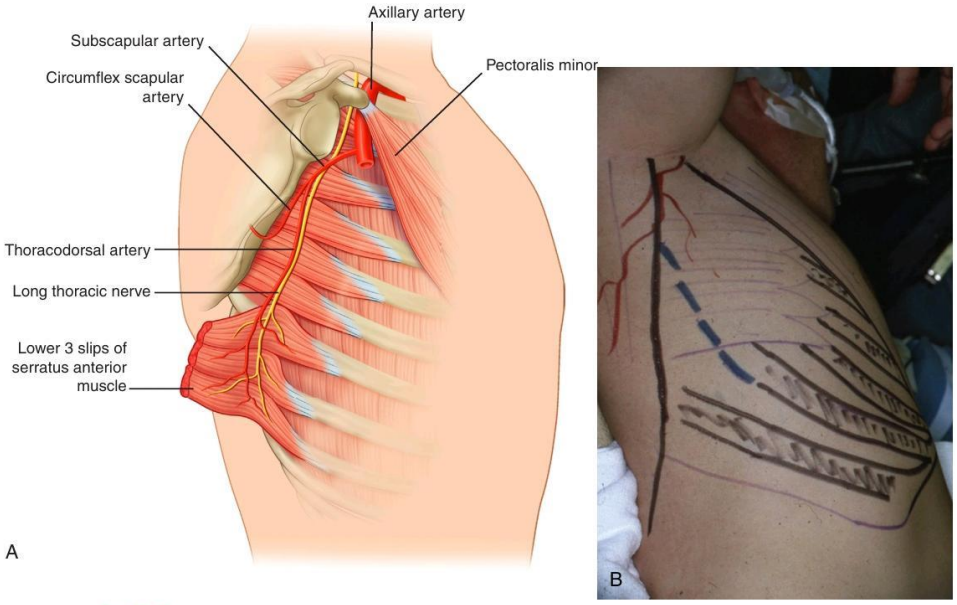

Fig. 45.25 Serratus anterior muscle flap. **A,** The arterial and neural anatomy of a serratus anterior free muscle flap. The descending serratus branch from the thoracodorsal artery passes downward along the anterior surface of the muscle to supply the lower three slips of the muscle. **B,** Preoperative marking of the midaxillary incision used to harvest a right serratus anterior free muscle flap.

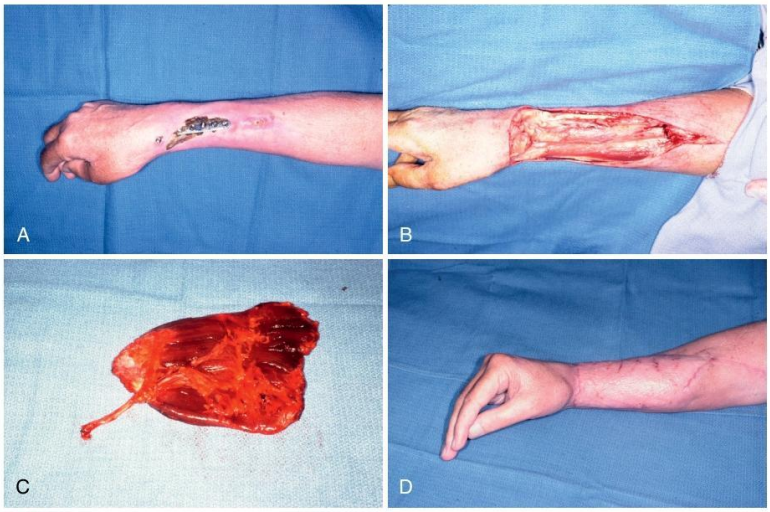

Fig. 45.26 Serratus anterior muscle flap. **A,** This man developed osteoradionecrosis of a distal radius allograft and exposed plate fixation used for reconstruction after radical resection of a malignant fibrous histiocytoma of the distal radius. **B,** He underwent resection of the involved soft tissues, removal of the allograft and ulna-carpal arthrodesis. **C,** This small serratus muscle flap can be isolated on a very long vascular pedicle by dividing the thoracodorsal artery and vein distal to the origin of the serratus branch and mobilizing the thoracodorsal artery and vein all the way proximally up to their origin from the subscapular artery and vein. **D,** The serratus muscle flap was used to obliterate the dead space and covered with a meshed split-thickness skin graft.

42) O nervo ulnar é derivado das raízes de C8 a T1, e é um ramo terminal do cordão medial. Na parte superior do braço, o nervo ulnar é

a) póstero medial a artéria braquial, posterior ao septo intermuscular e anterior a cabeça medial do tríceps
b) anteromedial a artéria braquial, posterior ao septo intermuscular e posterior a cabeça medial do tríceps
c) póstero medial a artéria braquial, posterior ao septo intermuscular e posterior a cabeça medial do tríceps
d) anteromedial a artéria braquial, anterior ao septo intermuscular e anterior a cabeça medial do tríceps

Resposta A

referência Green página 1105

Cubital Tunnel Syndrome

Chronic compression of the ulnar nerve at the cubital tunnel may occur as a result of ischemia or mechanical compression by repeated elbow flexion, posttraumatic scarring, anomalous musculature, or direct compression, although the exact cause may be difficult to identify. Acute trauma to the ulnar nerve from periarticular elbow fractures or subsequent surgery may compromise ulnar nerve function. Ulnar nerve subluxation may also contribute to cubital tunnel syndrome.[117] The area within the cubital tunnel is decreased with elbow flexion, and this can increase pressure on the cubital tunnel. Apefelberg and Larson reported a 55% decrease in cubital tunnel area with elbow flexion.[118] Pechan and Julis reported increased pressure within the cubital tunnel with elbow flexion, and this pressure was further compromised with wrist extension or shoulder abduction (or with both).[28] Gelberman and colleagues reported increased intraneural ulnar nerve pressure and decreased cubital tunnel volume with elbow flexion.[9]

Compression of the ulnar nerve at the cubital tunnel is extremely common and is the second most common peripheral compressive neuropathy after carpal tunnel syndrome. The diagnosis of cubital tunnel syndrome is based on patient symptoms, physical examination, and electrodiagnostic studies. Complaints typically include paresthesia and numbness in the small and ring fingers with aching in the medial aspect of the elbow and forearm. The Tinel sign is usually positive over the nerve at or proximal to the cubital tunnel, but the test is overly sensitive and often bilaterally positive. Provocative testing for cubital tunnel syndrome consisting of combined elbow flexion with digital pressure placed on the ulnar nerve proximal to the cubital tunnel has good sensitivity and specificity.[57] With severe ulnar nerve compression, patients may exhibit atrophy of the ulnar nerve–innervated intrinsic muscles with positive Froment and Wartenberg signs and clawing of the small and ring fingers if the innervation of the extrinsic flexors is less affected than the intrinsic muscles. Many patients are initially seen in the early stages of nerve compression and will have no obvious motor deficit. Careful sensory testing as outlined previously can help quantify changes in sensibility. In the early stages of nerve compression, provocation testing may be the only positive sign, followed by alteration of threshold testing (Semmes-Weinstein monofilaments). In the later stages, two-point discrimination will become abnormal.[57,119] McGowan described a classification system for ulnar neuropathy at the elbow that is based predominantly on the loss of ulnar nerve motor function and does not include sensory changes.[115] This classification system is widely quoted in the literature, although it is limited in clinical applicability. In the McGowan classification, grade I neuropathies have no muscle weakness, grade II neuropathies have muscle weakness with no atrophy, and grade III neuropathies have muscle atrophy.

Although clinical diagnosis of cubital tunnel syndrome remains the gold standard, electrodiagnostic studies may be used to confirm the diagnosis. Nerve conduction studies and EMG are useful in localizing the level of nerve compression, in addition to helping to identify other sites of nerve compression or other disease processes that may be present (i.e., upper motor neuron disease, peripheral neuropathy). Conduction velocity will help localize the site of compression and is a reflection on the degree of demyelination. Amplitude (SNAPs and CMAPs) provides information regarding the number of functional axons present. If the CMAP is severely reduced, conduction velocity across the elbow is not reliable in localizing the site of compression, and patient history and clinical examination will be required to localize the problem to the elbow. Reduced CMAPs in the first dorsal interosseous have been shown to be predictive of preoperative weakness in grip and key pinch strength and is a reflection of severity of disease.[120] Abnormal nerve conduction studies in patients with cubital tunnel syndrome include a conduction velocity of <50 m/sec across the elbow, a slowing of >10 m/sec between the above and below elbow segments, 10 m/sec difference in conduction velocity compared with the contralateral side, and a 20% reduction in amplitude compared with the contralateral side. Demyelination at the elbow can progress to cause a conduction block that will impair function. A conduction block is determined by a CMAP potential at the elbow that is 50% less than that at the wrist. Results of EMG and nerve conduction testing can be useful in preoperative counseling of patient with cubital tunnel syndrome. Patients with a decrease in conduction velocity across the elbow and normal CMAP amplitudes have a demyelinating injury and can anticipate fast and favorable recovery after surgery. Similarly, patients with intrinsic weakness and disuse atrophy due to a conduction block should anticipate motor recovery 2 to 3 months after successful surgery at the elbow. Those patients with a decrease in conduction velocity across the elbow and a decrease in CMAP amplitudes have an axonal injury, and their recovery will be slow, may be incomplete, and will depend on both the number of remaining functional axonal units and the status of the motor endplates.

Additional findings on EMG provide information regarding axonal loss. The presence of spontaneous activity (fibrillations/positive sharp waves) indicates acute axonal loss and that motor endplates are still receptive to receive new axons. Motor unit potential can be normal, acute (collateral sprouting, nascent), or chronic. This information is helpful when considering distal nerve transfers to augment functional recovery in patients with severe cubital tunnel syndrome. Anterior interosseous to ulnar motor nerve transfer may be considered in patients with severe cubital tunnel syndrome (decreased CMAP amplitude) and evidence of spontaneous activity in the ulnar intrinsic muscles (fibrillations and positive sharp waves) indicating acute denervation and the potential for recovery.[121]

Unlike carpal tunnel syndrome, there are other serious diagnoses that can mimic cubital tunnel syndrome, such as motor neuron disease or Guillain-Barré syndrome. The surgeon must be alert for the common problem of cervical disk disease and the rare but devastating problem of amyotrophic lateral sclerosis when evaluating patients with ulnar motor complaints, particularly if the motor findings exceed the sensory findings (severe motor loss with minimal sensory changes).

ANATOMY

The ulnar nerve is derived from the C8 and T1 nerve roots and is a terminal branch of the medial cord. In the upper part of the arm, the ulnar nerve is posteromedial to the brachial artery, posterior to the intermuscular septum, and anterior to the medial head of the triceps muscle (Fig. 28.17). The intermuscular septum is continuous from the humeral medial epicondyle to the coracobrachialis muscle. The arcade of Struthers is a tendinous band that attaches to the intermuscular septum and runs obliquely below the ulnar nerve to the triceps muscle (Fig. 28.18). The brachial fascia above combines to make this a significant compression point in some patients. The medial antebrachial cutaneous nerve (MABC) has two branches on either side of the basilic vein. The posterior MABC passes posterior to the ulnar nerve at or proximal to the epicondyle in 90% of cases.[122] This proximal branch of the MABC often runs with the medial intramuscular septum.[123] The anterior MABC crosses the ulnar nerve 3.5 cm distal to the medial epicondyle. The ulnar nerve passes posterior to the medial epicondyle and medial to the olecranon. The ulnar nerve then enters the cubital tunnel, which is defined by a taut fascial layer extending from the flexor carpi ulnaris muscle and the ligament of Osborne. After passing through the cubital tunnel, the ulnar nerve travels deep into the forearm between the ulnar and humeral heads of the flexor carpi ulnaris muscle.

43) A fratura da cabeça do metacarpo é mais comum no dedo

a) indicador
b) médio
c) anular
d) mínimo

Resposta A

referência Green página 260

7

Fractures of the Metacarpals and Phalanges

R. Glenn Gaston

Acknowledgments: I would like to acknowledge the recent work of Dr. Charles Day and the numerous previous editions by Dr. Peter Stern. Their brilliantly written chapters on this topic have been combined, modified, and updated to create this work.

Fractures of the metacarpals and phalanges are the most common fractures of the upper extremity.[1,2] In a series of 11,000 fractures, Emmett and Breck noted that these fractures accounted for 10% of the total.[3] Hove,[4] in a consecutive series of 1000 carpal, metacarpal, and phalangeal fractures, found that 82% involved the metacarpals or phalanges. The outer rays of the hand (thumb and small finger) are the most frequently injured digits; however, the most commonly fractured bone in the hand is the distal phalanx of the long finger.[5] Unfortunately, metacarpal and phalangeal fractures are often neglected or regarded as trivial injuries.[6] Swanson aptly stated: "Hand fractures can be complicated by deformity from no treatment, stiffness from overtreatment, and both deformity and stiffness from poor treatment."[7]

The incidence of metacarpal and phalangeal fractures peaks between 10 and 40 years and is most common in males,[8,9] a time when athletic and industrial exposure is the greatest. Sporting injuries alone accounted for nearly one-quarter of metacarpal and phalangeal fractures in a recent prospective population database from the United Kingdom.[10,11] Chung and Spilson,[12] using data from the National Hospital Ambulatory Care Survey, estimated that in 1998 there were approximately 1.5 million hand and forearm fractures in the United States. More than 600,000 of these were metacarpal and phalangeal fractures. Using 2010 U.S. census data, Karl et al. noted an incidence of phalangeal and metacarpal fractures to be 12.5 and 8.4 per 10,000 persons, respectfully.[13] While distal radius fractures were more common overall with a bimodal age distribution, metacarpal and phalangeal fractures were the most common upper extremity fractures in patients 18 to 49 years of age.

Until the early part of the 20th century, these fractures were all managed nonoperatively. In fact, the entire history of operative fixation for hand fractures is limited to the last 100 years[14] and was pioneered by Albine Lambotte.[15] Despite significant advancements in surgical techniques and implants, even today, the vast majority of these fractures can be successfully managed by nonoperative techniques.[16]

Most fractures are functionally stable either before or after closed reduction and will fare well with protective splintage and early mobilization.[17] Certain fractures require operative fixation (Box 7.1). Selection of the optimum treatment depends on a number of factors, both fracture-specific and patient-specific. Fracture-specific factors include fracture location (intraarticular versus extraarticular), fracture geometry (transverse, spiral or oblique, comminuted), deformity (angular, rotational, shortening), the presence of open wounds, associated osseous and soft tissue injuries, and fracture stability. Additional patient-specific considerations include age, occupation, handedness, and socioeconomic status; the presence of systemic illnesses; compliance; and ability to tolerate the requisite period of immobilization for nonoperative care.

Numerous treatment options exist, including immobilization with casts or splints, percutaneous techniques, and open reduction with internal or external fixation. Each of these modalities is acceptable, and treatment must be individualized based on fracture-specific and patient-specific consideration. Regardless of the treatment selected, the goal is maximal restoration of hand function in a timely fashion with minimal morbidity. Over the last several decades, operative fixation of hand fractures has gained increasing popularity.[18-20] Current operative trends include minimally invasive techniques such as intramedullary screws, immediate postoperative motion protocols, and wide awake surgery local anesthesia no tourniquet (WALANT).

Although prolonged immobilization is to be avoided because of the risk of permanent deformity and stiffness, one should remember that overly aggressive attempts at internal fixation may lead to soft tissue damage, tendon adhesion, infection, and the necessity for a secondary procedure for implant removal. Operative fixation must be used judiciously and with the expectation that the ultimate outcome will be as good as or better than the anticipated outcome of nonoperative management.

METACARPAL FRACTURES (EXCLUDING THE THUMB)

Metacarpal Head Fractures

Fractures of the metacarpal head are rare and are usually articular. In a series of 134 closed articular fractures of the metacarpophalangeal (MCP) and proximal interphalangeal (PIP) joints, Hastings and Carroll noted five metacarpal head fractures.[21] These fractures are usually the result of axial loading or direct trauma (crush or clenched-fist injury). Any open fracture of the metacarpal head should carry a high index of suspicion for a clenched fist injury or "fight bite."

McElfresh and Dobyns reported on 103 intraarticular metacarpal head fractures.[22] The injury involved the index metacarpal most frequently, presumably because it is a border digit and its metacarpal base is fixed to the carpus. The fractures were classified into several categories (Box 7.2). Comminuted fractures were most common. Half the patients with comminuted fractures had loss of more than 45 degrees of flexion at the MCP joint. Articular defects may remodel with time, and unlike weightbearing joints, an incongruous MCP joint may function satisfactorily with painless motion.

Articular fractures of the metacarpal head can also occur following complex dorsal MCP dislocations. Becton et al.[23] noted such a fracture in 7 of 13 patients and recommended open reduction and internal fixation (ORIF) through a dorsal approach. Additionally, the presence of a metacarpal head fracture can render MCP joint dislocations irreducible, thus necessitating ORIF through either volar, dorsal, or combined approaches.[24-26]

X-ray evaluation requires a minimum of three views: posteroanterior, lateral, and oblique. The lateral view is difficult to interpret because

44) No membro superior, a tuberculose raramente envolve

a) pele
b) subcutâneo
c) nervo
d) articulação

Resposta C

referência Green página 106

TABLE 3.8 Growth Rates of Mycobacteria

Slowly Growing	Rapidly Growing (<7 days)
M. avium complex (M. avium and M. intracellulare)	*M. fortuitum*
M. kansasii	*M. chelonae*
M. xenopi	*M. smegmatis*
M. szulgai	*M. abscessus*
M. scrofulaceum	*M. fortuitium*
M. malmoense	
M. terrae	
M. haemophilum	
M. asiaticum	
M. gordonae	

Growth rates have become a practical means of grouping the species within laboratories.

abscess in a muscle. Cold abscess of muscle has occurred in deltoid, brachialis, or biceps brachii muscles. Corticosteroids can cause reactivation of a latent focus of extrapulmonary TB in an immigrant from an endemic country or after organ transplantation.

Cutaneous Mycobacterial Infections

Clinical Findings

In the upper extremity, TB may involve skin, subcutaneous tissue, bursa, tendon, joint, bone, muscle, or rarely an artery or a nerve. The most common TB infection of the hand involves the skin; 80% of cutaneous TB affects the hand and the upper extremity. It is rare in childhood, even in countries with a high burden of TB. It may be acquired in the skin in one of the following ways: by inoculation from an exogenous source through a breach in the skin, inoculation by tattoo needles, by acupuncture needles, by BCG vaccination, by contiguous spread from bone to skin (scrofuloderma), or by hematogenous spread to skin from a pulmonary or extrapulmonary focus (lupus vulgaris). One case of scrofuloderma (Tuberculosis cutis colliquative) due to tuberculous dactylitis in an adult was reported in 2018. An underlying disease that compromises host immunity may be found in up to 30% of cases. Cutaneous TB of the hand in AIDS patients occurs in rare cases.

Skin infections can be caused in medical personnel by accidental primary inoculation with a cannulated needle withdrawn from an infected patient, primary inoculation of a surgeon from a blade that operated on tuberculous tissue, accidental injection of infected fluid in the laboratory, or mycobacterial infection from autopsy material (i.e., prosector's paronychia). Tuberculous paronychia has been reported in a nurse caring for a patient with active pulmonary TB. The disease is usually self-limited if host immunity is high, but chemotherapy expedites cure and reduces morbidity. Surgical excision of the lesion is clearly indicated for one caused by accidental inoculation by a known drug-resistant organism.

M. marinum (M. balnei) is the most commonly reported NTM skin infection of the hand in Western countries and *M. tuberculosis* in Eastern countries. Fish tank exposure is the most frequent source of cutaneous *M. marinum* infections and can be prevented by use of waterproof gloves by anyone with an open skin lesion. The lesions are usually multiple. A traumatic lesion in a laboratory worker working with *M. marinum* may be single at the site of injury. Cutaneous infections by *M. kansasii* may heal spontaneously over a period of time, but chemotherapy may be given to expedite healing and prevent scarring. A TB skin gumma can occur on the hand after a contaminated skin venipuncture. *M. bovis* skin infection can occur occupationally in butchers (butcher's wart).

Diagnosis

The most common presentation is a node, abscess, ulcer, or a plaque lesion on the finger, hand, or forearm. A nontender nodule gradually progresses to single or multiple abscesses that drain clear liquid. Nodules do not heal with antibiotics and soaks. Less common presentations include erythema, swelling, cellulitis, crusting, verrucous plaque, verrucous nodule, sporotrichoid lesion, and ulceration. Gumma of the skin is a rare presentation of cutaneous TB and may occur in an adolescent.[196] Cortisone exacerbates the disease. Signs of lymphatic spread are evident in 70% of cases. Multiple, marching, linear lesions may be seen along the lymphatics on the hand, wrist, and forearm (i.e., sporotrichoid type) (see Figs. 3.17 and 3.20).

Most patients have lesions for 2 months or more before they seek care, and there is usually a substantial delay between initial consultation and correct diagnosis because of the rarity of the condition. Patients infected with *M. marinum* give a history of a puncture wound involved with a fish, fish tank, or swimming pool in more than half the cases. Such a lesion is aptly known as "fish tank granuloma," "fish tank finger," "fish fancier's finger," "swimming pool granuloma," and "fish breeder's granuloma." To this list we can add "fish cleaner's finger" in women who clean fish without gloves. An outbreak of *M. marinum* occurred in 2014 in New York among Chinese housewives who cleaned fish without gloves (Fig. 3.26). A pustular or nodular phase may subsequently ulcerate to form a "tuberculous chancre"; rarely it may present as marching plaques. Regional lymphadenopathy develops in 3 to 4 weeks after the primary skin lesion is noted. The tuberculous chancre and affected regional lymph nodes constitute the "tuberculous primary complex" of the skin, akin to the classic Ghon lesion in the lung where there is a subpleural parenchymal lesion and hilar lymphadenopathy. Organisms may not be seen on AFB staining, and cultures may not grow mycobacteria. Under these circumstances, the detection of mycobacteria by PCR to analyze nucleic acid sequences is recommended, useful, and diagnostic.

Differential Diagnosis of Sporotrichal-Like Marching Lesions

The linear, marching lymphangitis typical of *Sporothrix* infection can also be seen with infections caused by *M. marinum, M. kansasii, Leishmania, Coccidioides, Cryptococcus, Nocardia,* and tularemia. TB cutaneous infection of the hand can also be confused with infection by blastomycosis, histoplasmosis, syphilis, and yaws. Final diagnosis of TB infection requires skin biopsy with mycobacterial culture. Rarely, TB and Hansen disease may coexist in the same patient.

Treatment

The Ukrainian-born U.S. researcher Selman Waksman was awarded a Nobel Prize in 1952 for his discovery of streptomycin in 1943 at Rutgers University in New Jersey—the first antibiotic demonstrated to be effective against TB. To avoid resistance, *M. tuberculosis* infection is treated with a combination of bactericidal drugs, including isoniazid and rifampin taken daily for at least 6 months, as well as ethambutol and pyrazinamide for the first 2 months. Prompt chemotherapy is curative.

Treatment of NTM infection differs from treatment of TB. Optimal treatment of cutaneous *M. marinum* infection is not well established. Mild infection resolves spontaneously but complete resolution may take up to 2 years. A two-drug combination is recommended to prevent resistance. *M. marinum* is sensitive to clarithromycin, rifampicin, ethambutol, minocycline, and levofloxacin. Resistance to tetracycline, minocycline, doxycycline, and rifampin is emerging. Thus results of

45) Na classificação de Weiss- Hasting para as fraturas unicondilares da falange proximal, o tipo coronal dorsal corresponde ao

a) I
b) II
c) III
d) IV

Resposta C

referência Green página 285

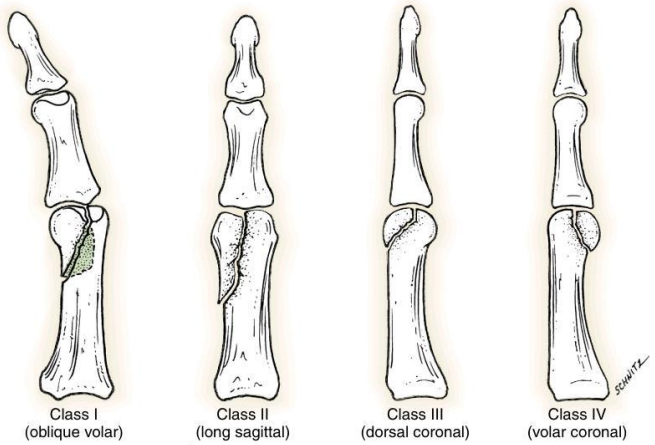

Fig. 7.29 Weiss–Hastings classification of unicondylar fractures of proximal phalanx. These fractures are nearly all unstable and nearly always require operative fixation. (From Weiss AP, Hastings H 2nd. Distal unicondylar fractures of the proximal phalanx, *J Hand Surg Am* 18[4]:594–599, 1993.)

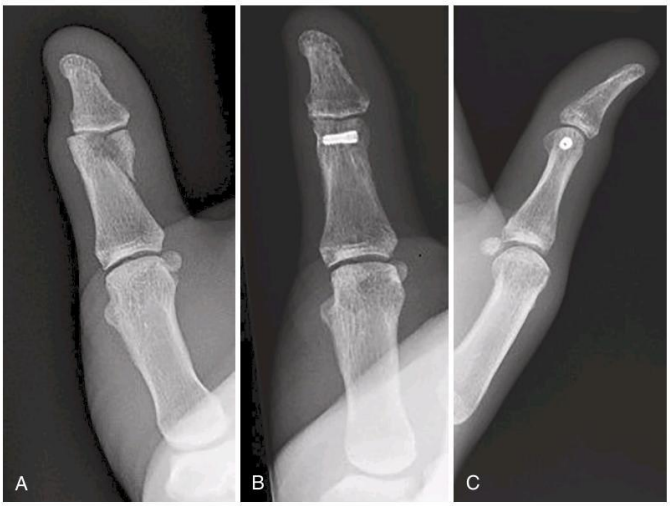

Fig. 7.30 **A,** Preoperative AP radiograph of a thumb unicondylar fracture of the proximal phalanx. **B** and **C,** Postoperative AP and lateral x-rays demonstrating anatomic fixation with a buried headless compression screw.

displaced lateral corner fractures that do not compromise joint stability or result in an incongruous articular surface can be treated by splinting for 10 to 14 days, followed by protected motion. Lee[314] collected 27 corner avulsion fractures of the proximal phalanx. All but two patients were managed nonoperatively by splintage for 2.5 weeks, and all but two fractures united in the original displaced position. Significantly displaced lateral corner fractures may compromise joint stability, and "Stener-like" lesions can occur by interposition of a portion of the sagittal band into the fracture site.[315] The recommended treatment is open reduction and fixation with either Kirschner wires, tension wire, lag screws, or hook plate.[310,311,316-318] This may be performed through either a volar or dorsal approach. The dorsal approach is the simpler and more commonly used approach performed through a dorsal midline skin incision. The avulsed fragment as mentioned can herniate through the sagittal band, especially on the radial side of the digit. The proximal aspect of the sagittal band is released to expose the displaced fragment, which can then be repaired

46) No estágio 2 de Garcia Elias para a dissociação escafolunar, a reabilitação com exercícios proprioceptivos dos músculos supinadores intracarpais, são recomendados apenas em lesões classificadas pela European Wrist Arthroscopy Society (EWAS) tipo

a) I e II
b) II e IIIA
c) IIIB e IIIC
d) IV

Resposta B

referência Green página 514

had stage II instability and the other 5 were stage IIIB. After 16 months of follow-up, the authors reported correction of carpal malalignment and improvement in functional outcome scores.

Garcia-Elias stage 2: scapholunate dissociation, reparable. This stage is characterized by a complete disruption of the entire SLIL (including the dorsal component) with preservation of the dorsal ligament complex (DST, DRC, and DIC) and the distal scaphoid stabilizers (STT and SC ligaments). By definition, carpal malalignment is dynamic, not static; it appears only under certain loading conditions (e.g., clenched fist, loaded ulnar deviation). The scaphoid is not abnormally flexed, the RS angle is normal, and there is little or no SL gap. The condition is characterized by painful alteration of carpal mobility and inability to sustain full load in most wrist positions.

According to Andersson et al.,[118] there are four major types of dSLIL ruptures: avulsion from the scaphoid (42% of all dSLILs), avulsion from the lunate (18%), midsubstance rupture (20%), and partial rupture plus elongation (22%). If the healing potential, acuity, substance, and vascular supply of the disrupted ligament are optimal, one option is an arthroscopy-guided closed reduction and percutaneous fixation. Alternatively, an open repair of the dorsal and proximal portions of the SL ligament may be performed. This needs to be augmented with either percutaneous Kirschner wire fixation or suture stabilization. Frequently the ligament is avulsed, with or without a small piece of bone; this occurs most commonly from the scaphoid. In these cases, a successful repair can be expected beyond the time limits of what could be expected from an intrasubstance rupture.

Proprioceptive reeducation of the intracarpal supinator muscles is no longer adequate in stage II as an isolated treatment. Indeed, if the dSLIL is disrupted, supination of the distal carpal row does not reduce the SL joint but instead creates an unconstrained dorsally directed vector that promotes scaphoid dorsal subluxation of its proximal pole. Certainly, proprioceptive exercises of the intracarpal supinator muscles are only recommended in EWAS II and IIIA partial injuries, where the dSLIL is intact.

Arthroscopic capsulodesis of subtotal or complete SL ligament. As noted earlier, arthroscopic techniques have been reported to repair a SL ligament injury, including chronic and complete disruptions. Mathoulin and colleagues[127] reported on the outcomes of an arthroscopic dorsal capsuloplasty with and without carpal pinning in 22 patients with an average follow-up of 13 months. According to the Geissler classification, there were 5 patients at grade 2, 14 at grade 3, and 3 at stage 4 (3, 8, and 11, respectively, in the Garcia-Elias classification). All of the patients with grade 4 Garcia-Elias instability received temporary Kirschner wire fixation. Eighty six percent of patients achieved 85% or more ROM, and the average grip strength was 96% of the contralateral wrist. The mean postoperative disabilities of the arm, shoulder, and hand (DASH) score was 6.1 (0 to 40.1) compared with the preoperative score of 34.5 (16.4 to 47.6). The results obtained after arthroscopic dSLIL repair and capsuloplasty by Wahegaonkar and Mathoulin[128] and the arthroscopic repair of the palmar SL ligament by Piñal[99] have also yielded encouraging results. See arthroscopic techniques in Chapter 17 for more details.

Technique: open reduction, internal fixation, and repair of the dorsal SL ligament. This approach offers the same advantages as when treating acute ligament injuries in other joints, provided the subluxation is reduced. A direct, solid repair of torn ligaments should be carefully performed, and all associated osteochondral injuries explored and repaired. Appropriate stabilization with Kirschner wires or temporary screw fixation should be performed. Failures may be explained by the excessive forces produced by the capitate trying to separate the SL joint, unrecognized injury to other critical supporting ligaments, the poor healing potential of chronic or devascularized ends of the disrupted ligaments, or the prolonged immobilization required after surgery. Despite these factors, we agree with authors who believe there is a place for primary, acute repair in properly selected patients.[129]

Data from cadaveric biomechanical studies support the premise that only the dSLIL needs to be repaired to achieve relatively normal carpal kinematics.[44] Other authors claim better results by repairing both the palmar and dSLILs, through a double palmar and dorsal approach, despite the obvious difficulty of getting access to the palmar component without damaging the palmar extrinsic ligaments.

The open dorsal repair skin incision may be longitudinal, "Z"-shaped, or transverse; the latter two incisions may result in a more esthetic scar. The extensor retinaculum is divided longitudinally over the third dorsal compartment, being careful not to injure the extensor pollicis longus (EPL) tendon. The authors recommend visualizing the dorsal capsule by lifting the retinaculum to the ulnar side, exposing the third, fourth, and, if needed, fifth extensor compartments. In most cases the second dorsal compartment can be left undisturbed, and the EPL primarily transposed outside of the retinaculum on closure.

Next, the floor of the fourth compartment is explored, and the posterior interosseous nerve is left undisturbed if found to be normal. If the posterior interosseous nerve is felt to be nonfunctional, damaged, or irregularly thick, a 2 cm section may be excised at the surgeon's discretion. The "radiocarpal window" capsular incision (Fig. 13.27A) starts beneath the tendons of the second dorsal compartment near the styloid tip, with care taken to protect the underlying cartilage of the carpus. At the Lister tubercle, the capsular incision takes a distal and oblique course, distal to the fibers of the DRC, only as far as is necessary to visualize and treat the torn SL ligament. Every attempt is made to protect and preserve the DIC and DRC insertions on the dorsal lunate. The window flap is raised distally to expose the torn ligament, and the DST ligament fibers are inspected. It is important that the dorsal intercarpal and DST ligaments are not detached from their insertions on the three bones of the proximal row. If necessary for visualization, a "midcarpal window" can be incised through the capsule on the distal edge of the DIC to gain wide exposure of the proximal and distal row bones at the midcarpal joint (see Fig. 13.27B). Alternatively, if one desires to perform the "fiber splitting capsulotomy" approach as described by Berger and colleagues,[4,130] it is recommended that the surgeon make every attempt to repair the DIC and DRC ligament attachments to the scaphoid and lunate with bone anchors, as described by Viegas et al.[12] Recent cadaveric research has demonstrated that the "fiber splitting" approach detaches the dorsal intercarpal, DRC, and DST ligament insertions on the lunate and scaphoid, and their stabilizing role for the proximal carpal row is not restored with bone anchor closure alone.[131]

Frequently, when operating early on a torn dSLIL, there is sufficient ligamentous tissue to permit a direct repair. If the ligament is not ruptured but avulsed with a bone fragment, the repair is more effective and consists of reattaching the avulsed ligament, with or without a bone fragment, to the freshened dorsal edge of the scaphoid or lunate. Transosseous sutures[132] or suture anchors are used[133] (Fig. 13.28). An open repair is typically protected by transfixing the SL and SC joints with Kirschner wires or a temporary SL screw. Several authors recommend reinforcing the repair with a dorsal capsulodesis, as will be described in the following section.[102,134] The fixation is maintained for 8 to 10 weeks with protection in a removable splint for an additional 4 weeks.

In recent years, special attention has been drawn to the fact that, during DTM, the majority of carpal motion occurs at the midcarpal joint, with the proximal row remaining relatively stationary. Based on these findings, it has been suggested that, after an SL ligament repair, early dart-throwing mobilization of the midcarpal joint could have a beneficial effect on stiffness, while avoiding tension on the repair. Recent studies using dynamic 3D CT of patients with SLDs have

47) As fraturas do olécrano com subluxação posterior, anterior ou em varo do antebraço em relação ao úmero distal, pela classificação da *MAYO CLINIC*, são do tipo

a) I
b) IIA
c) IIB
d) III

Resposta D

referência Green página 939

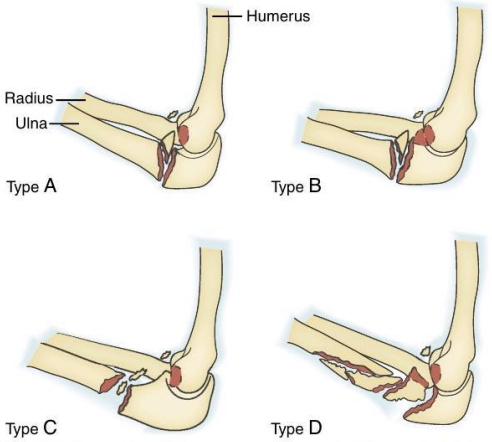

Fig. 20.4 Illustration of a spectrum of posterior Monteggia injuries. Type A: injury at the ulnohumeral joint with fractures of the olecranon and coronoid; type B: injury at the most common location, the proximal ulnar metaphysis; type C: injury at the diaphyseal level; type D: complex fractures that involve multiple levels. (Copyright © Massachusetts General Hospital Department of Orthopaedic Surgery.)

Fracture of Proximal Ulna With Posterior Subluxation of the Radiocapitellar Joint and Fracture of the Radial Head

Extraarticular fracture of the proximal ulna metaphysis distal to the coronoid, with posterior radiocapitellar subluxation and—in most cases—fracture of the radial head, is sometimes referred to as a posterior Monteggia lesion,[34,35] but this grouping is confusing because the radioulnar relationship is maintained. As suggested by Jupiter and colleagues, this injury pattern has more in common with posterior olecranon fracture-dislocations[36] (Fig. 20.4). Treatment consists of realignment of the ulna, plate and screw fixation, and selective repair or replacement of the fractured radial head, with occasional reattachment of lateral collateral ligament avulsion from the epicondyle.

Olecranon Fractures and Fracture-Subluxation

The Mayo classification of olecranon fractures distinguishes three factors that have a direct influence on treatment: (1) displacement, (2) fragmentation, and (3) ulnohumeral joint subluxation (Fig. 20.5).[6] Type I fractures are the uncommon nondisplaced or minimally displaced fractures that are treated nonoperatively. Type II fractures are displaced and either simple (IIA) or fragmented (IIB). Nonfragmented fractures can be treated with a screw, wires, or suture. Fragmented fractures are repaired with a plate and screws. Type III fractures are injuries with anterior, posterior, or varus subluxation of the forearm relative to the distal humerus.

Olecranon Fracture-Subluxations

On rare occasions, a simple elbow dislocation or terrible triad injury is associated with a fracture of the olecranon (Fig. 20.6 and Case Study 20.1). The pattern of olecranon fracture may represent a bony alternative to rupture of the medial collateral ligament complex. Most traumatic elbow instability featuring fracture of the olecranon does not involve complete loss of apposition of the articular surfaces (true dislocation), and the ligaments are typically relatively intact. Anterior (transolecranon) olecranon fracture-subluxations are often caused by

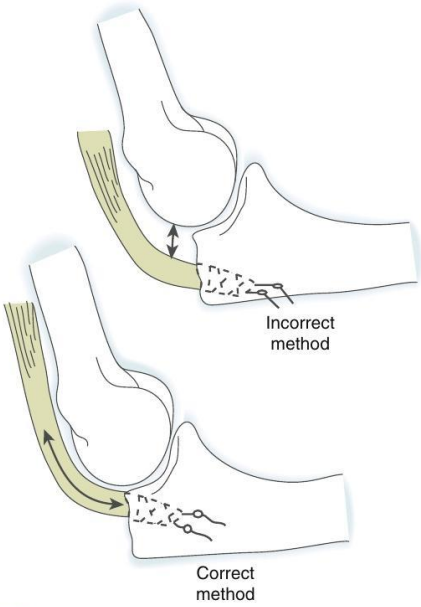

Fig. 20.5 When the triceps is advanced and reattached to the proximal ulna after olecranon excision, it is better to insert it close to the articular margin.

Fig. 20.6 In this unusual case, a patient has sustained a posterior dislocation of the elbow associated with a fracture of the olecranon process on the medial aspect, essentially avulsing the posterior aspect of the medial collateral ligament complex. (Copyright © David Ring, MD.)

48) Na ossificação heterotópica, que ocorre após fraturas de cotovelo e de antebraço, a perda parcial da supinação e pronação é classificada por Hastings e Graham como tipo

a) II
b) IIA
c) IIB
d) IIC

Resposta C

referência Green página 967

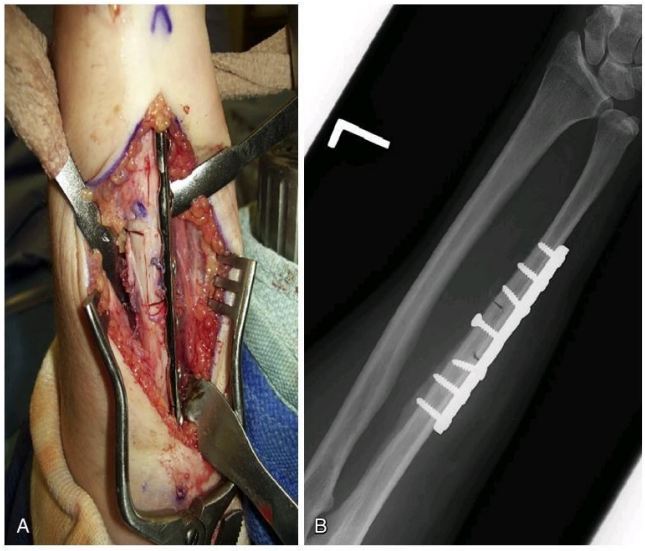

Fig. 21.26 **A,** Step-cut osteotomy of the ulna. **B,** Radiograph showing step-cut osteotomy of the ulna with lag screw across the osteotomy site.

Fig. 21.27 Posttraumatic radioulnar synostosis.

2. Healed fracture(s) in acceptable alignment
3. Normal PRUJ and DRUJ
4. A compliant IOM and soft tissue envelope

A preoperative CT scan of the forearm, including the PRUJ and DRUJ, will show whether the first three factors are present. The presence of factor four is more difficult to assess, but skin contractures from burns or crushing and degloving injuries may hinder efforts to restore motion.

The location of the synostosis as defined by a CT scan will determine the surgical approach. Proximal synostoses may be accessible by elevating the anconeus and common extensor muscle mass. In cases where the bone extends anteriorly, it may be prudent to use an anterior approach in which the median and radial nerves can be identified and protected. Access to middiaphyseal synostoses is typically via an anterior Henry approach. Exposure along the subcutaneous border of the ulna is also an option. Distal synostoses can be reached through an anterior or dorsal approach. There may be an associated soft tissue contracture that will limit motion after bone resection (e.g., release of the anterior capsule of the DRUJ often helps recover forearm supination).

Surgical hardware may be left in place unless it is specifically limiting exposure or range of motion. Intraoperative fluoroscopy is used

TABLE 21.1 Classification of Heterotopic Ossification

Class	Description
Class I	HO that does not cause functional limitation
Class II	HO that causes subtotal limitation of motion
Class IIA	Partial loss of elbow flexion-extension
Class IIB	Partial loss of forearm supination-pronation
Class IIC	Partial loss of both flexion-extension and supination-pronation
Class III	Complete ankylosis of the elbow or forearm, or both

HO, Heterotopic ossification.
From Hastings H 2nd, Graham TJ: The classification and treatment of heterotopic ossification about the elbow and forearm, *Hand Clin* 10(3):417–437, 1994.

49) Na paralisia do nervo mediano associada a paralisia completa dos músculos intrínsecos da mão, o polegar pode adotar uma posição de

a) supinação e adução
b) pronação e adução
c) extensão e adução
d) extensão e supinação

Resposta A

referência Green página 1192

and retroposition, usually 90 degrees of pronation and 60 degrees of supination, respectively, occurs on the spheroid area of the saddle-shaped trapezial articular surface. Pronation is probably an obligatory passive movement that occurs during circumduction toward the palm as a result of the force-couple produced by thumb intrinsic muscle contraction and passive tension within the dorsal trapeziometacarpal ligament. Retroposition probably also occurs passively during thumb extension as a result of the force-couple produced by contraction of the EPL and the extensor pollicis brevis (EPB) and the abductor pollicis longus (APL) muscles and passive tension within the radiopalmar (anterior oblique) ligament. Although the force-couples may be the prime mechanism of axial rotation, other mechanisms must exist inasmuch as thumb pronation is preserved after trapeziectomy.

The prime muscle of thumb opposition is the APB, although both the opponens pollicis and FPB also produce some opposition. The adductor pollicis (AP) and the two extrinsic thumb extensors cause thumb retroposition, whereas the FPL can act as a muscle of either opposition or retroposition, depending on the position of the thumb.

The classic description of thumb intrinsic muscle innervation is that the APB, the opponens pollicis, and the FPB are supplied by the motor branch of the median nerve, whereas the AP is supplied by the deep branch of the ulnar nerve. However, there is considerable diversity in the pattern of innervation, and clinical studies suggest that all the thenar muscles are innervated, in part at least, by either the ulnar (2%) or the median (2%) nerve in a few instances. Furthermore, the FPB remains functional in 73% of complete median and 58% of complete ulnar nerve injuries, thus demonstrating that this muscle frequently has a dual median and ulnar innervation.[19] Anatomic dissection suggests that the median nerve supplies the APB, the opponens pollicis, and the superficial head of the FPB in 63% of hands, but only the APB and the opponens pollicis in 30% of hands.[20]

Zancolli and Cozzi believe that the superficial head of the FPB has dual median and ulnar innervation in 30% of hands, whereas its deep head has dual innervation in 79% of cases but is exclusively supplied by the ulnar nerve in 19%.[21] They also believe that the oblique head of the AP has dual ulnar and median innervation in 35% of cases, whereas its transverse head is practically always (96%) innervated by the ulnar nerve. Although some of these findings are contradictory, the variability of thenar muscle innervation explains why thumb abduction and opposition are frequently retained after complete median nerve injuries.[22,23]

The Deficit and the Deformity

Thumb abduction and opposition are frequently retained after isolated median nerve injury as a result of preserved ulnar nerve function. Jensen[24] believed that opponensplasty was required in only 14% of median nerve injuries, and it is my experience that reasonable opposition is commonly retained in complete median nerve transections. Furthermore, I find that satisfactory thumb opposition is usually retained in severe carpal tunnel syndrome, even in the presence of significant thenar wasting. Foucher and colleagues found only 7% of the patients with severe carpal tunnel syndrome had absent or inadequate thumb opposition.[25] All the thenar intrinsic muscles are paralyzed after combined median and ulnar nerve injuries; in this situation, thumb opposition is absent and the patient is only able to flex the thumb across the palm by using the FPL. In combined ulnar and high median nerve injuries, resting thumb posture tends to be extended and supinated by the unopposed extrinsic extensor muscles.

Tendon Transfers to Restore Thumb Opposition

History. Steindler is credited with performing the first opponensplasty in 1917. He attached a radial slip of the FPL tendon onto the dorsum at the base of the thumb's proximal phalanx.[26] Shortly afterward, Cook used the extensor digiti minimi (EDM) for an opponensplasty[27] and Ney attached either the palmaris longus (PL) or FCR to the EPB tendon, which was rerouted through the carpal tunnel.[28] Huber[29] in 1921 and Nicolaysen[30] in 1922 described ADM opponensplasty.

Bunnell[4] in 1924 and Camitz[31] in 1929 both reported that the PL tendon could be satisfactorily elongated with a strip of palmar aponeurosis so that it could be used in an opponensplasty without the need for a tendon graft. To maximize thumb opposition, Bunnell recommended passing the transferred tendon through a pulley on the ulnar border of the wrist so that it ran subcutaneously across the palm to its thumb insertion.[4,32] Thompson[33] used the ulnar border of the palmar aponeurosis as a pulley for Royle's superficialis transfer.[34] A limitation of both the palmaris and superficialis transfers is that they are useful only for low median nerve palsies. Aguirre and Caplan, in 1956, first described EIP opponensplasty, which can be used for both high and low median nerve palsies and does not require manufacture of a pulley or a tendon graft.[35]

Patient counseling. Although the indication for an opponensplasty is loss of opposition, the need for surgery is loss of function due to loss of opposition. If loss of opposition is unilateral, especially if it affects the nondominant hand, then the consequent loss of function may be minimal and insufficient to warrant surgery. Additionally, if there is also loss of or absent sensation in the median nerve territory, this may reduce any potential benefit of an opponensplasty because the loss of function is primarily due to the loss of sensation. Careful patient counseling about the possible functional benefit, the rehabilitation process, and the likely outcome of surgery (this may be somewhat less than the published success rates for restoration of opposition movement) is mandatory. The surgeon must have a clear picture of the functional disability and be confident that this is due to the loss of opposition and not to other factors (e.g., sensory impairment or joint stiffness).

General principles of tendon transfer with reference to opponensplasty

Prevention and preoperative treatment of contractures. With median nerve palsy and complete intrinsic paralysis, the thumb may adopt a supinated and adducted position, and a first web space contracture can develop. This is readily prevented by passive thumb abduction and opposition exercises, supplemented by abduction splints as needed. Temporary internal splintage of the thumb metacarpal in abduction with a Kirschner wire may be indicated when there is an associated acute severe thenar or first web space soft tissue injury and thus a high risk of first web space contracture.

Established soft tissue contractures must be corrected either before or during opponensplasty because no opponensplasty has sufficient strength to improve a preoperative passive loss of opposition. Failure to detect and correct contractures preoperatively is a common cause of failure.[36] First web space contractures are generally due to contractures of the skin and deep fascia on its extensor surface[15] and usually can be readily detected. However, contracture of the dorsal capsule of the trapeziometacarpal joint, which restricts opposition but permits abduction, is detected only by careful clinical examination.[37] If supervised physiotherapy and splintage[38] fail to correct a contracture, surgical release is indicated.

In the absence of any injury to the thenar muscles or the base of the thumb, first web contractures usually can be released satisfactorily through a dorsal web space incision. The fascia over the AP and the first dorsal interosseous muscles is released and the dorsal web space skin widened with a skin graft or flap.[15,39] Isolated capsular contractures of the trapeziometacarpal joint should be released through a

50) Na paralisia obstétrica a segunda lesão mais comum é

a) C5-C6 pré ganglionar
b) C5-C6 pós ganglionar
c) C5-C6-C7 pré ganglionar
d) C5-C6-C7 pós ganglionar

Resposta D

referência Green página 1563

TABLE 40.1 Indicators of Avulsion Injuries and Poor Prognosis for Recovery

Finding	Implication
Paraspinal muscle injury	Dorsal rami injury
Rhomboid injury	Dorsal scapular nerve (C5)
Scapular winging	Long thoracic (C5, C7, C8) injury
Horner's syndrome	Cervicothoracic sympathetic injury
Hemidiaphragm paralysis	Phrenic nerve injury
Pseudomeningocele	Dura and arachnoid avulsion injury

For prognostic reasons, it is important to determine whether the level of injury is preganglionic or postganglionic (see Fig. 40.2). Because of the proximity of the dorsal root ganglion to the spinal cord and the fact that the motor cell body is in the spinal cord, preganglionic lesions are avulsions from the cord that will not spontaneously recover. By assessing the function of several nerves that arise close to the midline and the ganglion, one can frequently determine the level of the lesion by physical examination (Table 40.1). Specifically, the presence of an elevated hemidiaphragm (phrenic nerve, C5 nerve root), the absence of rhomboid major and minor (dorsal scapular nerve, C5 nerve root), a winged scapula (long thoracic nerve, C5-7 nerve roots), and the presence of a Horner syndrome (sympathetic chain, T1 nerve root) all raise concern about a preganglionic lesion.

Preganglionic lesions can be reconstructed only by nerve transfers,[51] most commonly with the thoracic intercostal nerves,[52-54] a branch of the spinal accessory nerve,[55] contralateral C7 nerve root transfers,[56] or partial peripheral nerve transfers. Postganglionic ruptures have reconstructible proximal and distal nerves beyond the zone of injury. Thus a postganglionic injury is a complex peripheral nerve lesion that can be reconstructed with intercalary nerve grafts. Peripheral nerve transfers can also be used to reconstruct these injuries. However, functional spontaneous recovery is also possible in postganglionic injuries, likely due to partial ruptures and redundant innervation pathways present at birth.[57] Narakas group I and those in Narakas II with complete biceps recovery by 4 months have a high likelihood of full function. Infants in groups III and IV are unlikely to achieve full function without surgical intervention.[58]

The majority of BPBIs involve the upper trunk.[59] The classic Erb palsy involves C5-6 (46%). The next most common injury (an extended upper trunk lesion or extended Erb's palsy) involves C5-7 (29%). With these injury patterns, the injury is most frequently postganglionic. When the lower plexus is involved, preganglionic avulsions of C8-T1 are most common, with additional avulsion of C7 often present. The exception to this situation is an upper trunk lesion seen with a breech delivery. These nerve injuries tend to be preganglionic C5-6 avulsions from the spinal cord[25] and are more commonly bilateral in presentation compared with vertex deliveries.

Most authors use the timing of specific motor function recovery and the absence of recovery as an indication for surgical intervention.[11,59] Wyeth and Sharpe in 1917 advised surgical intervention if no recovery was seen by 3 months of life.[60] Gilbert and Tassin concurred with the 3-month time interval and used recovery of antigravity biceps function as the key indicator of spontaneous recovery of the brachial plexus.[1] Waters similarly found biceps recovery to be statistically reliable.[3] Laurent and colleagues advised monitoring biceps, triceps, and deltoid function.[10]

Clarke and associates described the timing of return of elbow flexion and elbow, wrist, finger, and thumb extension as discriminators of outcome and used a combined threshold score of motor recovery of these muscles as an indication for nerve surgery.[61,62] Ultimately, Clarke advised that recovery at 9 months be assessed with a "cookie test" (i.e., inability to bring a cookie to the mouth with the arm at the side) to predict outcome and determine the need for microsurgical intervention in difficult cases with mixed recovery.

Grading recovery of specific muscles in an infant is difficult. Many centers use the Medical Research Council (MRC) muscle grading system to define results. The schema classifies muscle strength as 0 (no contraction), 1 (trace contraction), 2 (active motion with gravity eliminated), 3 (active motion against gravity), 4 (active motion against gravity and resistance), and 5 (normal power). However, this system requires volitional contraction and participation, which is not feasible in an infant and difficult in a young child. Understanding these difficulties, Gilbert and Tassin modified the MRC grading system to a four-grade classification using 0 (no contraction), 1 (contraction without movement), 2 (movement with gravity eliminated), and 3 (complete movement against the corresponding weight of the extremity).[1]

The modified Mallet classification (Fig. 40.4) provides a more global motor functional assessment of the upper trunk as opposed to isolated muscle testing.[63] This global shoulder motion system assesses hand-to-mouth, hand-to-neck, hand-to-spine, and hand-to-belly activities on a scale of 1 to 5. A sixth category of "internal rotation" has been added to better balance the Mallet classification with regard to external and internal rotation.[64] A score of 1 is no function, 5 is normal function, and grades 2 to 4 denote progressive improved strength, as shown in Fig. 40.4. The majority of late 20th century papers on infantile brachial plexus have used these classification schemes to determine the results of spontaneous recovery and surgical intervention.

More recently, Clarke and coworkers advocated use of the Hospital for Sick Children Active Movement Scale (AMS) (Table 40.2), a grading system that divides muscle strength into movement with gravity eliminated (grades 0 to 4) and movement against gravity (grades 5 to 7).[65] This system requires that full active motion with gravity eliminated to occur (grade 4) within the available range of passive motion before scoring antigravity muscle strength (5 to 7). The Toronto Test Score,[66] a similar grading of specific muscle functions at the elbow, wrist, and hand, is used only in infancy to predict the need for surgical nerve reconstruction, and it is not designed to track progressive recovery over time (Table 40.3). Thus no scoring system is without limitations.

The Mallet,[67] Toronto Test Score,[36] and AMS are statistically reliable in terms of interobserver and intraobserver analyses.[68,69] As might be expected, intraobserver reliability is better than interobserver, and less-complicated systems (Mallet) have higher reliability than more complicated schemes (AMS). The Pediatric Outcomes Data Collection Instrument (PODCI), which assesses parent and patient-reported function, has also been shown to be a reliable tool for measuring baseline function in children with chronic brachial plexus injuries against normative per age data, as well as for assessing postoperative changes in these children.[68,70] However, parent reports of their child's function can be confounded by litigation against the delivery team,[71] as this injury carries with it a strong emotional component that affects perceptions of function. This information is critical for comparing results and for assessing multicenter studies of therapeutic interventions for BPBI.

Recently the recognition that objective measurements and legacy measures may not correlate with enhanced function has resulted in a paradigm shift in outcome assessments. The initiative toward patient- or caregiver-reported outcomes has resulted in the development of reliable subjective measures. For children with brachial plexus injury, Shriners Hospitals for Children has developed patient-reported outcomes using the computer adaptive test (CAT) approach.[72,73] This methodology has been shown to correlate with legacy measures,

51) Na classificação das lesões da medula espinhal comumente usada, pela Associação American de Lesões Espinhais (ASIA), onde a função motora é preservada abaixo do nível neurológico, e a maioria dos músculos-chave abaixo do nível neurológico tem um grau muscular menor do que 3, é o tipo

a) A
b) B
c) C
d) D

Resposta C

referência Green página 1267

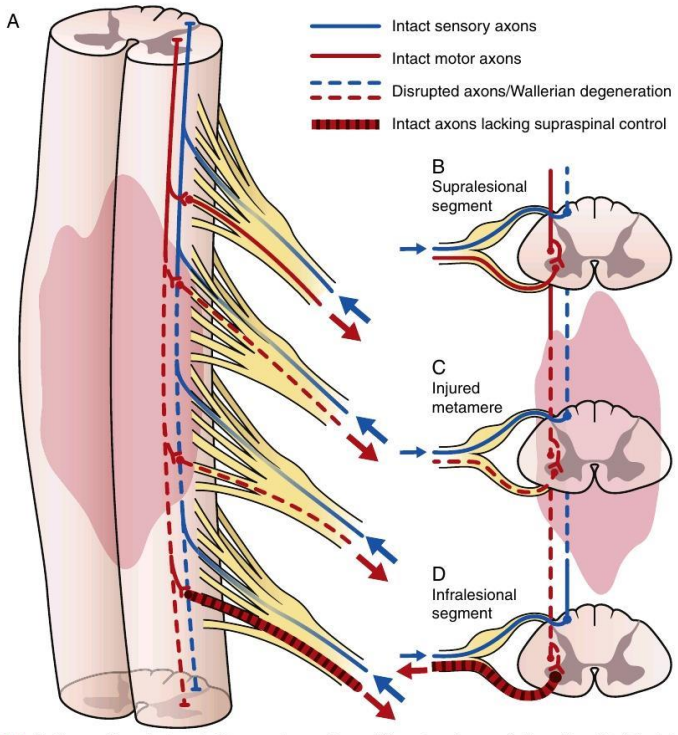

Fig. 33.2 **A,** Traumatic spinal cord injury produces three different patterns of disruption. **B,** Spinal lesions above the level of the injury maintain intact control of the peripheral nervous system **(C)** at the site of actual injury, which experiences both direct tissue disruption and alteration of in- and outgoing connections, and **(D)** the levels below the site of injury that maintain normal anatomic configuration but no longer receive descending electrical inputs. (Redrawn from Brown JM. The reconstructive neurosurgery of spinal cord injury. In: Dimitrijevic MR, Kakulas BA, McKay WB, Vrbova G, eds. *Restorative Neurology of Spinal Cord Injury*. New York: Oxford University Press; 2012, pp 134–168.)

TABLE 33.1 American Spinal Injury Association (ASIA) Scale

A	Complete	No sensory or motor function is preserved in sacral segments S4-S5
B	Incomplete	Sensory, but not motor, function is preserved below the neurologic level and extends through sacral segments S4-S5
C	Incomplete	Motor function is preserved below the neurologic level, and most key muscles below the neurologic level have a muscle grade of less than 3
D	Incomplete	Motor function is preserved below the neurologic level, and most key muscles below the neurologic level have a muscle grade that is greater than or equal to 3
E	Normal	Sensory and motor functions are normal

on the number of functional muscles below the elbow. The majority of persons with complete spinal cord injury will fall into ICSHT motor groups 2 and 3.

Another aspect of patient evaluation includes assessment of the general suitability for surgery. The assessment is based on various factors including age, occupation, level of education, learning capacity, motivation, economic support, family support, and agency support. The patient must have a clear understanding of what can and cannot be accomplished with surgery.

Physical Examination

The examination begins with a thorough history of the injury and treatment to date. Subsequently, a meticulous physical examination is performed, including sensory and motor testing to establish the patient's group (ICSHT level 0 to 9). Manual muscle testing (see Table 33.2) is performed on all muscle groups in the upper extremity. The surgeon can make a working list of tendons that are available for transfer (grade 4 strength or higher and expendable) and muscles that are paralyzed (grade 1 strength or lower). Once the muscles with grade 4

52) Na síndrome de Apert podemos indicar a ressecção do indicador, ou do dedo longo ou do anular no tipo

a) I
b) II
c) III
d) IV

Resposta C

referência Green página 1382

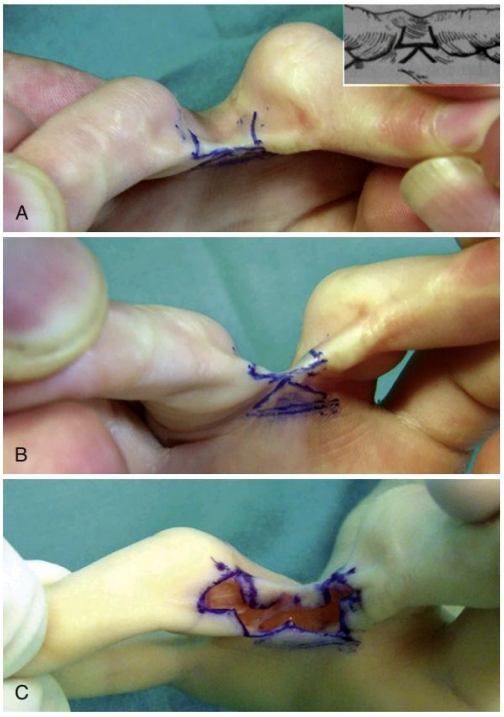

Fig. 36.12 Very short partial syndactyly (**A** and **B**), separated without need of a skin graft using a butterfly Z-plasty **(C)**.

separation can be performed very early and allowed to heal via secondary intention.

The Apert Hand

Apert syndrome combines a craniosynostosis and midfacial hypoplasia with complex syndactyly of the hands and feet. Apert syndrome is genetic and secondary to a mutation in the fibroblast growth factor receptor type 2 (FGFR2) gene located on chromosome 10q.[41] Several other acrocephalosyndactyly syndromes have been identified; however, the hand deformities are less complex. Apert syndrome has other upper limb manifestations, including shoulder and elbow dysplasia with stiffness, which usually do not require surgical intervention.[42] Prior to hand surgery, craniofacial anomalies should be addressed by neurosurgery and maxillofacial teams, usually around 3 months of age to improve anesthesia safety.[43]

The hand deformity is classified according to the involvement of the first web space and the appearance of the central mass (Table 36.1). The Apert hand has several key problems that must be addressed including syndactyly (including the first web), synonychia, symphalangism and/or finger stiffness, thumb brachydactyly and clinodactyly, and ring-small intermetacarpal synostoses (type II to III) (Figs. 36.22 and 36.23).[44,45]

There are many different treatment approaches to the Apert hand with variability between surgeons regarding timing and extent of management.[43,44,46-49] The goal is to complete separation of the digits before 2 years of age to allow for unimpeded growth and functional hand development. Although one stage reconstruction has been described,[50] most surgeons have adopted staged reconstructive strategies. The first stage is performed around the age of 9 months with subsequent surgeries occurring every 3 to 6 months.

Reconstruction of first web space is the first priority and is performed during the first stage. The goal is to position the thumb ray in 45 degrees of abduction. This requires release or lengthening of tight structures including the skin, fascia, intrinsic muscles, and carpometacarpal (CMC) joint (Fig. 36.24). Type I and II hands first web space skin deficits can be addressed with a four flap Z-plasty. Type III or II with severe first web space contractures require a dorsal advancement rotation flap.[31] Authors have proposed preliminary tissue expansion on the dorsum of the hand.[31,51] A pedicled or free flap is also an option to provide a wide first web reconstruction (Figs. 36.25, 36.26, and 36.27).

A distally curved central bone mass, if present, is also osteotomized into the phalangeal components during the first stage via a fish mouth incision. This converts the hand into the flat "spade" configuration (type I deformity) and allows for untethered growth of the central digits.[38,49]

The order and number of finger syndactyly releases and the need for ray resection depend on the type of deformity and surgeon preference. In the type III Apert hand, a ray resection of the index, long, or ring ray are all possibilities.[44,46,47] The advantage of resecting the index ray, especially if radially deviated, is increasing the width of the first web space. The advantage of resecting the ring ray and the intermetacarpal synostosis is increasing small finger motion.[46] There are no comparative functional studies between four- and three-fingered Apert hands.

An option in the Apert hand is a dorsal commissure flap combined with longitudinal incisions. This technique separates the fingers and leaves a longitudinal scar. However, the fingers are uniformly stiff in extension at the interphalangeal (IP) joints and do not develop flexion contractures. The soft tissue envelope of the Apert hand is usually extremely tight and fails to stretch (may be related to the fibroblast growth factor mutation). Separation results in extensive skin defects requiring coverage. This large amount of skin graft can be obtained from the lower abdomen and/or the medial arm. Soft tissue expansion in the coronal plane with an external fixator (Cube fix) to avoid skin grafting has been reported with good results.[52]

Most authors address thumb clinodactyly during the second stage. Thumb deformity is the result of delta-shaped and often fused phalanx and the abnormal insertion of the abductor pollicis brevis (APB) onto the distal phalanx causing metacarpophalangeal (MCP) joint radial deviation.[53] Reconstructive options include:

- A radial Z-plasty with opening wedge osteotomy and bone graft of the thumb phalanx. Bone graft sources include the iliac crest, any resected metacarpal, or bone from the resected intermetacarpal synostosis. Some authors perform this surgery after the age of 6 years to decrease recurrence rate.[54]
- Release of the abnormal APB insertion with reinsertion in the proximal phalanx combined with realignment osteotomy.[46,53]

The small finger ray is typically the least dysplastic and most mobile digit. However, intermetacarpal synostosis between the small and ring fingers lessens the mobility and prohibits the small finger from reaching the thumb (type II and III Apert hands).[53] Synostosis resection and interposition improves small finger motion for opposition.[44,45] The risk of synostosis recurrence is decreased when resection is performed after 5 years of age.

53) Na classificação modificada de Bayne para a deficiência longitudinal radial, no tipo 3 observamos o rádio distal

a) com encurtamento de 2 mm em relação à ulna
b) hipoplásico
c) fise ausente
d) ausente

Resposta C

referência Green página 1495

TABLE 38.1 Syndromes Associated With Radial Deficiency

Syndrome	Other Anomalies	Inheritance
VACTERL	Spinal, renal, gastrointestinal, cardiac	Sporadic
Holt-Oram	Cardiac (septal defects); other upper extremity malformations	Autosomal dominant
TAR	Thrombocytopenia, anemia; radius absent but thumb present	Autosomal recessive
Fanconi anemia	Pancytopenia	Autosomal recessive
Chromosome aberrations (trisomies 13 and 18)	Multiple	Sporadic
Nager, Rothmund-Thomson, IVIC	Craniofacial	Varies with the syndrome

IVIC, Instituto Venzolano de Investigaciones Cientificas; *TAR,* thrombocytopenia–absent radius; *VACTERL,* vertebral, anal, cardiac, tracheoesophageal, renal/radial, limb.

TABLE 38.2 Modified Bayne Classification of Radial Longitudinal Deficiency

Type	Thumb	Carpus	Distal Radius	Proximal Radius
N	Hypoplastic or absent	Normal	Normal	Normal
0	Hypoplastic or absent	Absence, hypoplasia, or coalition	Normal	Normal, radioulnar synostosis, or congenital dislocation of the radial head
1	Hypoplastic or absent	Absence, hypoplasia, or coalition	>2 mm shorter than the ulna	Normal, radioulnar synostosis, or congenital dislocation of the radial head
2	Hypoplastic or absent	Absence, hypoplasia, or coalition	Hypoplasia	Hypoplasia
3	Hypoplastic or absent	Absence, hypoplasia, or coalition	Physis absent	Variable hypoplasia
4	Hypoplastic or absent	Absence, hypoplasia, or coalition	Absent	Absent

Modified from Bayne LG, Klug MS: Long-term review of the surgical treatment of radial deficiencies, *J Hand Surg Am* 12(2):169–179, 1987; James MA, McCarroll HR Jr, Manske PR: The spectrum of radial longitudinal deficiency: a modified classification, *J Hand Surg Am* 24(6):1145–1155, 1999.

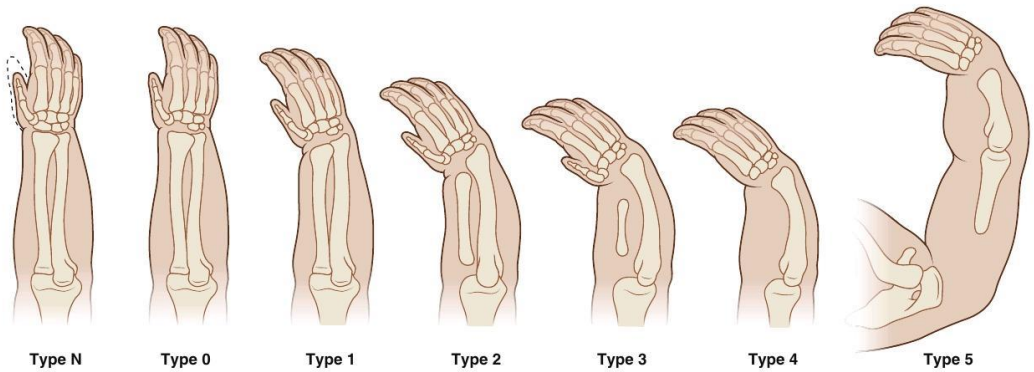

Type N Isolated thumb hypoplasia | **Type 0** Carpal anomaly | **Type 1** 2 mm shortening of distal radius | **Type 2** Hypoplastic distal radius | **Type 3** Partial absence of radius | **Type 4** Complete absence of radius | **Type 5** Absent radius and proximal humerus

Fig. 38.1 Types of radial deficiency. (Copyright © Andrea Bauer, Children's Orthopaedic Surgery Foundation.)

others prefer not to resect the carpus or shave the distal ulna because of the high rate of recurrent deformity and complications such as wrist stiffness and forearm growth impairment secondary to iatrogenic damage to the ulnar physis.

The best results of centralization are obtained when aberrant radial wrist extensors can be transferred to help maintain the new position and when the centralization is done before 1 year of age (as long as general anesthesia is not precluded by other manifestations of the child's syndrome such as cardiac problems or thrombocytopenia). Before centralization, serial casting and/or application of a distraction device facilitates stretching of the taut radial soft tissue structures. This preliminary stretching diminishes the soft tissue tension and the likelihood that bony resection will be required during centralization.[14,15] Preliminary external distraction is most helpful for older children with untreated type 3 or 4 radial deficiency. A bilobed skin flap or dorsal rotation flap may redistribute excess tissue from the ulnar to the radial side of the wrist.[16,17]

With unilateral type 3 or 4 involvement, the affected forearm is usually only half as long as the unaffected forearm. This deficit in length has been surgically addressed by ulnar lengthening via distraction

54) Pacientes com artrogripose distal tipo 3, também conhecida como _____, apresentam os seguintes achados característicos como _____

a) Síndrome de Freeman-Sheldon, Camptodactilia, Escoliose
b) Síndrome de Gordon, Camptodactilia, Escoliose
c) Síndrome de Freeman-Sheldon, baixa estatura e fenda palatina
d) Síndrome de Gordon, baixa estatura e fenda palatina

Resposta D

referência Green página 1535

TABLE 39.1 Distal Arthrogryposis Types

Distal Arthrogryposis Types	Other Name(s)	Label	Characteristic Findings
Distal arthrogryposis type 1	Common or typical	DA1	Camptodactyly, clasped thumb, clubfoot
Distal arthrogryposis type 2A	Freeman-Sheldon syndrome	DA2A	Whistling face, camptodactyly, clasped thumb, clubfoot, scoliosis
Distal arthrogryposis type 2B	Sheldon-Hall syndrome	DA2B	Prominent nasolabial folds, down-slanting palpebral fissures, small mouth, camptodactyly, clasped thumb, clubfoot
Distal arthrogryposis type 3	Gordon syndrome	DA3	Short stature, cleft palate
Distal arthrogryposis type 4	Scoliosis	DA4	Scoliosis, camptodactyly
Distal arthrogryposis type 5	Ophthalmoplegia, ptosis	DA5	Ptosis, strabismus, restrictive lung disease
Distal arthrogryposis type 6	Sensorineural hearing loss	DA6	Hearing loss, camptodactyly
Distal arthrogryposis type 7	Trismus-pseudocamptodactyly	DA7	Trismus, pseudocamptodactyly, short stature
Distal arthrogryposis type 8	Autosomal dominant multiple pterygium syndrome, Escobar syndrome	DA8	Multiple pterygia, camptodactyly, scoliosis, ptosis, down-slanting palpebral fissures
Distal arthrogryposis type 9	Beals syndrome (congenital contractural arachnodactyly)	DA9	Camptodactyly, arachnodactyly, kinked upper earlobe, tall stature
Distal arthrogryposis type 10	Congenital plantar contractures	DA10	Plantar contractures

Adapted from Bamshad M, Van Heest AE, Pleasure D: Arthrogryposis: a review and update, *J Bone Joint Surg Am* 91(Suppl 4):40–46, 2009.

Fig. 39.5 A child with amyoplasia demonstrating the characteristic facies with a hemangioma over the nasal bridge. (Courtesy of Shriners Hospitals for Children, Philadelphia, Pennsylvania.)

In very impaired children, independent feeding may be an unrealistic goal. A skilled therapist and the use of adaptive equipment may achieve independence with some daily tasks even in severely impaired children (Fig. 39.9).

Perineal care can be performed through the legs or around the back. Both require sufficient hand function to hold toilet paper firmly. Children who wipe their perineum through the legs require wrist flexion, elbow extension, and shoulder internal rotation. Children who wipe their perineum around the back require forearm supination, elbow extension, and shoulder extension.

The next priorities on the functional ladder are bathing and dressing, followed by food preparation, driving, and other activities of daily living. Recreational activities and sports participation may be achievable in mildly affected children.

Humeral External Rotation Osteotomy

Indications

Children with arthrogryposis typically present with internal rotation and adduction contractures. Elbow extension contractures can create the appearance of a pronation contracture, but most often the posture results from internal rotation at the shoulder with the forearm postured in neutral. The deltoid, rotator cuff, pectoralis, latissimus dorsi, and periscapular muscles may be weak or absent. Although rarely responsive to passive stretching, a course of therapy is recommended. Capsular releases have resulted in unpredictable results. Internal rotation contractures are best treated with a humeral external rotation osteotomy. The medial approach requires visualization and retraction of the median and ulnar nerves but is more cosmetic and provides a better bony surface for plate application than the anterolateral approach (Fig. 39.10).[7] However, the medial approach is difficult to access if the child has an adduction contracture of the shoulder. We currently prefer the anterolateral approach because the lateral arm dissection is more accessible and straightforward, and the only neurovascular structure in harm's way is the radial nerve at the distal extent of the incision. For the child with a severe elbow extension contracture, distinguishing between a shoulder internal rotation contracture and a forearm pronation contracture can be difficult. For these children, we will perform an elbow release first, followed by a humeral rotational osteotomy if needed. We routinely perform bilateral humeral rotational osteotomies in these children; however, for surgeons unfamiliar with this patient population, we recommend one side at a time.

Contraindications

Relative contraindications include (1) insufficient internal rotation for perineal care, (2) older age with established crossover grasp (see Fig. 39.10), and (3) absence of pectoralis function. Children who lack pectoralis function but retain triceps function will use an obligatory crossover grasp pattern that requires internal rotation.

55) O curativo a vácuo não deve ser usado para extremidade em casos de

a) contaminação severa
b) exsudato
c) edema
d) marsupialização da ferida

Resposta A

referência Green página 1684

Fig. 43.16 Use of vascular surgical "vessel loops" in a criss-cross fashion with staples along the wound edge to create a "corset" effect that brings the wound together without creating ischemia.

should strive to have definitive coverage by 7 to 10 days even though some smaller, noncritical wound or wounds may remain at that point.

During the period before definitive coverage, it is imperative that the wound and all vital structures remain moist. As swelling develops after injury, there is a tendency for wounds to enlarge, thus making closure progressively more difficult. We have found two techniques helpful in controlling this situation. The first involves using rubber bands or vascular surgical "vessel loops" in a criss-cross fashion with staples along the wound edge to create a "corset effect" that brings the wound together without creating ischemia (Fig. 43.16). This technique also allows a certain degree of limb swelling without creating a compartment syndrome and brings the wound edges together as the swelling diminishes.

The other method uses negative pressure therapy (NPT). NPT has a number of salutary effects, including removal of exudate, decrease in edema, closure of dead space, promotion of wound contraction, marsupialization of the wound edges, and promotion of granulation. In essence, it acts as a "mechanical myofibroblast." NPT has revolutionized the approach to soft tissue coverage in complex lower extremity defects in that it allows wounds to contract and granulate to the point where they can be covered with a simple skin graft rather than a complex flap. In the upper extremity, however, because of the importance of maintaining the gliding motion of muscles and tendons, prolonged application of NPT and skin grafting can lead to outcomes inferior to those of early coverage with a supple, vascularized flap.

NPT should never be used to unnecessarily prolong definitive upper extremity soft tissue reconstruction. Nevertheless, it does have an important role in the soft tissue reconstruction of mangled upper extremity injuries. When used judiciously and for limited periods, it can dramatically improve the wound environment and decrease the size requirements for flap coverage.[75,76] The application of NPT has evolved to the current state at which the benefit of immediate soft tissue coverage can be safely postponed. Details on the use of NPT are provided with the device, and because the device can change, the reader is referred to the manufacturer's instructions for details.

Closed NPT should not be used for extremities with severe contamination, infection, or significant bleeding. It should also be used with caution in the setting of vascular repair or reconstruction. Because NPT is a closed system, it is important to change the sponge every 3 to 5 days or more frequently, depending on the level of contamination. In some cases, if the fascial coverage of critical structures is preserved, NPT alone can obliterate dead space and produce a wound that can be skin grafted while preserving vascularized gliding tissue over critical structures (Fig. 43.17).

In planning soft tissue reconstruction, it is important to keep in mind the concept of the "reconstructive ladder" as originally described by Mathes and Nahai.[77] This concept implies that the simplest method of coverage appropriate to the situation should be used. The modified reconstructive ladder generally follows the following progression:

- Primary closure
- Wound contraction ("secondary intention")
- Skin grafting
- Flap
- Local
- Distant
- Free

Given the unique functional requirements of the upper extremity, including joint motion and tendon/muscle gliding, the simplest soft tissue reconstruction is not always the most appropriate. The decision often involves making judgments regarding the ultimate functional goals and balancing them with the complexity of the reconstruction required to achieve the goals. If the area in question has exposed "white structures" (i.e., tendon, nerve, bone, or ligament/joint), some form of a vascularized soft tissue reconstruction will be required. If, however, critical functional structures are not involved, a simpler form of reconstruction can be used. NPT should be addressed when discussing soft tissue reconstruction. Previously, there was enthusiasm for NPT as a definitive treatment for soft tissue defects in the hand and upper extremity. However, given the drawbacks to NPT (prolonged open wounds, development of intense scarring/fibrosis around the wound), we do not recommend it as a definitive treatment in and of itself. Rather, it is reasonable to use NPT in the setting of mangled upper extremity wounds, but generally as a bridge to definitive treatment.

Gottlieb and Krieger have made the point that merely using the simplest reconstruction and moving "up the ladder" when that fails is not appropriate, but rather, riding the "reconstructive *elevator*" up to the most appropriate treatment for the particular condition is what is required.[78] The essential principle is to not merely use the simplest technique possible but to use the simplest technique that will achieve optimum form and function. Do not be afraid to choose a complex reconstruction if it will provide the best result.

Whenever possible, primary closure or delayed primary closure (5 to 7 days after injury) should be performed. In doing so, it is critically important to close the wound loosely so that tension does not lead to ischemia of edges with subsequent dehiscence or ischemia of the underlying structures because of increased compartmental pressure. It is far better to have small gaps that heal secondarily than to have a large dehiscence or, even worse, to induce necrosis in marginally vascularized skin that would otherwise survive, especially in the case of traumatically elevated flaps.

In these situations, it is always best to simply lay the skin down and at most loosely suture it where it lays rather than stretch it back to its original position, thereby creating ischemia and necrosis in a large area of the flap, resulting in a defect much greater than one that would be left by simply laying the flap down (Fig. 43.18). If the wound edges cannot be closed primarily, it is certainly reasonable to allow the wound to close secondarily by wound contraction if the remaining defect is less than 1 to 2 cm and if there are no vital structures or motion areas (e.g., joints or web spaces) left exposed. Many fingertip injuries and amputations heal best with wound contraction to bring the adjacent, sensate skin together to provide coverage, as opposed to insensate grafts or flaps.

For larger noncritical defects, a skin graft may be required. Skin grafts can consist of autograft (from the patient), allograft (from a human skin bank), or xenograft (usually porcine skin). A xenograft is used primarily as a "biologic dressing" and usually does not revascularize. Allograft can revascularize and "take"; however, it will be rejected after the first week or so. It is useful in promoting vascular ingrowth into a wound bed and preparing the bed for later autografting. If an

56) Identifique as estruturas A,B,C,D na figura de pele palmar abaixo:

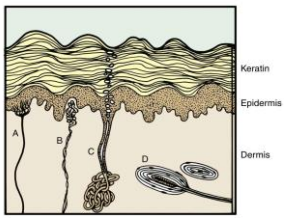

a) A - células de Meikel, B - corpúsculos de Meissner, C- glândulas sudoríparas, D - corpúsculos de Vater-Pacini
b) A - corpúsculos de Meissner, B - células de Meikel, C - glândulas sudoríparas, D - corpúsculos de Vater-Pacini
c) A - células de Meikel, B - corpúsculos de Vater-Pacini, C - glândulas sudoríparas, D - corpúsculos de Meissner
d) A - corpúsculos de Vater-Pacini, B - corpúsculos de Meissner, C - glândulas sudoríparas, D - células de Meikel

Resposta A

referência Green página 1703

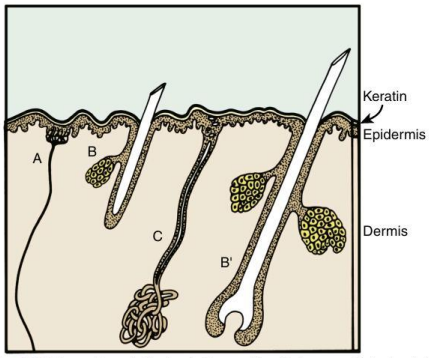

Fig. 44.1 Dorsal hand skin is similar to skin of the rest of the body in that it has hair and sebaceous glands. *A,* Merkel's cell/neurite complex. *B* and *B'*, Hair follicle and sebaceous apparatus. *C,* Sweat gland.

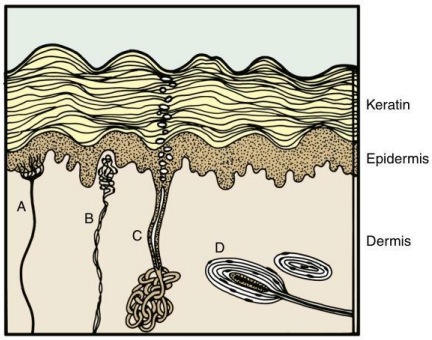

Fig. 44.2 Palmar hand skin. There are no pilosebaceous structures present. Meissner and pacinian corpuscles exist almost exclusively here. *A,* Meikel cell/neurite complex. *B,* Meissner corpuscle. *C,* Sweat gland. *D,* Vater-Pacini corpuscle.

gradual shrinking of the wound edges can be disastrous in hand wounds (Fig. 44.3). It appears that fibroblasts migrate into the base of the wound and differentiate into so-called myofibroblasts.[5] These cells have the ability to contract, and the network of these cells and collagen fibers that forms in the base of the wound is responsible for pulling the wound edges together. It has been shown that contraction can be temporarily halted by treatment of the wound with smooth muscle relaxants.[6] Once the contraction process has begun, its progression is not considerably altered by split-thickness skin grafting.[7]

In a series of experiments by Stone and Madden, wounds in animals were treated with immediate grafting, delayed grafting, and immediate and delayed grafting with splinting.[8] They concluded that immediate grafting with split-thickness skin did not significantly affect wound contraction. However, immediate grafting and splinting with a compressive dressing for 7 days did significantly inhibit wound contraction. On the other hand, delayed grafting had no effect on wound contraction no matter what adjunctive therapy was used. Splinting,

Fig. 44.3 The end result of scar contracture due to severe burn to the hand.

although effective with immediate grafting, was ineffective in preventing contraction when used with delayed grafts.

It is generally believed that the condition of the wound is the main determinant in the result of skin grafting. Even full-thickness skin grafts can be found to contract if wound contraction has already begun. Rudolph has found that the application of split-thickness skin does not seem to have as much effect on the differentiation of fibroblasts into myofibroblasts as does a full-thickness graft.[9] He has shown in animal experiments that wounds mature much more rapidly after the application of full-thickness grafts than after split-thickness grafts. The amount of actin and fibronectin found in rat wounds that were allowed to heal secondarily was compared in wounds with split-thickness grafts and those with full-thickness grafts. The thicker the graft, the less matrix protein present, which correlated well with the extent of wound contraction that occurred.[10]

This is important in considering the source of a graft for palmar wounds. The Shriners Burn Institute has compared the results of split-thickness and full-thickness grafts for coverage of deep palmar burns. Normal range of motion was found in over half of the full-thickness group, and only one-fourth needed reconstructive procedures. In contrast, normal range of motion was present in only one-fourth of the split-thickness group, and two-thirds required reconstructive procedures.[11]

Effect of Infection on Wound Healing

A great deal of bacteria is normally present on the skin. It has been estimated that about 1000 organisms per gram of tissue are normally present in hair follicles, crevices, and recesses of the skin. This number of organisms does not seem to have a negative effect on wound healing.[12] However, when contamination of the wound takes place, much higher levels are present. Surface bacteria, which can easily be removed, do not appear to be important in skin grafting if the wound is carefully prepared before surgery. On the other hand, penetration of the bed of the wound is very important.[13] It has been established that 10,000 organisms per gram of tissue is a critical level of contamination.[14] Wounds that contain fewer organisms than 10,000 organisms per gram of tissue do not commonly become infected. In a series of skin grafts applied to contaminated wounds, Krizek and colleagues[12] have shown that regardless of the technique used to prepare the bed of the wound for grafting, a bacterial count of greater than 10,000 organisms resulted in a successful skin graft take of only 19%. If the count was less than 10,000 organisms, however, there was a 94% successful take.

57) A elevação do retalho homodigital dorso radial do polegar em ilha, a pele dorsal do polegar a ser transferida é desenhado no eixo da artéria e pode ser no máximo _____e o fechamento _____

a) 3x4cm / com enxerto
b) 2x3cm / primário
c) 3x4cm / primário
d) 2x3cm / com enxerto

Resposta C

referência Green página 1851

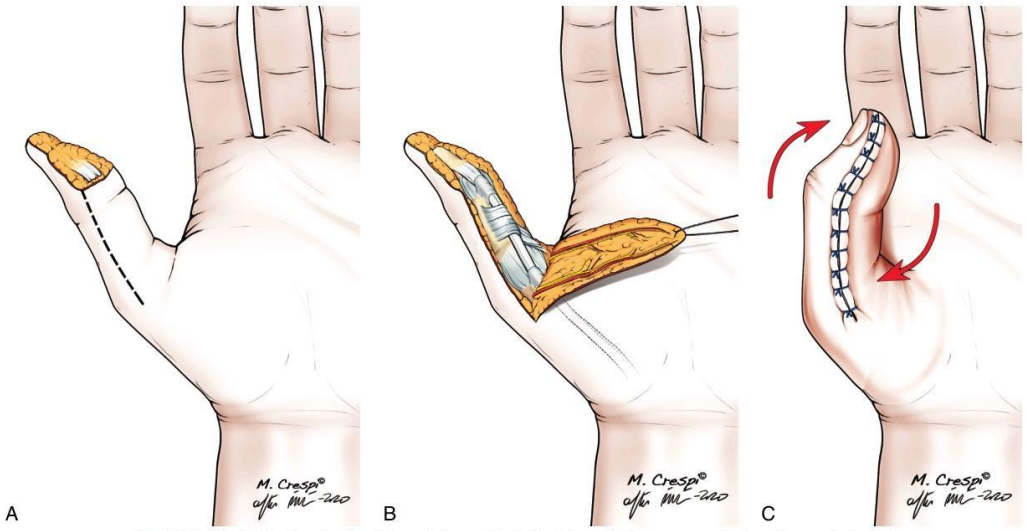

Fig. 48.3 **A** to **C,** The flap is raised through two midaxial incisions. Both neurovascular bundles are included in the flap. Some flexion contracture is permitted temporarily for closure. (Copyright © 2020, Dr. F. Piñal.)

Several variations of this flap have been presented, including an adipofascial extension to reduce donor site morbidity[17] and the possibility of carrying bone, probably in doubtful conditions.[18,19]

Irrespective of the fact that this flap represents a considerable advance in thumb coverage (Fig. 48.6), and it obviates the need for cross-finger flaps and all two-stage methods, it should, nevertheless, be used with caution. The surgeon should only raise the flap when the area of the cross anastomoses is intact, otherwise arterial failure will occur. Furthermore, the flap suffers from venous congestion if the skin over the pedicle is closed; skin-grafting is thus recommended.[13,17] In addition, because the skin at the site of the flap is elevated and is quite loose—nature provided it to permit thumb abduction—the surgeon may be tempted to close primarily excessively large donor sites. This will cause iatrogenic first web contracture and reduced MCP joint motion. Skin grafting is again recommended if large flaps are raised.[13,17]

A major drawback of this flap is the lack of sensory recovery, even when the dorsal branch of the radial nerve is connected to the ulnar digital nerve. For this reason, the flap is not recommended when there are defects involving more than 50% of the pulp. However, it may be indicated for larger defects in the elderly, where sensory recovery is frequently poor irrespective of the reconstructive option selected. For these reasons, this flap should probably only be utilized by those with experience in its application.

Dorsoradial homodigital flap. A similar flap based on the radial dorsal digital artery was described by Moschella and Cordova to solve radial and dorsal thumb defects.[14,20]

This flap's artery originates from the radial artery itself at the level of the anatomic snuffbox and passes deep to the extensor pollicis brevis tendon. It travels over the proximal phalanx at about 1 cm from the midline in the suprafascial plane. The rotation point of this flap is always the middle of the proximal phalanx. The reason for this is that it has a different arterial communicating pattern than the ulnar counterpart. Indeed, it constantly communicates with the palmar vasculature at the level of the middle third of the proximal phalanx (see Fig. 48.5), but the communication with the distal arcade is present in only about 20%.

Elevation. The skin island to be transferred is drawn on the axis of the artery. The flap can be quite large (up to 3 × 4 cm) and still achieve primary closure, as there is no risk of contracture.[20] As for the dorsoulnar flap, a sufficiently wide strip of subcutaneous tissue must be included in the pedicle. Likewise, visible larger veins should be preserved to secure adequate venous drainage of the flap.[21] Tight closure over the pedicle is to be avoided and skin grafts should be used freely. One recommendation is to add a cutaneous tail to facilitate direct skin closure after rotation of the flap.[21]

Although a branch of the radial nerve can be included and sutured, the originators did not recommend this flap for major pulp defects. Notwithstanding, the flap is a quick and safe solution for many lateral and dorsal defects of the thumb.

First dorsal metacarpal flap (kite flap). One of the most popularly employed procedures for thumb defects is the first dorsal metacarpal artery (FDMA) flap, also known as the "kite flap," described by Foucher and Braun in 1978.[22] This flap is an evolution of the innervated cross-finger flap described by Hilgenfeldt[13] and refined by Holevich.[23] The flap was devised for dorsal defects and as a vein carrier for thumb replantation. However, the fact that it can include a sensory branch from the radial nerve has made it useful for covering palmar defects, particularly in older people.[24]

The arterial supply of the flap is based on the radial dorsal artery of the index. This branch originates from the FDMA, which takes off from the radial artery between the crossing of the extensor pollicis longus and its penetration into the apex of the first interosseus space.

The radial dorsal artery of the index is constant[22] and travels on top of, or at times in, the aponeurosis of the first dorsal interosseous muscle. After providing a few branches, including one to the joint, the artery terminates supplying vascularity the dorsal skin of the proximal phalanx. There are a number of subcutaneous veins that can be

58) Ao longo de seu curso, a artéria radial dá ramos a um plexo de vasos na fáscia profunda sobrejacente, que supre a pele da superfície anterior e radiodorsal do antebraço. Da mesma forma, ramos fasciais profundos também suprem o periósteo da metade distal do rádio, entre as inserções do _____, o que permite que um segmento de osso vascularizado seja retirado do rádio até _____ da área da seção transversal do rádio, no retalho osteo cutâneo do antebraço

a) pronador redondo e braquiorradial / 10 cm de comprimento e até 30%
b) pronador quadrado e braquiorradial / 10 cm de comprimento e até 30%
c) pronador redondo e braquiorradial / 15 cm de comprimento e até 40%
d) pronador quadrado e braquiorradial / 15 cm de comprimento e até 40%

Resposta A

referência Green página 1759

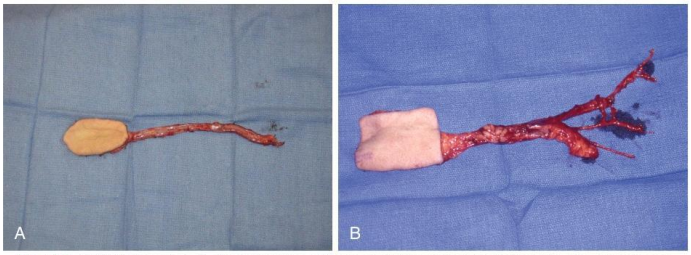

Fig. 45.6 Radial forearm flap. **A,** The thin supple skin of a small free radial forearm flap with a very long vascular pedicle of the radial artery and venae commitantes, which have been dissected all the way up to the elbow so that the microsurgical anastomoses of this free radial forearm flap can be performed much more proximal out of the zone of injury. **B,** The vascular pedicle of this free radial forearm flap has also been dissected up to the level of the elbow to incorporate the connections of the venae commitantes into the cephalic vein, so allowing a more "macro" microsurgical venous anastomosis.

The secondary defect can be closed directly if the flap is less than 6 to 8 cm wide, but otherwise a split-thickness skin graft is applied. Complications associated with the harvest of a lateral arm flap are permanent hypoesthesias in the distribution of the posterior cutaneous nerve of the forearm if it is divided and temporary radial nerve palsy. The authors have never encountered this serious problem in their practice, but it has been reported after an Esmarch bandage was used as a tourniquet or when careful monitoring of cuff pressure was not followed.[96] A study of donor-site morbidity and esthetic outcomes revealed that 90% of patients had decreased sensation after harvest of a lateral arm flap but 85% of patients would still choose a lateral arm flap again.[97]

Radial Forearm Flap

The radial forearm flap[27-29,98] certainly offers unrivaled quality of thin, mobile skin (Fig. 45.6), similar in its characteristics to the skin over the dorsum of the hand. Most dorsal and palmar defects of the hand can be covered by a pedicled reverse radial forearm flap[99] (see Chapter 44), but occasionally the size and shape of the defect may necessitate using a free radial forearm flap from the contralateral forearm (Figs. 45.7, 45.8, and 45.9) or even from the ipsilateral forearm.[26] In any of these variations, the radial forearm flap depends on the availability of good flow through the ulnar artery and the palmar arches into the digital vessels. The radial artery may occasionally be the only patent vessel to the hand when there has been a penetrating or crushing injury to the forearm or palmar surface of the hand. Even when this is not the case, the radial artery has been shown to be the dominant artery in 12% of hands. Harvesting a radial forearm flap may potentially result in acute ischemia of the hand or postoperative symptoms of cold intolerance. However, digital temperature and Doppler flow studies have shown that loss of the radial artery does not cause any significant compromise to the circulation of the hand. Therefore most surgeons no longer reconstruct the radial artery with a reversed interposition vein graft. The appearance of the donor defect, which has to be skin grafted, remains the major drawback of this flap for some surgeons.

Anatomy

The radial artery pursues a relatively superficial course down the forearm, from its origin at the bifurcation of the brachial artery to just distal to the radial styloid, where it passes deep to the abductor pollicis longus and extensor pollicis brevis tendons through the anatomic snuffbox. In the proximal forearm, it lies on the superficial surface of the pronator teres, just beneath the medial margin of the brachioradialis muscle. More distally, it comes to lie in turn on the radial head of the flexor digitorum superficialis and flexor pollicis longus muscles, where it is palpable through the skin. The artery is accompanied by two venae comitantes.

Throughout its course, the artery gives off branches to a plexus of vessels in the overlying deep fascia, which supplies the skin of the anterior and radiodorsal surfaces of the forearm. Similarly, deep fascial branches also supply the periosteum of the distal half of the radius between the insertions of the pronator teres and brachioradialis. This allows a segment of vascularized bone to be harvested from the radius up to 10 cm in length and up to 30% of the cross-sectional area of the radius as a radial forearm osteocutaneous flap.[98]

The minimal precaution that should be taken before raising a forearm flap is an Allen test to ensure that flow will be adequate through the remaining ulnar artery. Noninvasive vascular studies to determine arterial dominance are probably unnecessary.

Operative Technique

The course of the radial artery should be mapped out with a Doppler probe and marked on the skin, as should the course of the largest superficial vein in the forearm proximal to the flap.

The pattern of the defect is placed on the forearm with the marked course of the radial artery close to the radial border of the template. The radial artery should not be used as the midaxis of the flap; otherwise, if the flap extends around the radial border of the forearm, the skin-grafted defect becomes much more noticeable.[26] The flap is usually designed over the middle or distal third of the forearm. However, if the radial artery is to be used as a "flow-through" flap to reconstruct an associated arterial defect in the forearm (see Figs. 45.7 and 45.9),[68,69] the length of radial artery required proximal and distal to the flap to restore arterial inflow to the hand will predetermine the proximal-distal location of the flap on the forearm.

If pedicle length is not a consideration, the flap can be raised with its distal margin 3 to 5 cm proximal to the wrist crease. This avoids skin grafting over the more distal flexor tendons, especially the flexor carpi radialis, and the chances of the skin graft not taking over this critical area are reduced.

59) A osteomielite por tuberculose infantil é mais frequente na(o)

a) falange proximal
b) falange média
c) falange distal
d) metacarpo

Resposta A

referência Green página 119

treatment of TB of the elbow and the wrist.[229] *M. marinum* arthritis does not have as favorable a therapeutic response to chemotherapy as *M. marinum* tenosynovitis. A combination of chemotherapy and synovectomy is preferred in the treatment of *M. marinum* arthritis. Patients with involvement for more than 6 months had worse results. *M. marinum* strains are uniformly resistant to isoniazid but are sensitive to rifampin, ethambutol, and ciprofloxacin. Monotherapy with minocycline and trimethoprim-sulfamethoxazole has been effective for superficial infections, but combination chemotherapy is recommended for *M. marinum* arthritis to prevent resistance. Rifampin–ethambutol combination is the most successful in past reports. Chemotherapy for a minimum of 6 months, or for at least 2 months after complete resolution of joint infection, is recommended for all NTM joint infections.

Brashear and Winfield[230] and Tsai et al.[231] reviewed *M. tuberculosis* infections of the wrist joint. Wilson[221] and Dix-Peek et al.[222] reviewed the largest number of elbow TB. The largest numbers of deep NTM infections of the hand are reported and reviewed by Hurst et al.,[232] Chow et al.,[218] Kozin and Bishop,[206] Hellinger et al.,[18] and Zenone et al.[24] The largest number of cases of *M. marinum* joint infections of the hand have been reviewed by Alloway and colleagues.[14]

Mycobacterial Osteomyelitis

Tuberculous osteomyelitis may occur in children and adults. They are described separately here.

Etiology and epidemiology. Extrapulmonary TB accounts for almost 20% of all cases of TB in the general population and 72% of all cases in U.S. AIDS patients. In the United States, skeletal TB is 1% of all TB and 10% of all extrapulmonary TB. Of skeletal TB, approximately 50% occurs in the spine, 33% in the lower extremity (12% in pelvis, 10% in hip and femur, 10% in knee and tibia, 1% in ankle and foot), 7% in the ribs, and 10% in the upper extremity; that is, 1% in shoulder and humerus; 2% in elbow, forearm, and wrist; 4% in hand and fingers; and an additional 3% in the hand accompanied by multifocal sites elsewhere.[228,233] TB of the bones of the hand is less common than TB of the tenosynovium and joints of the hand. It typically occurs in the phalanges (i.e., tuberculous dactylitis) and metacarpals.

Diagnosis. Clinical presentation of skeletal TB of the hand in children and adults is different and has changed in character over the years based on health and immunity of the affected group.

Tuberculous osteomyelitis of children's hands. The highest incidence of skeletal TB of the hand before the era of antituberculous therapy was in infants and children. In children, two-thirds of the patients were age 2 or younger. It was uncommon after age 5 and scarce after 10 years. The natural course of the disease was often self-limiting but was accompanied by residual deformity. *M. bovis* was then the main infecting organism, and with pasteurization of milk, it is rarely reported in children today. Adult cases currently are reported more often and are caused by *M. tuberculosis* or NTM.[229] Concurrent pulmonary infection and multifocal skeletal TB was common in the past but is rare today both in children and adults.[229]

TB of phalanges (tubercular dactylitis) and metacarpals is the most common form of skeletal TB in infants and children. The proximal phalanx, middle phalanx, distal phalanx, and metacarpals are involved in that order. The second, third, and fourth fingers are involved most frequently. It is most commonly unilateral. Bilateral tuberculous dactylitis is unusual, but the clinician should not rule out TB in bilateral presentation.[234] During infancy and childhood, the short tubular bones have a lavish blood supply through a large nutrient artery entering in the middle of the bone. The agent lodges in the center of the marrow cavity, and the interior of the short tubular bone is converted into a virtual granuloma. This leads to a spindle-shaped expansion and inflated shape of the bone. Endosteal resorption of bone is followed by progressive subperiosteal hyperplasia and has been termed as *spina ventosa* (Latin *spina,* "spine"; *ventosa,* "distended with air"). Spina ventosa is a common presentation of TB of finger bones. Spina ventosa may present as a sausage finger. Of 37 cases of tuberculous dactylitis reviewed by Ritz et al., only 20% had concurrent pulmonary TB.[235] It also may follow previously treated pulmonary TB. From a clinical viewpoint, there are three types of dactylitis:

- One group consists of those individuals who have generalized tuberculous infection and tuberculous dactylitis is a manifestation of the whole.
- The second group consists of patients whose dactylitis is isolated and is the only presenting symptom and who have no evidence of generalized or multifocal tuberculous infection (see Fig. 3.36). Diagnosis is not easily made because constitutional features such as loss of weight, loss of appetite, night sweats, and evening rise of temperature, and history of close contact with a patient of TB may not be present.
- The third group consists of multifocal tuberculous dactylitis with coexistent musculoskeletal TB in additional fingers of the same hand (Fig. 3.38) and/or opposite hand, or in other parts of the same extremity or in another extremity.[236,237]

Thirty percent of children who have tuberculous dactylitis have multifocal TB. In all cases, symptoms begin with a painless, nonsuppurative, and insidious swelling on the fingers (phalangeal infection) or the hand (metacarpal infection). On examination, there is a typical fusiform swelling of a finger or a diffuse swelling on the dorsum of the hand. There is practically no tenderness or local heat, but the part may appear taut and shiny. It is not easily diagnosed at this early stage because the presentation is nonspecific and may simulate a tumor.[1,30]

Parents seek treatment only when they notice significant swelling or tenderness of fingers or hand in their children. The swelling often reaches considerable size, doubling the digital girth. In late cases, an abscess may form with skin discoloration and fluctuation. The abscess may burst and leave a sinus that drains a cheesy, yellowish exudate. Multiple discharging sinuses occur with disseminated dactylitis. Where secondary infection of a sinus occurs, the condition closely resembles a subacute osteomyelitis of pyogenic origin. Radiographs are characterized by endosteal resorption of bone and progressive subperiosteal hyperplasia.

Osteomyelitis has been reported in the carpal bones in lunate,[182] capitate,[238] scaphoid,[239,240] and scaphoid with scapholunate joint.[241] Recently a large number of TB cases in the wrist (44) have been reported by Prakash and Mehtani[182] They noted minimal initial symptoms and cited the rarity of the lesion and the ability of TB to mimic more common pathologies as factors in the delay to diagnosis. Skeletal TB behaves differently in this age compared with the adult population, as it affects the growing bone and causes residual deformities.

Metaphyseal tuberculous osteomyelitis may be the initial pathology and then the infection crosses the epiphyseal plate into the joint and there may be telltale enlargement of epiphysis. Transphyseal spread of infection is more commonly seen in tuberculous than in nontuberculous osteomyelitis. Syphilitic dactylitis has a similar radiographic appearance, but serology distinguishes the two clinically. Early in the course of a TB infection, the epiphysis is spared because of its rich blood supply, but in late cases it is invaded and causes shortening or deformity of the digit. Radiographic findings of TB in children include joint effusion, periarticular osteopenia, joint space narrowing, endosteal thinning with cortical irregularity, lytic lesions, periosteal new bone formation, and advanced epiphyseal maturity.

Diagnosis cannot be made without a biopsy. Singh et al. showed that FNAC reveals granulomas with or without necrosis in a third of

60) No paciente com tetraplegia a função principal do punho e da mão a ser obtida com tratamento cirúrgico é a

a) flexão dos dedos
b) supinação do antebraço
c) extensão do punho
d) pinça lateral

Resposta C

referência Green página 1268

strength have been identified, the patient is assigned a group number (see Table 33.3). For example, a patient with grade 4 strength of the brachioradialis (BR), both radial wrist extensors, the pronator teres (PT), and the flexor carpi radialis (FCR) would be classified as a group 5 patient. One of the difficulties in physical examination is distinguishing between group 2 and group 3 injuries. In group 2 patients, only the extensor carpi radialis longus (ECRL) has a grade 4 or higher strength, and physical examination reveals substantial radial deviation of the wrist with resisted wrist extension. In group 3 patients, both the ECRL and the extensor carpi radialis brevis (ECRB) have strength of grade 4 or higher. In a group 3 patient, the wrist extends with less radial deviation and often grade 1 to 3 strength is present in the PT, the next most caudal muscle. In thinner patients, the ECRL, a flat muscle, and the ECRB, a more bulbous muscle, can be palpated while muscle strength is being tested (Fig. 33.3).

TABLE 33.2 Muscle Grading System of the British Medical Research Council

Grade	Description
0	No contraction
1	Flicker or trace of contraction
2	Active movement with gravity eliminated
3	Active movement against gravity
4	Active movement against gravity and resistance
5	Normal power

Reproduced from *Aids to the examination of the peripheral nervous system*. London: Her Majesty's Stationery Office, 1976. With kind permission from the UK Medical Research Council.

In addition to manual muscle testing, the surgeon must also examine the passive range of motion to evaluate joint and muscle contractures along with the resting posture of the hand. The examiner can induce a tenodesis effect by passively flexing and extending the wrist while observing passive myostatic tensioning of the digital extensors and digital flexors, respectively. The hand must have passive mobility and tenodesis to achieve success. For example, if the thumb rests in a fully supinated position and lacks any tenodesis pinch during wrist extension, tendon transfers for pinch will be ineffective without skeletal stabilization (carpometacarpal [CMC] fusion) in a key pinch position.

The management of the wrist and hand in tetraplegia follows the concepts of "hierarchy of hand function" or the "reconstruction ladder." The primary fundamental movement is wrist extension, which yields tenodesis for grip as the fingers flex into the palm and tenodesis for lateral pinch as the thumb adducts against the index finger. Wrist extension also aligns the finger flexors along Blix's length-tension curve for maximum active grip. The second most essential movement is lateral pinch, which is necessary to perform numerous ADLs. Most daily activities are accomplished with lateral pinch, such as holding an object, turning a key, or using a fork (Fig. 33.4). The third essential motion is grasp, which allows the holding of objects (Fig. 33.5). The fourth and last movement is digital opening for object acquisition. The reason to place this function lowest on the ladder is that wrist flexion yields passive digital opening, which is often adequate for object procurement. In addition, synchronous digital opening is difficult to achieve via surgery as metacarpophalangeal (MCP) joint extension is mainly an extrinsic function (extensor digitorum communis, extensor indicis proprius, and extensor digiti quinti) and interphalangeal (IP) joint extension is primarily an intrinsic function (interossei and lumbricals). The only way the extrinsic system can elicit IP joint extension is by limiting MCP joint extension (e.g., Zancolli tenodesis of the flexor

TABLE 33.3 International Classification for Surgery of the Hand in Tetraplegia (ICSHT)[a]

Group	Sensibility[c]	Spinal Cord Segment	Key Muscle Below the Elbow Function	Motor Description
0	O or Cu	≥C5	None	Elbow flexion and forearm supination
1	O or Cu	C5	+ Brachioradialis	Elbow flexion with some supination/pronation[b]
2	O or Cu	C6	+ Extensor carpi radialis longus	Wrist extension
3	O or Cu	C7	+ Extensor carpi radialis brevis	Strong wrist extension
4	O or Cu	C7	+ Pronator teres	Forearm pronation
5	O or Cu	C7	+ Flexor carpi radialis	Wrist flexion
6	O or Cu	C7	+ Extensor digitorum communis	Finger extension (metacarpophalangeal joints)
7	O or Cu	C7	+ Extensor pollicis longus	Thumb extension
8	O or Cu	C7	+ Partial digital flexors	Incomplete finger flexion
9	O or Cu	C8	Lacks only intrinsics	Complete digital roll-up
X	O or Cu		Exceptions	Variable

[a]Developed at the First International Conference on Surgical Rehabilitation in the Upper Limb in Tetraplegia, Edinburgh, Scotland, 1978, and modified at the Second International Conference, Giens, France, 1984. This classification does not include the shoulder; it is a guide to the forearm and hand only. Determination of patient suitability for posterior deltoid to triceps transfer or biceps to triceps transfer is considered separately.
[b]The brachioradialis muscle can supinate and pronate to the neutral position.
[c]Afferent input, both ocular (O) and cutaneous (Cu), is recorded using the method described by Moberg. When vision is the only afferent available, the designation is "O." Assuming there is 10-mm two-point discrimination or less in the thumb and index finger, the correct classification is "Cu," indicating that the patient has adequate cutaneous sensibility. If two-point discrimination is more than 10 mm (i.e., inadequate cutaneous sensibility), the correct designation is "O." The sensibility designation precedes the motor group (e.g., O2).
Modified from McDowell CL, Moberg EA, House JH: The second international conference on surgical rehabilitation of the upper limb in tetraplegia (quadriplegia), *J Hand Surg Am* 11:604–608, 1986; data from Moberg EA, McDowell CL, House JH: Third international conference on surgical rehabilitation of the upper limb in tetraplegia (quadriplegia), *J Hand Surg Am* 14(6):1064–1066, 1989.

61) Na paralisia obstétrica é sinal de lesão por avulsão:

a) Sinal do corneteiro
b) Incapacidade de fletir os dedos após 6 meses de vida
c) Paralisia do trapézio
d) Escápula alada

Resposta D

referência Green página 1563

TABLE 40.1 Indicators of Avulsion Injuries and Poor Prognosis for Recovery

Finding	Implication
Paraspinal muscle injury	Dorsal rami injury
Rhomboid injury	Dorsal scapular nerve (C5)
Scapular winging	Long thoracic (C5, C7, C8) injury
Horner's syndrome	Cervicothoracic sympathetic injury
Hemidiaphragm paralysis	Phrenic nerve injury
Pseudomeningocele	Dura and arachnoid avulsion injury

For prognostic reasons, it is important to determine whether the level of injury is preganglionic or postganglionic (see Fig. 40.2). Because of the proximity of the dorsal root ganglion to the spinal cord and the fact that the motor cell body is in the spinal cord, preganglionic lesions are avulsions from the cord that will not spontaneously recover. By assessing the function of several nerves that arise close to the midline and the ganglion, one can frequently determine the level of the lesion by physical examination (Table 40.1). Specifically, the presence of an elevated hemidiaphragm (phrenic nerve, C5 nerve root), the absence of rhomboid major and minor (dorsal scapular nerve, C5 nerve root), a winged scapula (long thoracic nerve, C5-7 nerve roots), and the presence of a Horner syndrome (sympathetic chain, T1 nerve root) all raise concern about a preganglionic lesion.

Preganglionic lesions can be reconstructed only by nerve transfers,[51] most commonly with the thoracic intercostal nerves,[52-54] a branch of the spinal accessory nerve,[55] contralateral C7 nerve root transfers,[56] or partial peripheral nerve transfers. Postganglionic ruptures have reconstructible proximal and distal nerves beyond the zone of injury. Thus a postganglionic injury is a complex peripheral nerve lesion that can be reconstructed with intercalary nerve grafts. Peripheral nerve transfers can also be used to reconstruct these injuries. However, functional spontaneous recovery is also possible in postganglionic injuries, likely due to partial ruptures and redundant innervation pathways present at birth.[57] Narakas group I and those in Narakas II with complete biceps recovery by 4 months have a high likelihood of full function. Infants in groups III and IV are unlikely to achieve full function without surgical intervention.[58]

The majority of BPBIs involve the upper trunk.[59] The classic Erb palsy involves C5-6 (46%). The next most common injury (an extended upper trunk lesion or extended Erb's palsy) involves C5-7 (29%). With these injury patterns, the injury is most frequently postganglionic. When the lower plexus is involved, preganglionic avulsions of C8-T1 are most common, with additional avulsion of C7 often present. The exception to this situation is an upper trunk lesion seen with a breech delivery. These nerve injuries tend to be preganglionic C5-6 avulsions from the spinal cord[25] and are more commonly bilateral in presentation compared with vertex deliveries.

Most authors use the timing of specific motor function recovery and the absence of recovery as an indication for surgical intervention.[11,59] Wyeth and Sharpe in 1917 advised surgical intervention if no recovery was seen by 3 months of life.[60] Gilbert and Tassin concurred with the 3-month time interval and used recovery of antigravity biceps function as the key indicator of spontaneous recovery of the brachial plexus.[1] Waters similarly found biceps recovery to be statistically reliable.[3] Laurent and colleagues advised monitoring biceps, triceps, and deltoid function.[10]

Clarke and associates described the timing of return of elbow flexion and elbow, wrist, finger, and thumb extension as discriminators of outcome and used a combined threshold score of motor recovery of these muscles as an indication for nerve surgery.[61,62] Ultimately, Clarke advised that recovery at 9 months be assessed with a "cookie test" (i.e., inability to bring a cookie to the mouth with the arm at the side) to predict outcome and determine the need for microsurgical intervention in difficult cases with mixed recovery.

Grading recovery of specific muscles in an infant is difficult. Many centers use the Medical Research Council (MRC) muscle grading system to define results. The schema classifies muscle strength as 0 (no contraction), 1 (trace contraction), 2 (active motion with gravity eliminated), 3 (active motion against gravity), 4 (active motion against gravity and resistance), and 5 (normal power). However, this system requires volitional contraction and participation, which is not feasible in an infant and difficult in a young child. Understanding these difficulties, Gilbert and Tassin modified the MRC grading system to a four-grade classification using 0 (no contraction), 1 (contraction without movement), 2 (movement with gravity eliminated), and 3 (complete movement against the corresponding weight of the extremity).[1]

The modified Mallet classification (Fig. 40.4) provides a more global motor functional assessment of the upper trunk as opposed to isolated muscle testing.[63] This global shoulder motion system assesses hand-to-mouth, hand-to-neck, hand-to-spine, and hand-to-belly activities on a scale of 1 to 5. A sixth category of "internal rotation" has been added to better balance the Mallet classification with regard to external and internal rotation.[64] A score of 1 is no function, 5 is normal function, and grades 2 to 4 denote progressive improved strength, as shown in Fig. 40.4. The majority of late 20th century papers on infantile brachial plexus have used these classification schemes to determine the results of spontaneous recovery and surgical intervention.

More recently, Clarke and coworkers advocated use of the Hospital for Sick Children Active Movement Scale (AMS) (Table 40.2), a grading system that divides muscle strength into movement with gravity eliminated (grades 0 to 4) and movement against gravity (grades 5 to 7).[65] This system requires that full active motion with gravity eliminated to occur (grade 4) within the available range of passive motion before scoring antigravity muscle strength (5 to 7). The Toronto Test Score,[66] a similar grading of specific muscle functions at the elbow, wrist, and hand, is used only in infancy to predict the need for surgical nerve reconstruction, and it is not designed to track progressive recovery over time (Table 40.3). Thus no scoring system is without limitations.

The Mallet,[67] Toronto Test Score,[36] and AMS are statistically reliable in terms of interobserver and intraobserver analyses.[68,69] As might be expected, intraobserver reliability is better than interobserver, and less-complicated systems (Mallet) have higher reliability than more complicated schemes (AMS). The Pediatric Outcomes Data Collection Instrument (PODCI), which assesses parent and patient-reported function, has also been shown to be a reliable tool for measuring baseline function in children with chronic brachial plexus injuries against normative per age data, as well as for assessing postoperative changes in these children.[68,70] However, parent reports of their child's function can be confounded by litigation against the delivery team,[71] as this injury carries with it a strong emotional component that affects perceptions of function. This information is critical for comparing results and for assessing multicenter studies of therapeutic interventions for BPBI.

Recently the recognition that objective measurements and legacy measures may not correlate with enhanced function has resulted in a paradigm shift in outcome assessments. The initiative toward patient- or caregiver-reported outcomes has resulted in the development of reliable subjective measures. For children with brachial plexus injury, Shriners Hospitals for Children has developed patient-reported outcomes using the computer adaptive test (CAT) approach.[72,73] This methodology has been shown to correlate with legacy measures,

62) Na oponentoplastia idealizada por Buckhalter para as lesões altas do nervo mediano utilizamos o tendão

a) Extensor do quinto dedo
b) Extensor próprio do indicador
c) Abdutor curto do polegar
d) Palmar longo

Resposta B

referência Green página 1196

Surgical techniques. *Royle-Thompson opponensplasty.* With this technique, a 3-cm longitudinal incision is made at the base of the palm on the radial border of the hypothenar eminence.[33,34] The ulnar border of the palmar aponeurosis is exposed and retracted radially, and the ring finger superficialis tendon is identified as it emerges from the carpal tunnel proximal to the superficial palmar arch. This tendon is then divided distally through a transverse incision at the base of the digit and delivered into the palmar wound so that it passes ulnar to the palmar aponeurosis. A third incision is made over the dorsum of the thumb MCP joint, and a wide subcutaneous tunnel is created between this and the palmar incision. The superficialis tendon is passed through this tunnel, with the angle created by the distal edge of the flexor retinaculum and the ulnar border of the palmar aponeurosis acting as the pulley. The transfer is then attached to the thumb by one of the many insertion techniques. Although Thompson originally used a dual insertion that stabilized the thumb MCP joint, he subsequently used the APB insertion.[51]

The tourniquet is released and hemostasis is obtained before the incisions in the palm and at the base of the ring finger are closed. The superficialis transfer attachment to the thumb is then sutured while the thumb is held in full opposition. Because the ring finger superficialis tendon has a significant potential for excursion and crosses the wrist joint, adjusting the tension is not as critical as with other transfers, and there is a considerable margin for error. However, the transfer's tension should be adjusted so that it is tight when the thumb is fully opposed and the wrist is in neutral. Postoperatively, Thompson held the thumb in opposition for 4 to 6 weeks with spiral adhesive strapping that allowed some active thumb movement; in addition, Rath advocated early mobilization of this transfer.[64] However, most surgeons immobilize the thumb in full opposition with a cast for several weeks.

RESULTS. Some surgeons believe that this opponensplasty does not produce as wide a thumb abduction as some other transfers because it runs along the path of the superficial head of the FPB and not that of the APB muscle. However, the results were excellent or good in 8 of Thompson's 10 original opponensplasties,[33] and a subsequent report described excellent or good results in 78% of 94 opponensplasties.[51]

Bunnell's opponensplasty. Bunnell's precept for restoration of full thumb opposition was that the transfer should run in line with the fibers of the APB to an insertion on the dorsoulnar aspect of the thumb proximal phalanx. Because his transfer passes distal to the axis of rotation of the MCP joint, it also flexes that joint.

TECHNIQUE. The ring finger superficialis tendon is divided at the base of this digit by using one of the previously described techniques. An incision is then made over the ulnar neurovascular bundle, just proximal to the wrist crease, and the ring finger superficialis tendon is identified. The distal portion of the FCU tendon is then exposed and cut halfway across, 4 cm proximal to its insertion on the pisiform. The tendon is then split into two equal halves up to its pisiform insertion, thus creating a distally based strip of tendon tissue. The free end of this tendon slip is sutured back onto its base at the pisiform to create a fixed pulley through which the superficialis tendon can pass easily. Care should be taken to not make this loop too tight. An incision is then made on the dorsum of the thumb, and a wide subcutaneous tunnel is created across the palm between the two incisions. A hole large enough to accommodate the superficialis tendon is then drilled from the dorsoulnar cortex to the radial cortex of the base of the proximal phalanx. The ring finger superficialis is delivered into the wrist incision and passed through the pulley and then along the subcutaneous tunnel into the dorsal thumb incision.

Next, the tourniquet is released, hemostasis is achieved, and the skin incisions at the base of the ring finger and at the wrist are closed. The superficialis tendon is then passed superficial to the EPL tendon across the dorsum of the thumb MCP joint. It is then passed through the drilled hole in the base of the proximal phalanx in a dorsoulnar-to-radiopalmar direction. Once the tendon has been passed through the drill hole, the transfer's tension is set so that the thumb lies in full opposition with the wrist in neutral. The transfer is then sutured back onto itself or to the radial border periosteum. Alternatively, it can be held with a pull-out suture tied over a dental roll or attached to the proximal phalanx with suture anchors.

RESULTS. Jensen used the Bunnell opponensplasty and reported good opposition in 22 of his 27 superficialis transfers.[24]

EIP opponensplasty. The EIP opponensplasty was favored by Burkhalter, who wrote earlier editions of this chapter, and is popular in high median nerve palsy and other instances when the ring and middle finger FDS tendons are unavailable. It has become increasingly preferable to the superficialis transfer in low median nerve palsies because it does not weaken grip and causes little, if any, functional disability.[45]

Technique. A short incision is made over the index finger MCP joint, and the EIP tendon is identified lying deep and ulnar to the index EDC. It can be divided immediately proximal to the extensor hood, but the tendon is then only just long enough to reach the APB insertion on the thumb. As a result some surgeons, myself included, recommend that a 1- to 2-cm contiguous slip of the extensor hood is harvested with the tendon to lengthen the transfer (Fig. 31.3A).[45] This makes the attachment of the transfer to the ADM insertion much easier but requires careful repair of the extensor hood, as otherwise its radial and ulnar halves may subluxate palmarly and cause an extensor lag.[65] An incision is then made on the dorsoulnar aspect of the distal forearm and the deep fascia on the ulnar border of the extensor compartment is widely released to expose the finger extensor tendons proximal to the extensor retinaculum. The EIP muscle and tendon lie deep and ulnar to the EDC tendons and are identified by pulling on the distal end of the EIP tendon on the back of the hand (see Fig. 31.3B). The whole EIP tendon is pulled down from the back of the hand into the forearm wound, which is sometimes only possible after soft tissue connections between the extensor indicis and index communis tendons have been divided through a small incision on the back of the hand. The EIP muscle is then freed of soft tissue attachments in the distal third of the forearm (see Fig. 31.3C).

Next, the path of the transfer is planned and marked (see Fig. 31.3D), and small incisions are made in the pisiform area on the ulnar border of the wrist and on the dorsoradial aspect of the thumb MCP. A wide subcutaneous tunnel is then developed from the extensor surface of the forearm to the thumb incision, passing around the ulnar border of the wrist and across the palm (see Fig. 31.3E). The extensor indicis tendon is passed through this tunnel, running superficial to the EDC and FCU tendons (see Fig. 31.3F). *Inadvertently passing it beneath the FCU tendon may later result in compression of the ulnar nerve.* The tourniquet is then released and hemostasis obtained before the forearm and index finger incisions are closed. The distal attachment of this transfer depends on the clinical setting. In isolated median nerve palsies, it is simply attached to the APB tendon with the wrist in 30 degrees of flexion and the thumb in maximum opposition. My preference is to attach the transfer with a Pulvertaft weave (see Fig. 31.3G).

In combined median and ulnar nerve palsies with an intrinsic-minus thumb, the transfer may be attached in sequence to the APB tendon, the MCP joint capsule, and the EPL tendon over the proximal phalanx, as described by Riordan.[46] The transferred tendon can reach this new origin if the thumb is fully opposed and the wrist is flexed. This attachment restricts IP joint flexion and thus allows the FPL to flex the MCP joint more effectively and substitute for the paralyzed FPB.[45] Alternatively, a split FPL tendon transfer can be performed to achieve

63) Em relação aos retalhos venosos:

a) são uma boa indicação para as lesões extensas
b) podem ser inervados
c) quando arterializados têm melhor taxa de sobrevivência
d) são considerados retalhos de fluxo invertido

Resposta C

referência Green página 1748

TABLE 45.1 Common Free Flap Donor Sites

Classification	Flap	Artery	Composite Tissues	References
Cutaneous				
	Dorsalis pedis	Anterior tibial–dorsalis pedis artery	Bone: second metatarsal Tendon: extensor tendons Sensory: superficial peroneal nerve	McCraw, 1977[16]; Ohmori, 1976[58]; Robinson, 1976[17]; Zuker, 1986[18]
	Groin	Superficial circumflex iliac artery Deep circumflex iliac artery	Bone: iliac crest	Chuang, 1992[19]; Harii, 1975[20]; Hough, 2004[7]; Smith, 1972[108]
	Scapular	Transverse branch of circumflex scapular artery		Dabernig, 2007[48]; Gilbert, 1982[104]; Hamilton, 1982[105]
	Parascapular	Descending branch of circumflex scapular artery	Bone: lateral border of scapula	Burns, 1986[133]; Nassif, 1982[106]; Swartz, 1986[107]
	Anterolateral thigh	Descending branch of lateral circumflex femoral artery	Sensory: lateral cutaneous nerve of thigh	Baek, 1983[110]; Javaid, 2003[114]; Koshima, 2003[51]; Song, 1984[111]; Wang, 2005[115]; Wei, 2002[112]
	First web space/toe pulp	Dorsalis pedis artery/first dorsal metatarsal artery	Sensory: fibular digital nerve to great toe; tibial digital nerve to second toe; deep peroneal nerve	Buncke, 1979[126]; Gu, 2014[127]; Koshima, 2000[128]; Lin, 2007[129]; May, 1977[21]; Morrison, 1978[22]
Fascial/fasciocutaneous	Radial forearm	Radial artery	Bone: radius Tendon: palmaris longus	Bardsley, 1990[101]; Hentz, 1987[25]; Jones, 2008[26]; Muhlbauer, 1982[27]; Partecke, 1984[69]; Song, 1982[28]; Timmons, 1986[102]
			Sensory: medial and lateral antebrachial cutaneous nerves	
	Ulnar forearm	Ulnar artery	Sensory: medial and lateral antebrachial cutaneous nerves	Christie, 1994[30]
	Posterior interosseous	Posterior interosseous artery		Chen, 1996[135]; Shibata, 1997[136]
	Lateral arm	Posterior radial collateral artery	Bone: humerus	Katsaros, 1984[31]; Katsaros, 1991[32]; Ulusal, 2007[33]; Yousif, 1990[34]
			Tendon: triceps	
			Sensory: posterior cutaneous nerve of arm	
	Fibular osteocutaneous	Peroneal artery	Bone: fibula	Wei, 1986[57]
	Medial plantar	Medial plantar artery		Morrison, 1983[137]; Ninkovic, 1996[138]
	Temporoparietal	Superficial temporal artery		Hing, 1988[124]; Hirase, 1994[125]; Upton, 1986[39]
Musculocutaneous	Gracilis	Medial circumflex femoral artery		Jones, 1990[45]
	Latissimus dorsi	Thoracodorsal artery		Chen, 2004[47]; Godina, 1987[122]; Gordon, 1982[40]; Lee, 2008[53]
	Rectus abdominis	Deep inferior epigastric artery		Pennington, 1980[42]; Press, 1990[43]; Rao, 1994[44]; Taylor, 1984[123]
	Serratus anterior	Thoracodorsal artery	Bone: rib	Brody, 1990[41]; Harii; 1982[120]
Omentum	Right gastroepiploic artery			Iglesias, 2014[131]; Seitz, 2009[132]

Venous Flaps

Venous flaps[62-65] and *arterialized venous flaps*[66] have provoked sporadic interest during the past decade. In a pure venous perfusion flap, a small flap of skin and subcutaneous tissue containing a superficial vein that projects a few millimeters both proximally and distally beyond the flap is harvested from the flexor surface of the distal forearm. The flap is then reversed and can be used for simultaneous coverage of a defect over the dorsal aspect of the fingers or hand as well as for restoration of venous outflow by anastomosis of both the proximal and distal ends of the vein to a vein proximal and distal to the defect.[62-65]

There are two types of arterialized venous flaps.[66] In the first type, the flap inflow vein is anastomosed to a digital artery and the outflow vein is anastomosed to a vein proximal to the defect, in essence creating an arteriovenous fistula. The second type of arterialized venous flap can be used for simultaneous coverage of a defect over the palmar surface of a digit as well as for restoration of a segmental defect in a digital artery, by anastomosis of both the proximal and distal ends of the vein to the digital artery to create a *flow-through flap.* Clinically, arterialized venous flaps have better survival rates than pure venous perfusion flaps. The largest successfully surviving venous perfusion flap measured

64) O cisto sinovial volar normalmente se encontra

a) sobre o tubérculo do escafóide
b) entre o escafóide e o semilunar
c) entre o escafóide e o trapézio
d) entre o rádio e o semilunar

Resposta A

referência Green página 2201

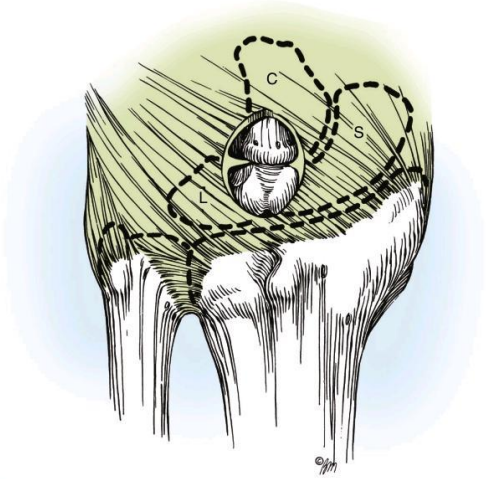

Fig. 59.23 Completed excision of all attachments to the scapholunate (SL) ligament and the immediate vicinity. Synovial tissue between the ligament and the head of the capitate *(C)* has also been excised. Note that the SLs remain intact. *L,* Lunate; *S,* scaphoid. (Copyright © Elizabeth Martin.)

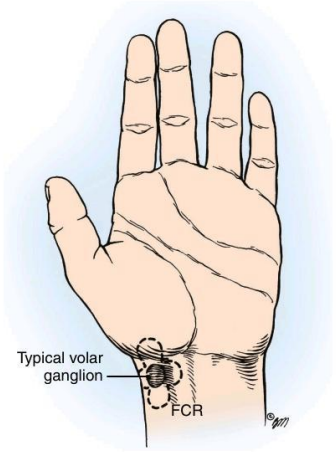

Fig. 59.24 Typical location of a volar wrist ganglion. Possible subcutaneous extensions *(dashed lines)* are often palpable. *FCR,* Flexor carpi radialis. (Copyright © Elizabeth Martin.)

be avoided by early motion, physical therapy if necessary, and splinting of the wrist in slight flexion during the immediate postoperative period. It is imperative that early volar flexion be stressed. To avoid keloid or hypertrophic scars, longitudinal incisions across the wrist joint should be avoided. Awareness and respect for the sensory branches of the radial and ulnar nerves prevent neuroma formation, which often defies effective treatment. I have not seen avascular necrosis of either the lunate or scaphoid or scapholunate dissociation after the surgical technique just described.[23] Ganglions and sprains of the intercarpal ligaments can occur concomitantly after trauma to the wrist and must be distinguished preoperatively. Identification of concomitant wrist pathology may be facilitated with arthroscopic treatment.

Occult Dorsal Carpal Ganglion

Unlike protruding dorsal ganglions, smaller, occult dorsal ganglions are easily overlooked and can often only be palpated with the involved wrist in marked volar flexion. Comparison with the opposite normal wrist is helpful. An occult ganglion may be the cause of unexplained wrist pain and is disproportionately tender. MRI is useful in confirming the diagnosis and differentiating pain related to scapholunate ligament injury. Dorsal ganglions occasionally do occur in association with an underlying scapholunate diastasis, and they may be blamed for the carpal instability after their excision.

Dorsal prominence of the proximal pole of the scaphoid secondary to intercarpal instability may be confused with a painful occult ganglion and must be diagnosed with appropriate radiographic studies to avoid a delay in proper treatment. Excising the ganglion alone might not alleviate all the patient's preoperative pain. Excision of the posterior interosseous nerve at the level of the radiocarpal joint may help alleviate the pain and add to the patient's postoperative comfort. If other causes of wrist pain and tenderness, especially directly over the scapholunate ligament, can be excluded, an occult dorsal ganglion is best initially treated conservatively by immobilization and steroid injections directly into the dorsal capsule, which can also aid in diagnosis.

In cases in which further diagnostic studies are necessary, some authors have found the use of MRI and ultrasonography helpful.[34] Chronic tenosynovitis of the extensor tendons can be confused with a dorsal wrist ganglion but can be easily distinguished by the diffuse nature of the swelling and the puckering seen with digital extension, the so-called tuck sign.

Volar Wrist Ganglion

Clinical characteristics. The second most common ganglion of the hand and wrist is a volar wrist ganglion (18% to 20%). The majority of volar ganglions occur either directly over the distal edge of the radius or slightly more distally over the scaphoid tubercle. The former arises from the capsular and ligamentous fibers of the radiocarpal joint and occurs under the volar wrist crease between the flexor carpi radialis and abductor pollicis longus tendons (Fig. 59.24). The main cyst may be intertwined with bifurcating branches of the radial artery, thus making delicate dissection imperative. The other type of volar ganglion arises from the capsule of the scaphotrapezial joint.

Although volar ganglions may appear small clinically, they can be surprisingly extensive at surgery. Multiloculated cysts extending under the thenar muscles, along the flexor carpi radialis tendon, into the carpal canal, and under the first extensor compartment adjacent to the dorsal branch of the radial artery and as far dorsally as the first web space may be encountered. These extensions can often be appreciated preoperatively by careful palpation and digital compression of the ganglion.

It is important to assess the patency of the radial and ulnar arteries. The Allen test should be performed routinely and ulnar artery occlusion excluded. The surgeon must be aware of the importance of preserving the radial artery, particularly in patients with a radial-dominant circulation.

AUTHORS' PREFERRED METHOD OF TREATMENT: VOLAR WRIST GANGLION

Operative technique. Although the surgical technique of excision of a volar ganglion is similar to that for a dorsal ganglion, exposure and precise identification of the capsular attachments of

65) No tratamento cirúrgico do dedo em gatilho, o nervo digital com maior risco de lesão é o nervo digital

a) ulnar do polegar
b) radial do polegar
c) radial do index
d) ulnar do quinto dedo

Resposta B

referência Green página 2109

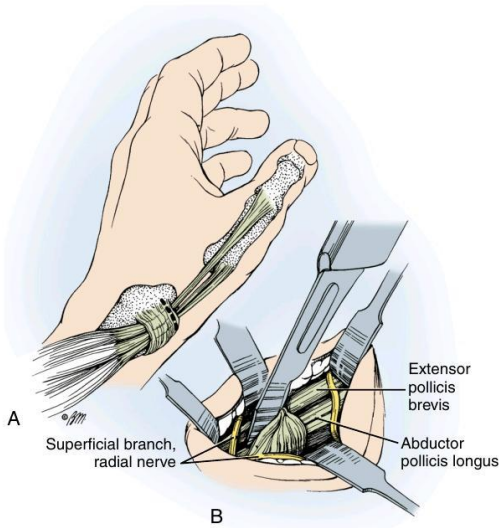

Fig. 56.5 Release for de Quervain disease. **A,** The first dorsal compartment is approached by a short transverse skin incision. **B,** The annular ligament is incised with a scalpel from the snuffbox to the musculotendinous junctions. (**A** and **B,** Copyright © Elizabeth Martin.)

Persistence of trigger digit after division of the A1 pulley can occur due to enlargement of the flexor tendon with stenosis at the level of the A2 pulley, especially in patients with long-standing trigger digits.[77] Although some authors have advocated combined release of the A1 and A2 pulleys for primary trigger release,[78] most authorities have recommended reduction in the volume of the flexor tendons as the solution for persistent triggering. Seradge and Kleinert described "flexor reduction tenoplasty," with excision and sutured closure of bulbous enlargement of the FDP tendon.[77] Others have advocated resection of the ulnar slip of the FDS tendon[79] or the entire FDS tendon.[80]

Infection. Infection after trigger digit surgery is low in most series. Ng et al. retrospectively evaluated 780 patients with 999 digits and noted 26 patients with infection (3%), which included stitch abscesses as well as superficial and deep infections. Risk factors include shorter time between corticosteroid injection and surgery, tobacco use, use of epinephrine in the local anesthetic, and use of antibiotics.[81] Others have noted similar risk with regard to close timing of corticosteroid injection, with findings of greater incidence of deep infection in those receiving steroid injections within 90 days of surgery.[82]

Stiffness or contracture. PIP joint stiffness or contracture is often present upon initial presentation in long-standing cases of trigger digit.[17] This contracture is theorized to occur due to pathologic changes or shortening of the FDS tendon.[83] Preoperative flexion contracture is significantly correlated with higher risk of postoperative contracture,[84] and the patient should be made aware of this risk prior to surgery. Yang et al. described the addition of finger splinting after percutaneous A1 pulley release in a comparative study in 65 patients with PIP contractures and noted significantly improved PIP joint extension in the splinted group.[85] Favre and Kinnen resected the FDS in 39 digits with PIP contracture in combination with A1 pulley release and noted that 72% achieved full extension after surgery.[80]

Nerve injury. Iatrogenic digital nerve injuries are rare.[64,86] The radial digital nerve of the thumb is at higher risk because of its superficial location,[86] as close as 1.29-mm deep to the dermis, and oblique course at the level of the MCP joint.[87] Nerve injuries have also been described in other digits. Sreedharan et al. described a case of a neuroma of the radial digital nerve to the middle finger, which was treated with excision and primary nerve repair.[88]

Adult trigger digits are distinct from pediatric trigger digits and congenital trigger thumb. There are important differences between trigger digits in children and those in adults, including trigger thumbs. Congenital or developmental trigger thumb presents in early childhood with a thumb interphalangeal (IP) joint in fixed flexion, with a palpable nodule at the MCP joint crease characterized as Notta's nodule.[89] These are treated either with passive stretching,[90] splinting,[91] or surgical release of the A1 pulley.[89] This entity will be addressed in detail in Chapter 37.

In addition, pediatric trigger digits other than the thumb are notable for underlying anatomic abnormalities or conditions. Specifically, aberrant lumbrical muscles or decussation of the FDS tendon proximal to the A1 pulley have been described.[92] Trigger digits are associated with juvenile rheumatoid arthritis, mucopolysaccharidosis, and Ehlers-Danlos syndrome.[93,94]

De Quervain Tenosynovitis

De Quervain tendinopathy is defined as tenosynovitis of the first dorsal extensor compartment tendons (the abductor pollicis longus [APL] and extensor pollicis brevis [EPB]), as they pass through the fibroosseous sheath at the wrist joint[95] (Fig. 56.5). Similar to trigger digits and other tendinopathies, inflammatory cells are absent in histopathological specimens, which show thickening of the tendon sheath and mucopolysaccharide deposition.[96] Although de Quervain, a Swiss physician, receives the eponymous credit for the condition from his report of five cases in 1912,[97] a surgeon from St. Louis published about this condition in 1898.[98]

Anatomy

The first dorsal compartment tendons cross the wrist at the radial styloid, under a retinacular sheath with a mean length of 21.2 mm.[99] In patients with first dorsal compartment tenosynovitis, the retinacular sheath is nearly three times thicker, based on ultrasound-guided studies.[100] Finkelstein was the first to report septation of the compartment in 3 of 24 patients with de Quervain tenosynovitis.[101] Jackson et al. noted that the most common anatomic pattern of tendon anatomy was composed of two APL tendon slips and one EPB slip in the first dorsal compartment.[102] A septum between the APL and EPB tendons was seen in 40% of cadaveric wrists. Studies have shown a high incidence of subcompartmental septae in patients undergoing surgery for de Quervain tendinopathy.[103]

Risk Factors

Risk factors for de Quervain tendinopathy include female sex and increased age.[104,105] A study in a working population showed a significantly increased risk from repeated or sustained wrist bending activities and twisting motions.[105] De Quervain has also been described during pregnancy[106] and in the postpartum period.[107] A recent study of factors associated with surgery for de Quervain in a population of 200 patients showed that Medicaid insurance status and psychiatric illness history correlated with surgical treatment.[108]

Clinical Presentation

Patients present with wrist pain, localized to the dorsoradial side of the wrist, and sometimes complain of triggering of the extensor tendons.[109]

66) O estabilizador primário da articulação CMC (carpometacarpal) do polegar é o ligamento oblíquo

a) anterior superficial
b) posterior superficial
c) anterior profundo
d) posterior profundo

Resposta C

referência Green página 423

Fig. 11.15 Robert's true PA radiograph of the thumb carpometacarpal (CMC) joint of a 52-year-old female with stage III CMC osteoarthritis.

chuck pinch test using a dynamometer, may be helpful when absolute values are compared with those of the contralateral side (Video 11.3). Pinch maneuvers such as the two-point or lateral pinch test may increase forces across the CMC joint by a factor of 12. The examiner should be aware that the association of carpal tunnel syndrome with CMC osteoarthritis approaches 30%.

Diagnostic Imaging

Radiographs to profile the thumb CMC joint include PA, lateral, and oblique views of the hand or, alternatively, PA and lateral views of the wrist. A Robert view of the thumb CMC joint is also helpful because it is a true PA view of the joint (Fig. 11.15). The Robert view requires special positioning of the arm and hand that some patients may find difficult, especially if they have limited or painful motion of the shoulder. The Robert view is obtained with the arm and hand in a combination of positions, including shoulder flexion, shoulder internal rotation, and wrist hyperpronation, so that the dorsal surface of the thumb can be placed directly on the radiograph cassette. Advanced imaging studies such as MRI or CT scanning are seldom necessary for operative procedures or surgical decision making about the thumb CMC joint.

Eaton and colleagues have described a widely accepted radiographic staging system for thumb CMC joint degenerative arthritis[94]:

Stage I: Normal or slight widening of the joint shadow due to synovitis

Stage II: Mild joint shadow narrowing with osteophyte formation of 2 mm or less

Stage III: Marked joint shadow narrowing with osteophyte formation of more than 2 mm

Stage IV: Stage III disease with scaphotrapeziotrapezoidal (STT) osteoarthritis

Although helpful for radiographic description and explanation, this staging system has never shown correlation with the intraoperative extent of disease or treatment outcome.

ANATOMY AND BIOMECHANICS

The thumb CMC joint evolved as an unstable articulation providing prehension, opposition, and circumduction, which distinguished human hand function from that of the higher-order mammals. The joint is a biconcave, reciprocating saddle joint with little inherent stability. There are 16 surrounding ligaments that impart stability[95,96] (Fig. 11.16). There is a discrepancy in articular diameter; the thumb metacarpal articular surface is 34% smaller than the distal articular surface of the trapezium.

The primary stabilizer of the thumb CMC joint is the deep anterior oblique ligament, or palmar "beak" ligament. The deep anterior oblique ligament is an intracapsular ligament emanating from the volar tubercle of the trapezium and inserting on the ulnar volar aspect of the first metacarpal. The ligament tightens with pronation, abduction, and extension, preventing ulnar translation and dorsal translation of the first metacarpal relative to the trapezium. The ligament's obliquely oriented fibers serve to create a center of rotation about which the CMC joint may rotate. The superficial anterior oblique ligament tightens with pronation and extension of the thumb.

Other ligaments that contribute substantially to thumb CMC joint stability include the dorsoradial ligament and posterior oblique ligament, which stabilize and inhibit dorsal translation and ulnar translation of the joint, respectively. The dorsal intermetacarpal ligament of the thumb prevents radial translation of the thumb metacarpal as well as proximal migration of the thumb metacarpal following trapeziectomy.

Mobargha and associates have noted in 11 patients with osteoarthritis that ultrastructural analysis of the deep anterior oblique ligament found disorganized connective tissue, with little evidence of collagen fibers and few signs of innervation. Mechanoreceptors were identified in the dorsoradial ligament, and it was found to be innervated to a much greater extent than the anterior oblique ligament. In contrast, the collagen bundles of the dorsoradial ligament were found to be better organized. No association was noted between ligament innervation patterns and patient age. In a separate study, however, changes in the type and distribution of mechanoreceptors were found among symptomatic patients with degenerative arthritis of the CMC joint.[97,98]

High compressive forces occur across the thumb CMC during pinch that may reach in excess of 12 times the applied load and may approach 20 times the applied load during maximum grasp. Cantilever bending occurs with these applied forces such that shear forces are created that are highest at the volar half of the joint's articular surface. These forces are enhanced with thumb MCP joint flexion. Flexion of the thumb MCP joint produces unloading of the volar portion of the trapezial metacarpal joint as the CMC joint is relatively unloaded.[99] Pellegrini[100,101] has shown an association with degeneration of the volar half of the thumb CMC joint as the integrity of the deep anterior oblique ligament diminishes. Consequently, the dorsal cartilage is relatively spared, even in cases of advanced osteoarthritis. In another study, Pellegrini showed that articular degeneration consistently involved a greater portion of the surface area of the trapezium compared with the metacarpal by a ratio of 3:1, and a decrease in this ratio was associated with more advanced disease.[100,101]

Treatment

Indications and Contraindications

Nonoperative treatment. The first phase of management for patients with osteoarthritis of the thumb CMC joint is nonoperative treatment.

67) A porcentagem das fraturas de escafóide que não podem ser vistas a radiografia simples na fase aguda do trauma é de

a) 10%
b) 15%
c) 20%
d) 25%

Resposta D

referência Green página 682

wrist motion, loss of grip strength, loss of productivity, and premature articular degeneration. Of particular importance is identifying which scaphoid fractures require surgical intervention to heal. A failure to identify an unstable scaphoid fracture and treat it accordingly will predictably result in 6 months or more of additional treatment and restricted activities.

One of the earliest efforts to identify unstable fractures was to examine the scaphoid fracture plane. Russe recognized that oblique fractures were unstable and difficult to control with immobilization and that they resulted in an increased rate of nonunion.[38] Herbert and Fisher classified scaphoid fractures according to their stability.[39] Stable fractures, classified as type A, included incomplete fractures or fractures of the scaphoid tubercle. The authors stated that these fractures could be safely treated with immobilization with expectation of a high rate of union. All other fractures were considered potentially unstable and merited rigid fixation, a point of some controversy. Despite the assertions of these authors, however, Desai and colleagues were unable to predict fracture union with closed treatment using either the Russe or the Herbert classification system.[40]

Cooney and colleagues attempted to further define unstable injuries.[19] These included fractures with more than 1 mm of displacement, a lateral intrascaphoid angle of more than 35 degrees, bone loss or comminution, perilunate fracture-dislocation, DISI alignment, and proximal pole fractures. They advocated open surgical fixation for all unstable injuries.

Management of Scaphoid Fractures

Up to 25% of scaphoid fractures are not visible on initial radiographs. Unless the x-ray beam lies in the same plane as the fracture, the fracture line may be missed. Because delay in treating a scaphoid fracture increases the nonunion rate,[41] the treating physician should be vigilant about confirming diagnosis. The obvious goal is to attain healing of the scaphoid fracture in an anatomic position while maintaining carpal alignment. Patients with union have better functional results.[16,42-44]

Stable Acute Fractures

Distal pole fractures. Distal pole and tubercle fractures of the scaphoid are generally treated nonoperatively. The distal pole of the scaphoid is well vascularized, and distal scaphoid pole fractures have a high rate of union after 6 to 8 weeks of immobilization in a short-arm cast. The two predominant distal fracture types treated in plaster immobilization are (1) avulsion fractures from the radiopalmar lip of the scaphoid tuberosity and (2) impaction fractures of the radial half of the distal scaphoid articular surface. In a study of long-term follow-up of distal scaphoid fractures, Clementson and colleagues reported on a cohort of 41 patients treated nonoperatively in thumb spica casts. All but one healed. Median Disabilities of the Arm, Shoulder, and Hand (DASH) score was 2, median patient rated wrist evaluation (PRWE) 0, and median visual analog scale (VAS) pain score 0. CT revealed arthritis in the scaphotrapeziotrapezoid (STT) joint in 7 out of 41 wrists, none of which caused clinical symptoms.[45]

Nondisplaced waist fractures. Nondisplaced waist fractures may be treated either with casting or with surgery. There are a number of issues involved in this decision, including union rates, recovery time, cost effectiveness, age, and activity level. How to treat these fractures is a complex topic and is controversial in the literature.

Union rates. For nondisplaced waist fractures, union rates are similarly high whether treated in a cast or with surgery. In a prospective randomized trial of cast versus surgery for nondisplaced waist fractures, 100% of fractures healed in both groups.[46] In a multicenter trial, non- to minimally displaced scaphoid waist fractures showed a 98% union rate in a short-arm cast.[47] Dias and colleagues advocate that if a scaphoid waist fracture is displaced less than 2 mm, short-arm casting is used. If a nascent nonunion is suspected by radiographs and a CT scan confirms this, then surgery is performed. This strategy produced union rates of 95%.[48] In a multicenter randomized controlled trial of surgery versus casting for nondisplaced waist fractures, there was no difference in an early surgical group versus a cast immobilization group assessed by PRWE at 52 weeks.[49]

Good outcome for cast treatment is not necessarily the case if *all* acute fractures are treated with cast immobilization. Symes and Stothard[50] performed a systematic review of cast versus surgery for acute scaphoid fractures. Subgroup analysis was not performed as to location or displacement. The rate of nonunion was three times less for surgery, and recovery was quicker. However, there were more complications with surgery.

Recovery time. There is evidence that fixing nondisplaced waist fractures allows for faster healing and earlier return to work. Bond and colleagues demonstrated, in a prospective study of 25 active military personnel randomized to cast or screw treatment, that time to healing was significantly faster for the group who had surgery (7 versus 12 weeks) and the return-to-work time was also significantly faster for this group (8 versus 15 weeks).[46]

Cost effectiveness. The treatment of scaphoid waist fractures by surgery has raised the issue of cost. Would the health care system be better served by plaster immobilization of these stable fractures, or are the theoretical cost savings offset by the increased costs of surgically treating fractures that failed to heal (6% to 23% nonunion rate)? Arora and colleagues compared two groups of stable scaphoid fractures, one treated with plaster immobilization and the other with internal screw fixation.[51] They concluded that internal screw fixation of nondisplaced scaphoid fractures had a shorter time to bony union and that the patients returned to work an average of 7 weeks earlier than patients with cast immobilization. Although it is assumed that operative treatment is more expensive, in this study, the overall cost was not found to be higher.[51]

Davis and colleagues conducted a cost/utility analysis to weigh open reduction and internal fixation (ORIF) against cast immobilization in the treatment of acute nondisplaced midwaist scaphoid fractures.[52] The authors used a model to calculate the outcomes and costs of ORIF and of cast immobilization, assuming the societal perspective. Medical costs were estimated using Medicare reimbursement rates, and costs of lost productivity were estimated by average wages obtained from the U.S. Bureau of Labor Statistics. ORIF offered greater quality-adjusted life-years (QALY) than casting. ORIF was less costly than casting ($7940 versus $13,851 per patient) because of a longer period of lost productivity with casting. When considering only direct costs, the incremental cost/utility ratio for ORIF ranged from $5438 per QALY for the 25- to 34-year-old age group to $11,420 for the 55- to 64-year-old age group, and $29,850 for the age group 65 years and older. They concluded that ORIF is more cost-effective than casting for acute scaphoid fractures.[52]

Age and activity level. Age and activity level usually help guide treatment choices as well. Younger active patients may choose surgery to return to work and activities and sports sooner.[53] Older patients may choose cast immobilization, especially if they have comordities that increase surgical risks.

Cast type for nonoperative treatment. The choice of operative or nonoperative treatment must be individualized based on the discussion of pros and cons of treatment with the patient. If a cast is chosen, there are controversies about what type of cast to use. In a cadaveric study, there was motion of 1 to 4 mm in simulated scaphoid fractures treated with a short-arm thumb spica cast. Therefore the authors recommended a long-arm thumb spica cast.[54] In a series by Dias and colleagues, 23% of

68) O tamanho correto do parafuso utilizado para fixação das fraturas instáveis do escafóide deve ser

a) 2 a 3 mm mais curto que o tamanho medido
b) 4 a 5 mm mais curto que o tamanho medido
c) 8 a 10 mm mais curto que o tamanho medido
d) no limite da cartilagem do tamanho medido

Resposta B

referência Green página 689

Fig. 16.13 In 1998, Haddad and Goddard reported on a simplified volar percutaneous technique using traction and a cannulated screw to stabilize waist fractures. The thumb is suspended by a single finger trap. It permits free rotation of the hand throughout the operation, and the scaphoid remains in the center of an imaging unit. The C-arm is turned to a horizontal position surrounding the wrist. The most important step is to establish the entry point of the guidewire and the position of the screw. The ulnar deviation of the wrist is provided by thumb traction and allows the distal half of the scaphoid to slide out from under the radial styloid. The scaphoid tuberosity is easily palpable and is the key to the insertion point. The entry point is located using a 12- or 14-gauge intravenous needle, which is introduced radial and distal to the scaphoid tuberosity. (From Haddad FS, Goddard NJ. Acute percutaneous scaphoid fixation: a pilot study, *J Bone Joint Surg Br* 80[1]:95–99, 1998.)

To perform percutaneous volar scaphoid screw fixation, the patient is placed supine on an operating table and the hand is suspended vertically by the thumb using a finger trap (Fig. 16.13).[95] This position extends the scaphoid and ulnarly deviates the wrist to improve access to the distal pole of the scaphoid. A fluoroscopic imaging unit is rotated parallel to the floor and positioned so that the wrist is in its central axis. Traction from a tower permits full rotation of the scaphoid in the imaging beam. In the majority of cases, longitudinal traction is enough to reduce the scaphoid fracture. If the fracture is not reduced, Kirschner wires can be inserted and used as joysticks to manipulate the fragments into position. The quality of the reduction can then be checked radiographically.

Having achieved an acceptable reduction, the most important step is to establish the entry point of the guidewire. The ulnar deviation of the wrist extends the scaphoid to make the tubercle more accessible. The entry point, the scaphoid tuberosity, is located using a 12- or 14-gauge intravenous needle introduced on the anteroradial aspect of the wrist, just radial and distal to the scaphoid tuberosity. The needle serves as a trocar to guide the wire and establish a central path along the scaphoid. The needle is inserted into the scaphotrapezial joint and tilted into a vertical position. The needle is levered on the trapezium, which brings the distal pole of the scaphoid more radially and facilitates screw insertion. The wrist is rotated in the fluoroscopic beam to confirm that the needle is aligned along the axis of the scaphoid in all planes, with the intent of directing the guidewire into the proximal pole to a point just radial to the scapholunate ligament. Leventhal and colleagues identified the ideal starting point to be approximately 2 mm dorsal and just radial to the apex of the scaphoid tubercle in order to achieve maximum guidewire length within the scaphoid.[92]

Once the entry point and the direction of the guidewire are confirmed, the needle is impacted into the soft articular cartilage over the distal pole of the scaphoid so that the tip does not slip during insertion of the guidewire. The guidewire is passed down through the needle and drilled across the fracture; its direction is continually checked on the image intensifier and adjusted as necessary, with the goal of entering the radial aspect of the proximal pole. The position is checked in multiple fluoroscopy planes, and, if satisfactory, a longitudinal incision of 0.5 cm is made at the entry point of the wire and deepened down to the distal pole of the scaphoid using a small hemostat and blunt dissection. This is a relatively safe zone, with minimal risk to the adjacent neurovascular structures.

The length of the screw is determined using a depth gauge or by advancing a second guidewire of the same length up the distal cortex of the scaphoid and subtracting the difference between the two. The correct screw size is 4 to 5 mm shorter than the measured length, which will ensure that the screw head is fully buried below the cartilage and the subchondral bone on each end. In rare cases a second antirotation wire may be inserted parallel to the first prior to drilling and reaming. The wire is advanced into the radius or out of the dorsal skin and clamped so as to avoid loss of wire position with drilling. The 12-gauge needle is removed and the cannulated drill is passed over the wire and advanced under imaging guidance, stopping 1 to 2 mm short of the far articular surface. At this point the hand is taken out of traction so that the screw will adequately compress the scaphoid. A countersink or a trailing drill is used, depending on the particular set. A self-tapping screw is advanced over the guidewire. The final position is checked with multiple fluoroscopic views to confirm complete containment within the scaphoid. A hyperpronated PA view profiles the dorsal-radial cortical margin of the scaphoid, where a perforation of the proximal cortical bone can occur.[84] Compression of the fracture site is confirmed radiographically on the image intensifier. The wire is removed, the skin closed with a suture or Steri-Strips, and the wound covered with a sterile compressive dressing.

Postoperative care. A plaster splint is removed at 10 to 14 days postoperatively. The sutures are removed at this stage, and wrist radiographs (PA, lateral, 45-degree oblique, scaphoid view) are taken to confirm that screw position is satisfactory. Depending on the bone quality, fixation, and assumed patient compliance, a short-arm cast or well-molded thermoplastic short-arm splint is used for 4 additional weeks or until the fracture has healed. Hand therapy may be useful to regain hand motion and forearm rotation; no heavy carrying or weight-bearing activity is permitted. A return to sedentary work is allowed as soon as the patient feels ready or when 75% of the contralateral range of movement is achieved. When radiographic and clinical union have been achieved, the splint is discontinued and all previous activities are resumed as tolerated. CT is used to confirm healing before return to heavy lifting or competitive athletics.

Potential complications include malposition of the screw, violation of the cortical surface, and hardware protrusion within the radioscaphoid or scaphocapitate joint proximally, breakage of a guidewire, and fracture of the scaphoid during screw placement. Another potential problem is a failure to completely bury the head of the screw within the scaphoid, which can lead to STT arthrosis. This problem is avoided by selecting a screw length approximately 4 to 5 mm shorter than

69) As estruturas representadas pelas letras A e B são respectivamente

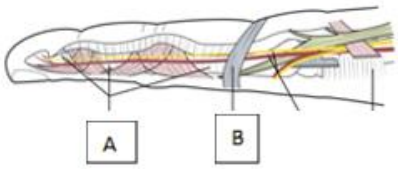

a) ligamento Cleland e banda espiral
b) ligamento de Grayson e ligamento Natatório
c) ligamento de Cleland e ligamento Natatório
d) ligamento de Grayson e banda espiral

Resposta B

referência Green página 157

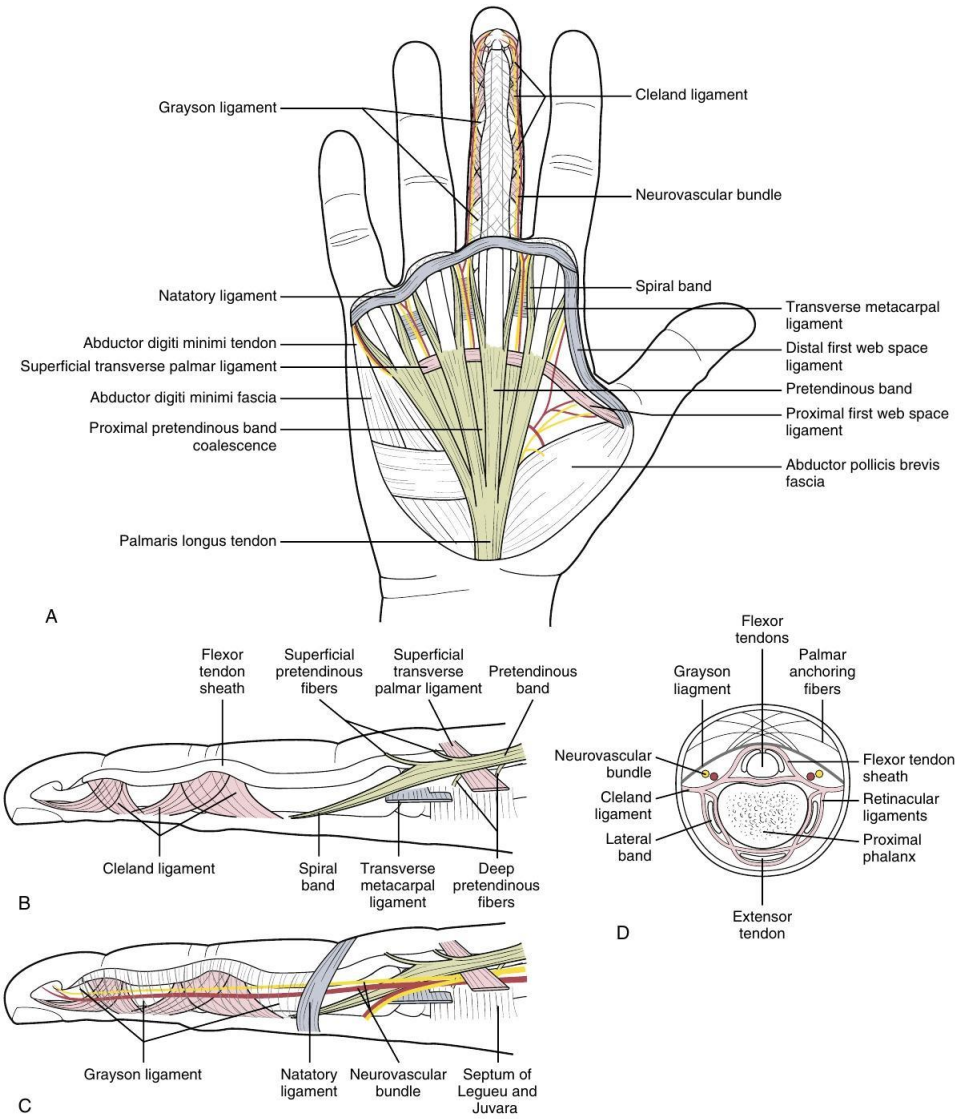

Fig. 4.8 Normal fascial anatomy. **A,** Palmar view of structures beneath skin and subcutaneous tissues of the palm and finger. **B,** Lateral view of the deeper structures of the distal palm and finger. **C,** Lateral view of the more superficial structures of the distal palm and finger. **D,** Axial cross-sectional view of finger proximal to the proximal interphalangeal joint.

70) A figura abaixo representa um paciente com Rizartrose no estágio

a) I de Eaton
b) II de Eaton
c) III de Eaton
d) IV de Eaton

Resposta C

referência Green página 423

Fig. 11.15 Robert's true PA radiograph of the thumb carpometacarpal (CMC) joint of a 52-year-old female with stage III CMC osteoarthritis.

chuck pinch test using a dynamometer, may be helpful when absolute values are compared with those of the contralateral side (Video 11.3). Pinch maneuvers such as the two-point or lateral pinch test may increase forces across the CMC joint by a factor of 12. The examiner should be aware that the association of carpal tunnel syndrome with CMC osteoarthritis approaches 30%.

Diagnostic Imaging

Radiographs to profile the thumb CMC joint include PA, lateral, and oblique views of the hand or, alternatively, PA and lateral views of the wrist. A Robert view of the thumb CMC joint is also helpful because it is a true PA view of the joint (Fig. 11.15). The Robert view requires special positioning of the arm and hand that some patients may find difficult, especially if they have limited or painful motion of the shoulder. The Robert view is obtained with the arm and hand in a combination of positions, including shoulder flexion, shoulder internal rotation, and wrist hyperpronation, so that the dorsal surface of the thumb can be placed directly on the radiograph cassette. Advanced imaging studies such as MRI or CT scanning are seldom necessary for operative procedures or surgical decision making about the thumb CMC joint.

Eaton and colleagues have described a widely accepted radiographic staging system for thumb CMC joint degenerative arthritis[94]:

Stage I: Normal or slight widening of the joint shadow due to synovitis

Stage II: Mild joint shadow narrowing with osteophyte formation of 2 mm or less

Stage III: Marked joint shadow narrowing with osteophyte formation of more than 2 mm

Stage IV: Stage III disease with scaphotrapeziotrapezoidal (STT) osteoarthritis

Although helpful for radiographic description and explanation, this staging system has never shown correlation with the intraoperative extent of disease or treatment outcome.

ANATOMY AND BIOMECHANICS

The thumb CMC joint evolved as an unstable articulation providing prehension, opposition, and circumduction, which distinguished human hand function from that of the higher-order mammals. The joint is a biconcave, reciprocating saddle joint with little inherent stability. There are 16 surrounding ligaments that impart stability[95,96] (Fig. 11.16). There is a discrepancy in articular diameter; the thumb metacarpal articular surface is 34% smaller than the distal articular surface of the trapezium.

The primary stabilizer of the thumb CMC joint is the deep anterior oblique ligament, or palmar "beak" ligament. The deep anterior oblique ligament is an intracapsular ligament emanating from the volar tubercle of the trapezium and inserting on the ulnar volar aspect of the first metacarpal. The ligament tightens with pronation, abduction, and extension, preventing ulnar translation and dorsal translation of the first metacarpal relative to the trapezium. The ligament's obliquely oriented fibers serve to create a center of rotation about which the CMC joint may rotate. The superficial anterior oblique ligament tightens with pronation and extension of the thumb.

Other ligaments that contribute substantially to thumb CMC joint stability include the dorsoradial ligament and posterior oblique ligament, which stabilize and inhibit dorsal translation and ulnar translation of the joint, respectively. The dorsal intermetacarpal ligament of the thumb prevents radial translation of the thumb metacarpal as well as proximal migration of the thumb metacarpal following trapeziectomy.

Mobargha and associates have noted in 11 patients with osteoarthritis that ultrastructural analysis of the deep anterior oblique ligament found disorganized connective tissue, with little evidence of collagen fibers and few signs of innervation. Mechanoreceptors were identified in the dorsoradial ligament, and it was found to be innervated to a much greater extent than the anterior oblique ligament. In contrast, the collagen bundles of the dorsoradial ligament were found to be better organized. No association was noted between ligament innervation patterns and patient age. In a separate study, however, changes in the type and distribution of mechanoreceptors were found among symptomatic patients with degenerative arthritis of the CMC joint.[97,98]

High compressive forces occur across the thumb CMC during pinch that may reach in excess of 12 times the applied load and may approach 20 times the applied load during maximum grasp. Cantilever bending occurs with these applied forces such that shear forces are created that are highest at the volar half of the joint's articular surface. These forces are enhanced with thumb MCP joint flexion. Flexion of the thumb MCP joint produces unloading of the volar portion of the trapezial metacarpal joint as the CMC joint is relatively unloaded.[99] Pellegrini[100,101] has shown an association with degeneration of the volar half of the thumb CMC joint as the integrity of the deep anterior oblique ligament diminishes. Consequently, the dorsal cartilage is relatively spared, even in cases of advanced osteoarthritis. In another study, Pellegrini showed that articular degeneration consistently involved a greater portion of the surface area of the trapezium compared with the metacarpal by a ratio of 3:1, and a decrease in this ratio was associated with more advanced disease.[100,101]

Treatment

Indications and Contraindications

Nonoperative treatment. The first phase of management for patients with osteoarthritis of the thumb CMC joint is nonoperative treatment.

71) As estruturas representadas pelas letras A, B e C respectivamente são

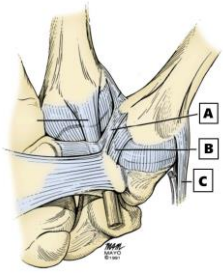

a) ligamento colateral ulnar, ligamento oblíquo posterior e ligamento dorso radial
b) ligamento oblíquo anterior, ligamento oblíquo posterior e ligamento dorso radial
c) ligamento colateral ulnar, ligamento oblíquo posterior e abdutor longo do polegar
d) ligamento colateral ulnar, ligamento oblíquo anterior e abdutor longo do polegar

Resposta D

referência Green página 424

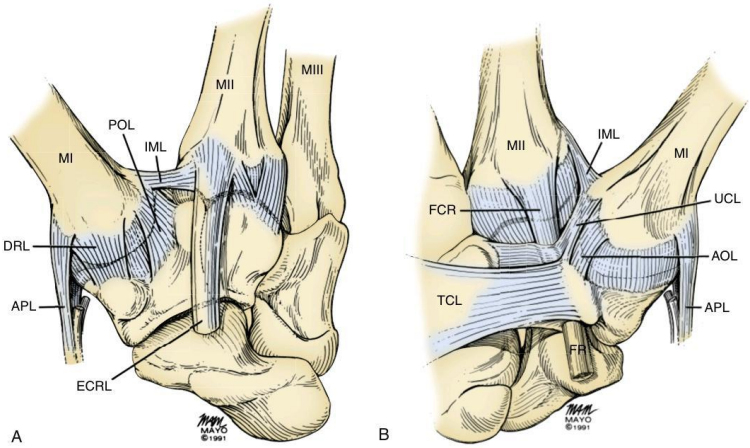

Fig. 11.16 Posterior view **(A)** and anterior view **(B)** showing ligamentous anatomy of the thumb carpometacarpal joint. *APL,* Abductor pollici longus; *AOL,* anterior oblique ligament; *DRL,* dorsoradial ligament; *ECRL,* extensor carpi radialis longus; *FCR,* flexor carpi radialis; *FR,* flexor radialis; *IML,* intermetacarpal ligament; *MI,* metacarpal I; *MII,* metacarpal II; *MIII,* metacarpal III; *POL,* posterior oblique ligament; *TCL,* transverse carpal ligament; *UCL,* ulnar collateral ligament. (Copyright © Mayo Clinic, Rochester, MN. Modified with permission.)

This may include thumb spica splinting, which may be forearm or hand based but preferably leaves the thumb IP joint free for patient comfort. In addition to splinting, NSAIDs may be used orally or topically, depending on patient tolerance or physician preference. Outpatient hand therapy may consist of ultrasound, paraffin wax, heat, and deep tissue massage, along with activity modifications. The success of hand therapy protocols in these situations is variable. Sustained benefit from splinting and corticosteroid injections has been demonstrated by several authors.[102,103] One randomized controlled, blinded trial, however, showed no difference in scores on the visual analog pain scale at 24 weeks when comparing a group treated with a thumb CMC joint steroid injection and another group treated with saline injection.[104]

First metacarpal osteotomy. Forces across the thumb CMC joint lead to cantilever bending and result in high concentrations of shear forces across the volar half of the joint. These forces are believed to be causative in the preferential development of osteoarthritis across the volar portion of the thumb CMC joint. Therefore a 30-degree closing wedge, extension osteotomy of the thumb metacarpal has been theorized to unload the volar segment of the thumb CMC joint by redistributing the load through the more dorsal segment of the joint. The first metacarpal osteotomy is indicated for patients with stage I or II disease but contraindicated in patients with hypermobility, fixed subluxation, or hyperextension of the joint.

In 1999, Tomaino et al.[105] reported on 12 patients with stage I disease treated with extension osteotomy of the thumb metacarpal. All osteotomies healed within 7 weeks; 11 of the 12 were satisfied with the outcome, and all had increased grip and pinch strength at 2 years of follow-up. Parker and colleagues[106] and more recently Bachoura et al.[107] have reported similar results.

Ligament reconstruction. For patients with stage I or II disease of the thumb CMC joint, ligament reconstruction alone may be preferred over other salvage techniques. Instability of the volar ligamentous complex of the joint, particularly the deep anterior oblique ligament, has been proposed as the potential cause of osteoarthritis of the joint.[108] In a biomechanical study, Koff and coworkers[109] have shown that ligament reconstruction improved stability of the joint. Ligament reconstruction has been typically reserved for patients with very mild articular changes and is contraindicated in patients with stages III and IV disease.[93]

Resection arthroplasty. The majority of reconstructive procedures for thumb CMC osteoarthritis involve resection arthroplasty of the trapezium, with removal of the articular base of the first metacarpal with or without ligament reconstruction and with or without interposition of autograft material.[110] This procedure is typically reserved for patients with stage III or IV disease, although durability of this procedure has been reported in a younger population with stage I disease.[111] In 1984, Burton and Pellegrini[112] described a technique for "advanced osteoarthritis of the thumb CMC joint," in part based on the procedure described by Eaton and Littler for reconstruction of the deep anterior oblique ligament. This procedure involves resection of the trapezium and base of the first metacarpal, along with a stabilization procedure they termed the *flexor carpi radialis sling suspension interposition*. Similar to the Eaton and Littler procedure, a portion of the flexor carpi radialis (FCR) tendon is used to reconstruct the deep anterior oblique ligament (or perhaps more accurately, the intermetacarpal ligament) and to create an interposition arthroplasty, filling the void left by trapezium resection. Theoretically, this interposition and deep anterior oblique ligament reconstruction provides support and resists subsidence of the thumb metacarpal. Shah et al. have shown in a cadaver study that wrist biomechanics are altered following trapeziectomy, and the ligament reconstruction and tendon interposition (LRTI) procedure helps restore wrist biomechanics.[113]

72) A radiografia abaixo representa um paciente com diagnóstico de

a) deformidade de Madelung
b) Mão torta ulnar
c) sequela de osteomielite
d) Mão torta radial

Resposta A

referência Green página 1370

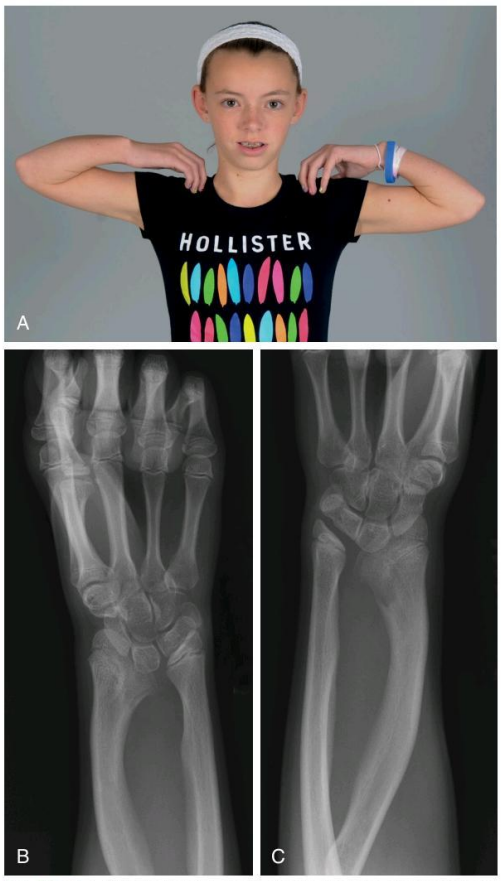

Fig. 35.15 A 12-year-old with short stature, bilateral shortened forearms, and Leri-Weill dyschondrosteosis. **A,** Clinical appearance of bilateral Madelung deformity. **B,** Left wrist radiograph with classic findings associated with Madelung deformity. **C,** Right wrist x-ray with similar findings. (Courtesy of Shriners Hospital for Children, Philadelphia, Pennsylvania.)

Fig. 35.16 Mother and 9-month-old boy with inherited Holt-Oram syndrome and associated radial deficiency. Mother's and child's heart anomalies required surgical intervention. (Courtesy of Soldado Francisco, MD, PhD.)

Fig. 35.17 Hands of a child with Grebe chondrodysplasia and severe brachydactyly associated with a cartilage-derived morphogenetic protein deficiency. (Courtesy of Shriners Hospital for Children, Philadelphia, Pennsylvania.)

Altered expression of T-box products can affect the anteroposterior (i.e., radioulnar) development of the limb. The combination of a cardiac defect and radial deficiency (e.g., Holt-Oram syndrome) has been specifically linked to the production of transcription factor Tbx5.[57-59] Holt-Oram syndrome is an autosomal dominant trait with variable phenotypes, and affected families would benefit from genetic counseling (Fig. 35.16). T-box gene mutations have also been linked to limb anomalies associated with a variety of systemic syndromes, including ulnar-mammary syndrome (Tbx3 mutation), which is associated with postaxial limb anomalies.[3,60,61]

The family of BMPs are expressed in the developing limb.[16] Cartilage-derived morphogenetic protein appears paramount to digital length during embryogenesis. Deficiencies in a cartilage-derived morphogenetic protein are associated with various forms of brachydactyly. Grebe and Hunter-Thompson chondrodysplasias are associated with severe brachydactyly and have been directly related to a cartilage-derived morphogenetic protein deficiency (Fig. 35.17).[62,63]

Systemic Considerations

During the period of embryogenesis, other organ systems are also developing and maturing. Errors affecting limb formation can also disturb formation of these systems. Certain upper limb anomalies are associated with concomitant systemic disorders (e.g., radial deficiency).[64,65] Other limb anomalies occur in isolation or are combined with other musculoskeletal problems (e.g., ulnar deficiency).[66] Some limb anomalies, such as central deficiency, can be associated with a systemic condition (EEC syndrome: triad of ectrodactyly, ectodermal dysplasia, and facial clefting) or can be linked to other musculoskeletal anomalies, such as lower limb hemimelia. Identifying anomalies that occur in isolation and anomalies associated with systemic ailments is mandatory. Many of the systemic

73) O ângulo Teardrop nas fraturas do rádio distal com deslocamento anterior estará

a) abaixo de 45 graus
b) acima de 70 graus
c) abaixo de 50 graus
d) entre 60 e 70 graus

Resposta B

referência Green página 610

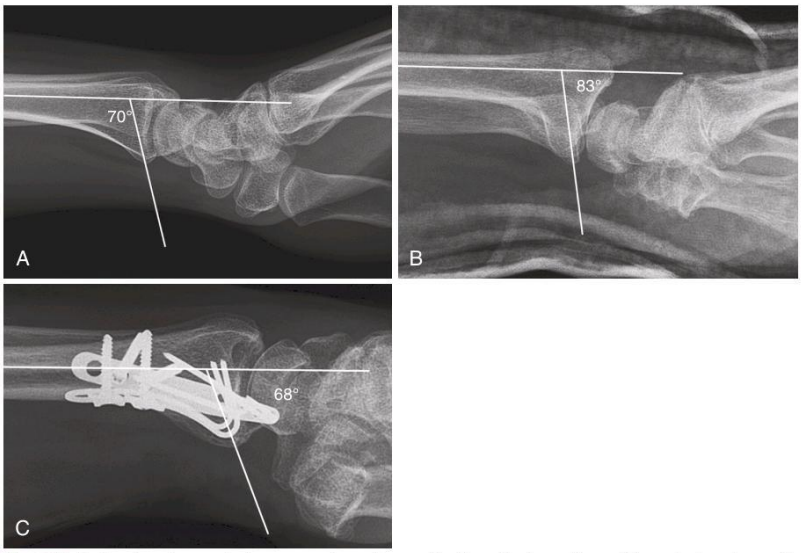

Fig. 15.9 **A,** The teardrop angle is measured as a tangent to the articular surface of the volar teardrop with respect to the longitudinal axis of the radius and is normally 70 degrees. **B,** Increased teardrop angle with a displaced volar marginal fracture. **C,** Normalized after surgery.

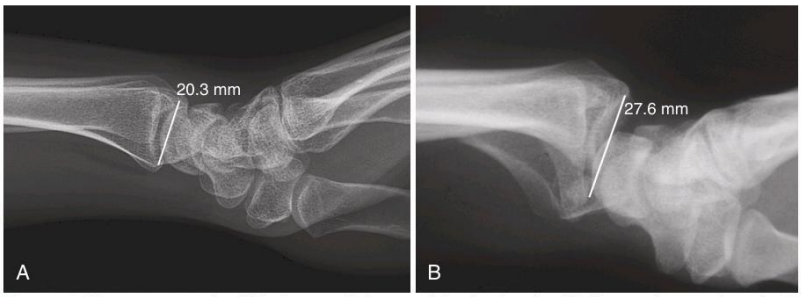

Fig. 15.10 The anteroposterior (AP) distance. **A,** In an uninjured wrist, the AP distance is approximately 20 mm in males and 18 mm in females. **B,** In this lateral radiograph of an injured wrist, the AP diameter is grossly widened (~28 mm).

articular fractures with articular impaction (Fernandez type III), fracture–dislocations (Fernandez type IV), or combined injuries with metaphyseal–diaphyseal comminution (Fernandez type V). Some fractures may require surgical management for other reasons, including open fractures or fractures complicated by nerve compression, compartment syndrome, or multiple injuries.

What is not immediately intuitive is how to classify the rest of the fractures as stable or unstable, preferably early in the acute setting, when an acceptable reduction has been achieved. It is well known that even fractures without primary displacement can develop a secondary collapse under conservative treatment by the time of complete healing, and the opposite, fractures with a considerable primary displacement, may, after reduction and immobilization, heal anatomically in a cast.

The classic predictive model of stability was presented by Lafontaine and colleagues, who defined risk factors associated with redisplacement in 112 patients. Five parameters were defined, and a linear relationship was shown between the number of instability parameters in the prereduction films and ultimate fracture collapse with closed treatment.[15] The following parameters were suggested:

- Dorsal angulation greater than 20 degrees
- Dorsal comminution
- Intraarticular radiocarpal fracture
- Associated ulnar fracture
- Age of more than 60 years

Lafontaine recommended that patients with three or more of the five parameters should be considered for surgical intervention at an early stage of management. Although inclusion of all the factors is the subject of some controversy, subsequent authors have confirmed the idea that stability is a combination of factors, and therefore the term relative stability is best used (Case Studies 15.1 and 15.2).

74) As amputações das extremidades dos dedos ao nível do eponíquio correspondem a zona

a) I de Tamai e II de Allen
b) II de Tamai e IV de Allen
c) II de Allen e III de Tamai
d) I de Allen e II de Tamai.

Resposta B

referência Green página 1908

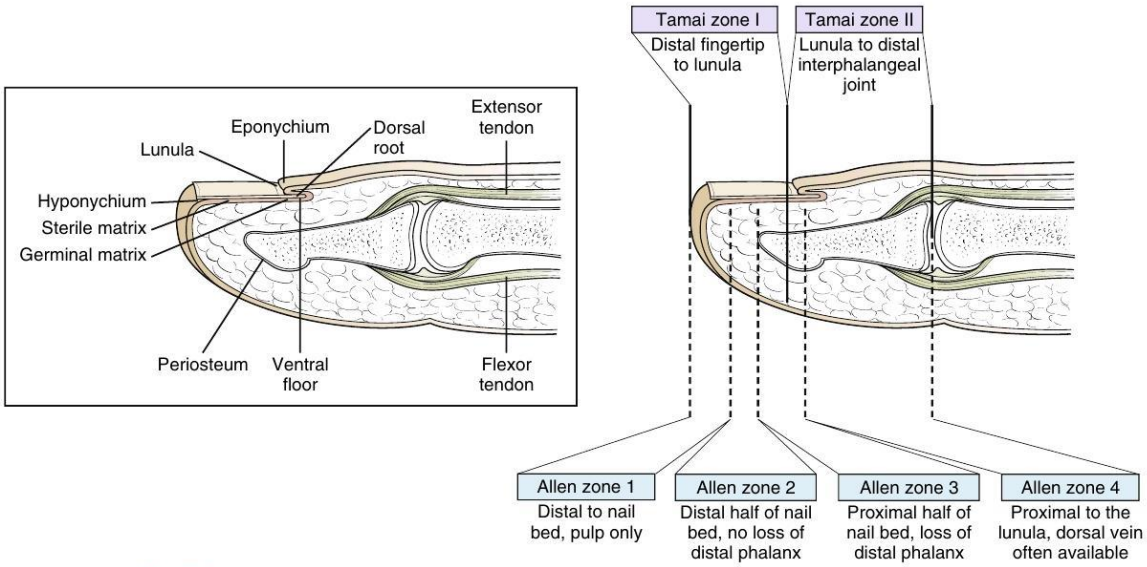

Fig. 49.1 Illustration demonstrating the anatomy of the distal finger and nail bed and the Tamai and Allen classifications for distal amputations of the fingertip. The *line* through the lunula represents the divisions between Tamai zones I and II.

reattached as a composite graft or defatted and sutured to the residual digit as a full-thickness skin graft (Fig. 49.2). The concept of using it as a "biologic dressing" has been advocated by some; however, this is not often appropriate in adults due to the lack of success, and the concept of placing dead tissue into a contaminated field is flawed. If there is bony involvement of the composite graft, stability may be afforded by repair of the amputated tip with absorbable sutures, Kirschner wires, or a hypodermic needle. The nail plate is removed and the nail plate repaired.[6] Timing of repair may be important. Moiemen and Elliot noted that those repaired within 5 hours after injury had a 61% survival rate compared with none after this time point.[7] The tip may become necrotic but should be left in situ as long as there is no developing infection because the tissue acts as a biologic dressing. Butler and colleagues conducted a retrospective review of 120 patients under 16 years of age who underwent composite graft of digital tip injuries and noted 10% complete and 34% partial graft survival rate. Patients younger than the age of 4 years were likely to have complete graft survival. However, 48% of patients developed a hook nail deformity, 17% had cold intolerance, and 95% had some degree of functional limitations in the long term.[8] Similar success has not been noted within adults.[9] Heistein and Cook[10] reported on 53 patients who underwent composite tissue grafting of injuries distal to the DIP joint. The success rate was 43% for injuries between the DIP joint and the eponychium and 58% for injuries distal to the eponychium. Factors linked to suboptimal results were smoking, age older than 18 years, alcohol use, presence of diabetes, and crush injury. In an effort to improve survival, Chen and colleagues[11] reported on a technique whereby the distal amputated tip was defatted and deep-ithelialized and the bone excised in patients who sustained either a crush injury or a sharp transection injury. The survival rate was higher than 93% with an average two-point discrimination of 6.3 mm after 6 months. Over 90% of patients were happy with the cosmetic appearance and 86% were able to use the finger normally at work.

Dressing Changes and Healing by Secondary Intention

Healing by secondary intention with dressing changes is one of the best options for a tip amputation without exposed bone. This technique is especially applicable when the amputated part is unavailable or cannot be used. The technique is simple, inexpensive, and effective, regardless of patient age (Fig. 49.3).[4,12-18] Healing by secondary intention is most applicable for wounds with skin loss of 1.5 cm or less; healing will occur by wound contracture and reepithelialization over 3 to 4 weeks with return of normal sensation and two-point discrimination. Indeed, recovery of sensation tends to be better than with other forms of surgical reconstruction.[4,19] Dressing changes can also be used to treat wounds with additional loss of subcutaneous tissue of similar size, but it may take 1 to 2 months to heal by this method. The patient performs daily dressing changes and local wound care. Protective splinting may be used to protect the healing wound. Patients can be referred to hand therapists within the first few days after injury to use modalities such as MIST ultrasound therapy (Celleration, Inc., Eden Prairie, MN) to encourage granulation tissue formation. Ultrasound works by reducing the bacterial load and promoting tissue regeneration by increasing angiogenesis, release of growth factors, and collagen deposition.[20] Patients are encouraged to work on the range of motion to avoid joint stiffness and/or contractures.

Bojsen-Moller and colleagues reviewed a series of 134 digital tip injuries in 110 patients who were treated by dressing changes, shortening of the digit, or skin grafting.[21] They observed that nonoperative treatment was uniformly compared with surgical cases that developed a variety of complications such as infection or graft failure that prolonged treatment. In addition, there was no significant difference in time off work between the treatment groups. The authors concluded that management of an amputation by skin grafting or dressing changes was superior to surgical shortening and primary closure. Allen[4] reported on 46 patients with 49 fingertip injuries from the lunula and distal. If the distal phalanx was exposed, it was trimmed back to allow soft tissue to cover it. Forty-five patients felt their results were very good or good, 3 believed their outcome was acceptable, and 1 deemed the result as poor. Four of the 49 injuries required secondary surgery, 3 for nail growth problems and 1 because of lack of ample soft tissue coverage. The average two-point discrimination was 6 mm, and the average time off work ranged from 18 to 26 days. None

75) O retalho do tensor da fáscia lata é considerado um retalho

a) músculo cutâneo com apenas um pedículo, portanto do tipo I
b) músculo cutâneo com um pedículo dominante e vários secundários, portanto do tipo III
c) músculo cutâneo com dois pedículos dominantes, portanto do tipo III
d) músculo cutâneo com um pedículo dominante e vários secundários, portanto do tipo V

Resposta A

referência Green página 1732

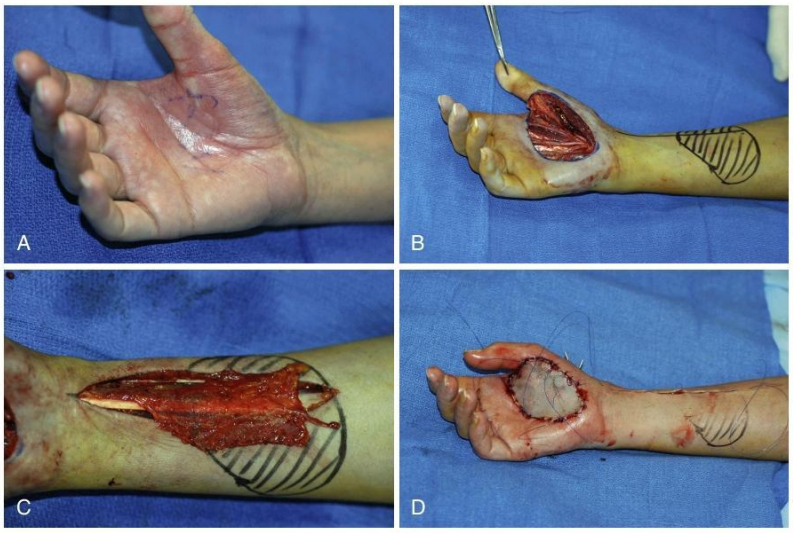

Fig. 44.35 Radial forearm fascial flap. **A,** Palm of patient with soft tissue sarcoma following irradiation prior to resection. **B,** View of hand after resection and markings for harvest of a distally based radial forearm fascial flap. **C,** Flap elevated with pedicle. **D,** Rotated into palm and covered with a split-thickness skin graft.

Type III: Two dominant (e.g., gluteus maximus)
Type IV: Several, equal, segmental (e.g., sartorius)
Type V: One dominant plus peripheral (e.g., latissimus dorsi)

In types I, II, and V, one dominant pedicle is capable of supporting the entire muscle if the others are ligated. Theoretically, therefore, any muscle in the upper extremity that belongs to one of these three types can be transposed on its pedicle. Several have been described: latissimus dorsi to the shoulder and upper arm; deltoid to the shoulder; brachioradialis, extensor carpi radialis longus, and flexor carpi ulnaris to the elbow; flexor digitorum superficialis to the antecubital fossa; extensor carpi ulnaris and flexor digitorum profundus to the proximal ulna; pronator quadratus and abductor digiti minimi[91] to the wrist; and the first dorsal interosseous to the first metacarpal and to the third metacarpal. Because the majority of these lie beneath a well-vascularized deep fascia, most have been used as muscle flaps covered with a split-thickness skin graft. These flaps have limited value as they sacrifice a functioning muscle. Furthermore, their contour is good only when the defect has a volume similar to that of the muscle belly. The function of the transposed muscle can be preserved where necessary,[92] provided the correct tension is maintained. The fascia overlying a muscle, if it is thick, has a rich plexus supplied through vessels of the intermuscular septa. The plexus also supplies the overlying skin, which allows harvest of a fasciocutaneous flap, leaving the muscle in place. Where the fascia is thin or absent, the supply to the skin comes more from small branches that perforate the muscle; such vessels supply the skin over the latissimus dorsi. In this case the muscle and the overlying skin can be moved as a block to provide skin cover and function. There is still a debate as to whether the coverage is better with a skin-grafted muscle versus a muscle and its overlying skin (musculocutaneous flap).

Two muscles in the type V classification have been used to provide coverage and/or function in the upper extremity, the pectoralis major and latissimus dorsi. The main vascular pedicle of the pectoralis major, the pectoral branch of the acromiothoracic axis, is supplemented by the lateral thoracic artery[93] and enters close to its insertion. There are numerous additional small vessels entering the periphery or origin of the muscle, notably from the internal mammary artery. Unlike all the regional axial muscle flaps listed earlier, the pectoralis can be left attached at its insertion and released from its origin. The muscle can be split longitudinally to cover two adjacent defects. The pectoralis muscle without skin (and it may be used with the addition of the pectoralis minor) has long been used for restoration of elbow flexion after nerve injury[94] or arthrogryposis. With an island of overlying skin, the pectoralis major has been used as an axial regional flap for reconstruction of the axilla and shoulder. However, the secondary defect with loss of the axially contour is entirely unacceptable to women and largely so to men. The latissimus dorsi flap and pectoralis flap cover similar upper extremity defects. The latissimus dorsi flap, however, has an acceptable donor site and is preferred in virtually all cases.

Latissimus dorsi flap. The latissimus dorsi flap has a wide arc of rotation around its pedicle and is therefore useful for reconstruction of the breast, the abdominal wall, the head and neck, and the shoulder.[95,96] The diameter of the artery (1 to 2.5 mm) and the length of the pedicle (11 cm) have made the latissimus dorsi flap the most robust and popular tissue for free transfer, especially to the extremities. Functional transposition of the latissimus dorsi to restore lost biceps function was developed over 30 years ago.[97] The latissimus dorsi flap can restore both function and skin cover.[98] The latissimus muscle has also found some utility in the functional reconstruction of massive shoulder rotator cuff tears.[99]

The latissimus dorsi arises from the lower six thoracic vertebrae, from the thoracolumbar fascia, and from the posterior part of the iliac crest. From this extensive origin the muscle fibers converge to wrap around the lower border of the teres major and end in a quadrilateral tendon that inserts into the intertubercular sulcus of the humerus. Together with the teres major, it forms the posterior axillary fold. Furnas and Furnas[100] reported one patient in whom the lower part of the

76) A imagem abaixo representa um caso de

a) Clinodactilia
b) Braquidactilia
c) deformidade de Kirner
d) Condrodisplasia

Resposta C

referência Green página 1436

be taken into consideration. The outcomes of epiphysiolysis vary according to the extent of growth potential remaining in the digit at the time of surgery.

CRITICAL POINTS

Clinodactyly

- Clinodactyly is angulation of the digit in the radioulnar (coronal) plane distal to the metacarpophalangeal joint.
- Minor angulation, particularly of the small finger, is common to the point of normalcy. The etiology is usually an abnormal trapezoidal shape of the middle phalanx that leads to radial deviation of the distal interphalangeal joint.
- Greater angulation may be secondary to a longitudinal diaphyseal bracket or a longitudinal epiphyseal bracket along the middle phalanx.
- Mild to moderate clinodactyly requires no treatment.
- Substantial clinodactyly requires realignment of the digit via a closing wedge, opening wedge, or reverse wedge osteotomy. The soft tissue deficit on the concave side must also be addressed.

KIRNER DEFORMITY

Kirner deformity is characterized by progressive palmar-radial curvature of the distal phalanx of the digit and usually affects the small finger. The deformity was initially described by Kirner in 1927 in the German literature and subsequently by Thomas in 1936 in the *Lancet*.[213] Most of the literature regarding Kirner deformity consists of isolated reports or small series. The condition, however, presents with a characteristic appearance and is common enough to be encountered by most pediatric hand surgeons.

Epidemiology

The incidence has been estimated to be 0.25% of the population, and females are affected twice as frequently as males.[214] The deformity may be inherited as an autosomal dominant trait with incomplete penetrance. The homozygous state is responsible for expression of the deformity in multiple digits and both hands.[215] The deformity occurs sporadically in the majority of cases. Song proposed a classification based on age of onset as either early-onset (congenital deformity present at birth and associated with a family history) or late-onset (deformity developing in late childhood or adolescence and sporadic in incidence).[216] In the more common late-onset presentation, there is a history of swelling over the dorsum of the distal phalanx base of the small finger. There may be some discomfort associated with this stage, but usually the swelling is painless. The deformity then ensues with the development of the palmar-radial curvature of the distal fingertip (Fig. 36.91), which is marked by the clubbed or beaked appearance of the fingernail. Once established, the deformity is stable. Joint motion at the distal IP joint is preserved.

While Kirner deformity is usually seen in isolation, it has also been noted in cases of Cornelia de Lange syndrome, Silver syndrome, Turner syndrome, and Down syndrome. The differential diagnosis in the unilateral deformity is a delayed presentation of distal phalangeal trauma, particularly a physeal fracture with palmar angulation, or a burn or frostbite injury to the physis. A thorough history coupled with the physical and x-ray findings usually enable confident diagnosis.

PATHOANATOMY

A number of theories of etiology have been proposed to be responsible for Kirner deformity. Early observations attributed the deformity

Fig. 36.91 Clinical appearance of Kirner deformity of the right small finger.

to an acquired etiology such as osteochondritis of either the epiphysis or entire distal phalanx or focal epiphysiolysis with the angulation due to the effect of the strong flexor tendon on the compromised phalanx.[217,218] Despite these reports, there is general consensus that the deformity is due to a congenital cause given the epidemiology of the condition. An abnormal distal insertion of the FDP tendon along the phalanx has been linked to the deformity.[219,220] Radiographic and more recently magnetic resonance imaging evidence of congenital physeal deformity has also been proposed as the basis of the deformity.[214,221] Fairbank and coworkers described an L-shaped basal physis accounting for restriction of palmar growth and progressive deformity.[221]

Kirner deformity is characterized by distortion and widening of the physeal plate along with curvature of the diaphysis of the distal phalanx (Fig. 36.92). Radiographs show an abnormality of the epiphysis with the palmar lip of the epiphysis relatively lengthened and the metaphyseal margin of the physis sclerotic and ragged. Physeal plate closure is delayed and begins in the dorsal half of the physis. Histology of the phalanx at this stage demonstrates lysis at the junction of the metaphysis and physis. Later, the diaphyseal curvature is well established, and in the mature form of the deformity, the physis has completely fused and normal bone density is restored throughout the deformed phalanx.

Management

Kirner deformity has little effect on function. Musicians and keyboard operators may identify specific problems related to small finger position. The indication for surgery is primarily restoration of the finger appearance. The patient must be counseled carefully about the potential risks of surgery and expected results.

Splinting the small finger into extension has been reported as effective in relieving discomfort in the early swelling stage of the deformity, although no benefit in prevention or correction of deformity.[222] If the deformity warrants correction, surgery is required. Benatar has reported the correction of the deformity by early release of the abnormal component of the long flexor tendon insertion.[219] If the epiphysis remains open, another option is to perform a dorsal hemiepiphysiodesis or resect a dorsal wedge including the dorsal growth plate to prevent progression of the deformity.[223] For the mature deformity, corrective osteotomies have been used to improve the alignment of the phalanx and corresponding nail growth (Fig. 36.93). The deformity has been addressed with a dorsal closing wedge osteotomy, although this has risk of nail bed injury given

77) O retalho utilizado na imagem para cobertura da extremidade do polegar é o retalho de _____ baseado na artéria _____

a) Quaba modificado, digital volar ulnar do polegar
b) Kite, digital dorsal ulnar do polegar
c) Brunelli, digital dorsal ulnar do polegar
d) Quaba, digital volar ulnar do polegar

Resposta C

referência Green página 1853

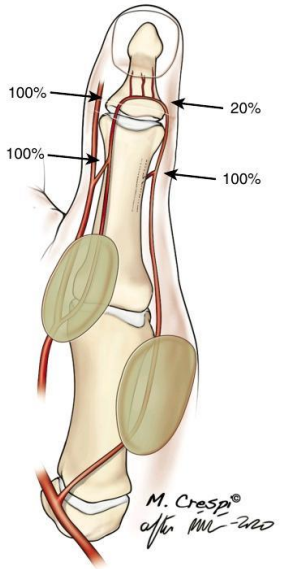

Fig. 48.5 Arterial disposition of the dorsal arteries of the thumb. Note that the radial dorsal digital artery only reaches the nail fold arcade in 20% of the cases, while on the ulnar side, this connection is constant. (Copyright © 2020, Dr F. Piñal.)

generous subcutaneous tunnel. The flap is sutured in position and the incisions are closed loosely on the dorsum of the hand. The tourniquet is now released. I prefer to assess the vascularity of the flap only after it has been sutured onto its final position. Doing otherwise will not rule out the possibility of later necrosis due to pedicle kinking by a fascial band or constriction in the tunnel. After hemostasis of the bed, a full-thickness skin graft is applied and dressed under a tie-over bolus on the proximal phalanx. I keep this dressing for 7 to 10 days unless drainage or inflammation appear.

The flap is particularly indicated for dorsal thumb defects. The use of the flap in volar defects is controversial. According to Foucher and Braun,[22] thumb pulp defects "will not be well served" by the kite flap because of the problem of cortical reorientation. Trankle et al., however, found this not to be a problem in their series, and in fact in a later publication the authors consider this flap first choice for thumb pulp defects.[24] Others have applied the kite flap for small defects in the palm or in the first web.[7,25]

I do not consider this flap applicable for pulp defects, but probably it is a suitable indication in older people.[24] The donor site can be (if large) a source of hypertrophic scarring and painful ulcerations. To prevent this from happening the flap should not trespass the MCP or PIP joint creases; furthermore, the peritenon should be left intact. The kite flap plays an indisputable starring role for dorsal thumb defects combined with venous outflow difficulties (Fig. 48.8).[26]

Heterodigital island flap (Littler flap). Although in purity the kite flap could also be considered an heterodigital island flap, the name is reserved for the flap described by Littler.[27]

The flap is taken from the ulnar aspect of the middle finger and transposed under a tunnel to the pulp area of the thumb, based on its neurovascular bundle, thus providing sensibility to the pulp. Classically, the flap was the last stage after a neo-thumb reconstruction with

Fig. 48.6 Brunelli flap reconstruction of the dorsal thumb. **A,** Squamous cell carcinoma of the nail bed. **B,** Total excision of the nail complex and distal phalanx dorsal cortex with clear surgical margins. **C,** Marking of the flap and the course of the dorsoulnar artery of the thumb pedicle. **D,** Elevation and rotation of the flap. **E,** Flap inset and closure of the donor site with a rotation flap. **F,** Results 6 weeks after surgery.

78) No estágio II de Curtis, a estrutura seccionada é o

a) ligamento triangular
b) ligamento retinacular obliquo
c) tendão extensor terminal
d) ligamento retinacular transverso

Resposta D

referência Green página 202

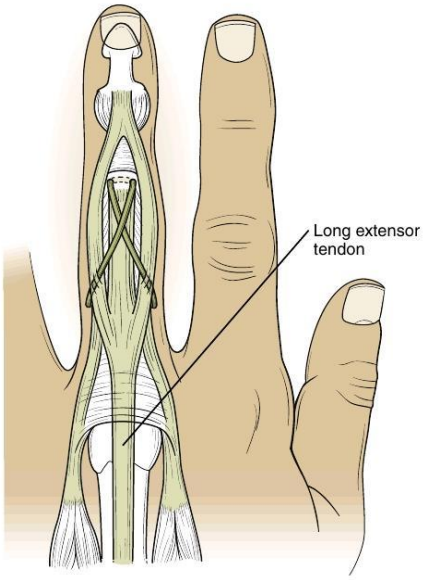

Fig. 5.25 The Littler tendon graft technique. A thin graft is woven through the base of the middle phalanx and through the extensor tendon to restore extensor tone to the PIP joint.

the middle phalanx described by Littler[88] (Fig. 5.25). Full preoperative passive mobility of the PIP joint is required for success.

Lateral band mobilization and relocation. The lateral bands normally move in a dorsal-palmar direction with PIP joint flexion and extension. Division of one lateral band at the level of the DIP joint and transferring it to augment the central slip insertion has been described with mixed results.[82,89-92]

AUTHOR'S PREFERRED METHOD OF TREATMENT: CHRONIC BOUTONNIÈRE DEFORMITY

In patients with fixed PIP flexion deformities and fixed DIP hyperextension, the major complaint may be the inability to flex the DIP joint and a tender palmar DIP joint caused by direct pressure when gripping. In such patients, a dolphin or terminal extensor tenotomy may be all that is necessary, assuming they accept no improvement of the PIP flexion contracture. For patients who desire both improvement of the PIP extensor lag and DIP hyperextension, I prefer the technique of Curtis, a stepwise surgical procedure. There are three stages of the Curtis procedure, depending on the correction obtained at each step (Fig. 5.26).[93] All are done under awake anesthetic, and all rely on full passive preoperative PIP joint motion. The use of local anesthetic allows the surgeon to test active extension at each stage.

In stage I, a lazy "S" incision is made centered on the PIP joint. The transverse retinacular ligaments are freed distally and proximally by inserting a probe or clamp underneath them, and a tenolysis of the extensor tendon is performed. If full active PIP extension is enabled, the operation stops; this rarely occurs.

In stage II, the transverse retinacular ligaments are sectioned, allowing the lateral bands to swing dorsally. If full extension is achieved (seen in 30%–40% of Curtis's cases), the MP joint is splinted at 70 degrees of flexion, the PIP and DIP joints are splinted at 0 degrees for 1 week, and then dynamic PIP joint splinting is performed.

In stage III, if there is still a 20-degree or smaller lag after stage II, a distal Fowler tenotomy is performed. Curtis recommended a "step-cut lengthening" of the lateral bands to prevent a mallet finger. I usually just obliquely transect the extensor mechanism distal to the triangular ligament. If full extension is present, the operation stops.

If an extensor lag of more than 20 degrees is still present after stage II, Curtis recommended proceeding directly to stage IV (necessary in 38% of his cases). The central tendon is dissected free and advanced about 4 to 6 mm into a drill hole in the dorsal base of the middle phalanx or to the tendon remnant. The lateral bands, now slack, are loosely sutured to the central tendon.

Curtis's results at 1 year of follow-up revealed a 10-degree PIP joint lag, with an average 31-degree improvement from the preoperative status.[93] For patients requiring stage IV reconstruction with an average PIP joint preoperative lag of 55 degrees, a 17-degree lag persisted postoperatively. All but 3 of 23 patients showed improved flexion after the procedure.

CRITICAL POINTS

Treatment of Chronic Boutonnière Deformity

- Exhaust the splinting protocol before surgical correction.
- Ensure full passive PIP joint motion before embarking on any tendon rebalancing or reconstructive procedure.
- A stepwise approach (Curtis procedure) is a rational solution to the problem.

Expected Outcomes

- A 20-degree persistent extensor lag is common, and surgery for PIP joint extensor lags of 20 to 30 degrees may not result in significant improvements. Although flexion loss is possible postoperatively, it is uncommon using the stepwise approach (Curtis procedure).

Zone 4 Injuries

Because of the convex bony contour of the proximal phalanx, dorsal lacerations are frequently associated with partial tendon injuries. Fractures of the proximal phalanx are commonly seen in association with these injuries. Similar to tendon injuries in other locations, the ideal method of evaluating the extent of injury is by surgical exploration. Partial lacerations of greater than 50% and complete tendon lacerations are repaired with one or two modified Kessler 4-0 core braided polyester sutures and a 5-0 cross-stitch on the dorsal side of the tendon.[24,94] The core suture should be placed into the relatively thicker area of the lateral bands to obtain maximal purchase (see Fig. 5.13). Early motion protocols to prevent adhesions to the proximal phalanx involve the use of a dynamic extension splint to allow PIP joint flexion. The postoperative splint includes a dorsal outrigger with elastic straps to provide passive PIP joint extension (see Fig. 5.15). The degree to which the PIP joint can be safely flexed is determined during surgery by observing repair site tension. Accelerated rehabilitation protocols generally begin within the first week of repair. If treated with immobilization, the PIP and MP joints are maintained in extension for 4 weeks, followed by range-of-motion exercises.

Zone 4 in the thumb lies over the metacarpal. In this zone, the tendons are typically wide and round enough to perform a standard core-type repair with a 3-0 or 4-0 suture, followed by a 5-0 cross-stitch.

79) As estruturas representadas pelas letras A,B,C,D e E são respectivamente:

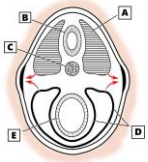

a) Mesoderma somático, notocorda, endoderma, ectoderma e mesoderma lateral
b) Corda espinhal, notocorda, mesoderma somático, endoderma e mesoderma lateral
c) Mesoderma somático, corda espinhal, notocorda, mesoderma lateral e endoderma
d) Corda espinhal, mesoderma somático, notocorda, endoderma e mesoderma lateral

Resposta C

referência Green página 1364

TABLE 35.1 **Key Milestones in the Development of the Human Upper Limb**[a]

Week	Day	Upper Limb	Lower Limb
4	24	Swelling appears in region of upper limb bud	
	28	Scattered blood vessels	Appearance of lower limb bud
5	32	Upper limb AER	
		Early marginal vessel	
		Early brachial plexus development	
	33	Hand plate appears	Lower limb AER
		Humeral mesenchymal condensations	
6	37	Humeral chondrification	Lumbosacral plexus
		Radial and ulnar mesenchymal condensations	
		Brachial plexus with radial, median, and ulnar nerves to the elbow	
		Early muscle masses	
	41	Finger rays (webbed)	Mesenchymal condensations of femur, tibia, fibula, and tarsus
		Radial, ulnar, and metacarpal chondrification	
7	44	Interdigital apoptosis	Chondrification of femur, tibia, and fibula
		Scapular and humeral head chondrification	
		Chondrification of carpals and proximal phalanges	
		Trapezius innervated (accessory nerve)	
		Major muscles distinguishable	
	48	Chondrification of middle phalanges	
		Shoulder and elbow interzones (joint cavity formation)	
8	51	Chondrification of distal phalanges	
	52	Ossification of humerus	
		Ossification of radius	
		All muscles distinguishable	
		Wrist and carpal interzones	
	54	Ulnar ossification	Ossification of femur and tibia
	57	Scapular ossification	Ossification of fibula
		Intramembranous ossification of distal tip of distal phalanges	Chondrification of tarsus and digits

AER, Apical ectodermal ridge.
[a]Selected milestones for the lower limb are provided for comparison.
Adapted from O'Rahilly R, Gardner E. The timing and sequence of events in the development of the limbs in the human embryo. *Anat Embryol (Berl)*. 1975;148(1):1–23.

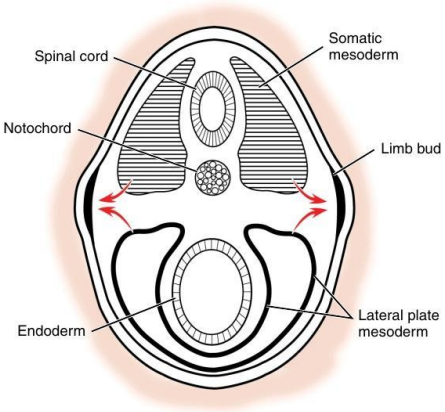

Fig. 35.1 Axial view of an embryo. The lateral plate mesoderm forms the bone, cartilage, and tendon, and the somatic mesoderm forms the muscle, nerve, and vascular elements of the limb. (Adapted from Riddle RD, Tabin C. How limbs develop. *Sci Am*. 1999;280[2]:74–79.)

80) No procedimento de Paneva-Holevich, inserimos na falange distal o tendão

a) flexor superficial
b) palmar longo
c) flexor profundo
d) plantar delgado

Resposta A

referência Green página 241

CRITICAL POINTS

Single-Stage Tendon Grafting: Flexor Digitorum Profundus Tendon Disrupted, Flexor Digitorum Superficialis Tendon Intact (Chronic Zone 1 FDP Injury)

Indications

- Young person with supple joints and a reasonable need for active DIP joint function
- More useful on the ulnar side of the hand for power grip
- DIP joint that is unstable but supple

Preoperative Evaluation

- Document absence of FDP function.
- Evaluate the DIP joint for instability.
- MRI or ultrasound may be useful to determine the location of the proximal FDP stump.
- Later repair is possible if a short vinculum to the FDP tendon maintains the proximal tendon in close proximity to the distal stump.

Pearls

- Never remove an intact, fully functioning FDS tendon in an effort to place a graft.
- Tenolysis of the FDS tendon may be necessary.
- The procedure may be done in one or two stages, depending on the condition of the flexor tendon sheath.
- The graft must be accurately oriented through the decussation of the FDS tendon, or a single FDS slip should be removed.
- The proximal motor for the graft is usually the FDP tendon of the same finger, with the proximal juncture done just distal to the lumbrical origin.
- For some cases a more proximal tenolysis of the FDP motor must be done to improve the tendon excursion.

Technical Points

- Use a similar technique as in free tendon grafting.
- Know that a thinner graft is easier to pass (EDM or plantaris).
- Pass the graft through the FDS tendon decussation.
- One FDS tail can be removed for tendon graft passage if the graft is too bulky to pass.

Pitfalls

- Patients should be selected for the goal of restoring the specific function of grip.
- Patients with an intact FDS tendon usually adapt nicely and require no treatment.
- Digital scarring can be heavy and result in adhesions, loss of motion, and further functional impairment.

Postoperative Care

- Apply a static dorsal blocking splint (4 to 6 weeks) with the wrist in neutral position, MCP joints at 45 degrees, and IP joints in neutral position.
- Use an early motion protocol if the graft junctures are secure.
- Treat flexion contractures with passive stretching and splinting (6 to 8 weeks).

The index procedure is followed by placement of a tendon graft at a second operation, which is usually done 6 to 12 weeks after the index operation.

Tissue response to a silicone implant. The nature of the sheath formed by silicone and other materials has received significant investigation. Hunter's group,[213,214] working in the late 1960s, observed an orderly pattern of cellular organization on the surface of the implant when silicone implants were placed in the paravertebral soft tissues of dogs. A parallel study evaluated the response to an actively gliding implant in the extensor system of dogs and showed that the system could function as a physiologic sheath capable of supporting a long tendon graft initially by synovial fluid nutrition and subsequently via mobile vascular adhesions. Urbaniak and colleagues[194] performed experiments in the flexor system and confirmed revascularization of tendon in dogs by intratendinous vessels within the sheath. Farkas and colleagues[147] reported ultrastructural evidence of a normal-appearing reconstituted tendon sheath in chickens, and also concluded that motion was important for remodeling.

The nature of the sheath created in response to a flexible silicone implant used in a passive-gliding program in humans is still debated. Some of the varying observations may be a result of different species and experimental conditions. Most commonly the silicone rod placement is associated with the formation of a soft, flexible, translucent sheath, which is suitable for supporting the purpose of tendon grafting. In a series of 109 digits, the reported complications from silicone rod implantation during stage 1 included rod buckling, rupture of the distal end of the rod, rod migration, synovitis, and infection.[100]

Alternative techniques. Other researchers have investigated alternative techniques for reconstruction.[215] In the staged technique published by Paneva-Holevich in 1969,[216] the damaged tendons are removed from the flexor sheath and transected in the palm (Video 6.3). The cut ends of the FDS and FDP tendons are sutured in the palm to create the proximal tendon juncture. Approximately 6 weeks later at a second stage, the FDS tendon is severed at the muscle-tendon junction in the forearm and passed distally through the tendon sheath to be attached to the distal phalanx or distal FDP tendon. Although this procedure results in a finger with one tendon, it has the advantage of requiring a single distal repair at the second stage and may transplant an intrasynovial tendon segment of the FDS to the digital sheath. This can be a good solution for severely injured fingers, especially in patients with limited tendon donor options. Later, this method was combined with implantation of a silicone prosthesis during the first stage to prepare a bed for the subsequent distal pedicle transfer[217-220] (Fig. 6.35). The relatively larger size of the FDS tendon compared with a conventional tendon graft may require the use of a silicone rod with a larger diameter.

Composite tissue transfer methods. Peacock[221] showed that a transplanted allograft of the entire flexor system, tendon, and sheath was well tolerated in three digits in four patients, but no range-of-motion details were provided. Hueston and colleagues[222] also presented a clinical series of three cases using homografts, although no clinical results were reported, and the technique was not widely adopted. In 1974 Chacha[202] used autologous composite grafts from the toe to the flexor system of the hand with only modest results. More recently, Asencio and associates[223] implanted human composite flexor tendon allografts into two fingers with irreparable injuries of the flexor tendon system. Although none of these methods has current clinical applicability, they are interesting to consider and may represent fertile ground for future tissue engineering research. Some of the biggest future improvements will likely come from tissue engineering strategies.

Permanent (active) tendon implants varying in size, shape, material, and type of end device for distal and proximal fixation have been reported in the literature. Unfortunately, biologically durable bonding between the tendon implant distal to bone and proximal to native tendon has not been reliably achieved. Basic science researchers continue to search for a permanent active tendon implant.[185]

81) O procedimento de marsupialização é realizado

a) na polpa digital
b) no eponíquio
c) no hiponíquio
d) no leito ungueal

Resposta B

referência Green página 25

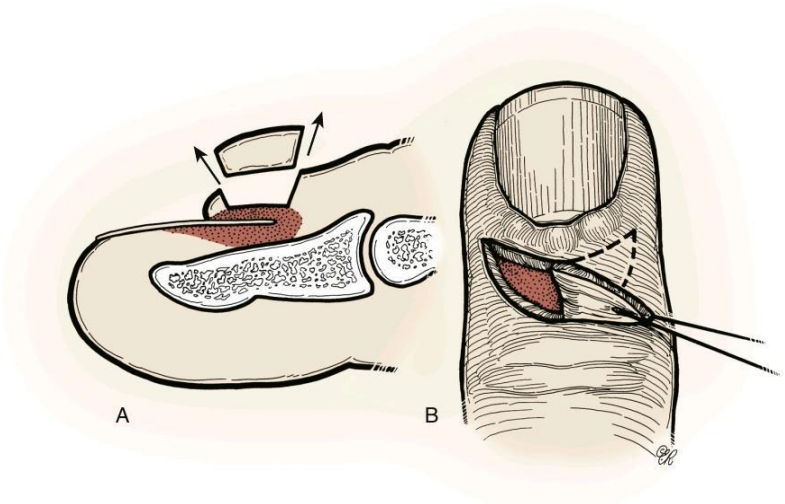

Fig. 2.6 Eponychial marsupialization for chronic paronychia. **A,** Lateral view showing the area of wedge-shaped excision. Undisturbed matrix is stippled. **B,** Dorsal view of the crescent-shaped area of excision extending to the margins of the nail folds on each side.

Treatment

Conservative therapies for chronic paronychial infection have included topical corticosteroids, topical tacrolimus, oral and topical antibiotics, and oral and topical antifungal agents. Although reducing exposure to moist environments and chemical irritants may be helpful, these treatments alone have been uniformly unsuccessful.[42,44] Studies from the dermatologic literature found that topical corticosteroids and even topical tacrolimus are more effective than topical antifungals, implicating the relative importance inflammatory element over the mycological component.[41,45]

Operative treatment. Eponychial marsupialization is the most common surgical treatment for the chronic paronychium. Under digital block anesthesia and tourniquet control, a crescent-shaped incision is made beginning 1 mm proximal to the distal edge of the eponychial nail fold and extending proximally for 3 to 5 mm. Some authors recommend removal of all thickened tissue. Others have found a 3-mm margin adequate to achieve equal results. The crescent should be symmetrically shaped and extend to the edge of the nail fold on each side (Fig. 2.6). The crescent of tissue is removed down to but not including the germinal matrix. The wound is left open and allowed to drain. If nail deformity is present, removal of the nail has been reported to improve the cure rate and reduce the risk of recurrence.[42] Pabari and colleagues have described elevation of the nail fold, inverting and folding this tissue over a nonadherent gauze, and anchoring the inverted skin proximally with a nonabsorbable suture. Anchoring sutures are removed between 2 and 7 days, and the nail fold is allowed to return to its original position[46] (Fig. 2.7).

Fig. 2.7 Alternative technique of nail marsupialization for chronic paronychia: the Swiss roll technique. (Copyright courtesy of Milan Stevanovic and Frances Sharpe.)

AUTHORS' PREFFERED METHODS OF TREATMENT: CHRONIC PARONYCHIA

We have found eponychial marsupialization an effective treatment for chronic paronychia recalcitrant to nonoperative management. We agree with Bednar and Lane[42] that a 3-mm crescent of tissue is adequate, and removal of all thickened tissue is not critical to the outcome. Special care is used to avoid injury to the germinal matrix. The removed tissue is sent for bacterial, fungal, and mycobacterial culture. The remaining tissue is sent for pathologic examination. Nail removal is performed when a nail deformity is present. Wounds are covered with Xeroform® (absorbent, fine-mesh gauze impregnated with a petrolatum blend; 3% bismuth tribromophenate) gauze. When the nail is removed, Xeroform gauze is placed in the nail bed and nail fold as well.

Patients are instructed to avoid moist environments. Predisposing systemic conditions, such as diabetes and psoriasis, are medically controlled. We inquire about activities that may lead to mycobacterial exposures, such as home aquariums or terrariums, marine work, or aviary exposure.

82) A paralisia cerebral pode levar a uma instabilidade cárpica

a) escafo-semilunar
b) semiluno-piramidal
c) adaptativa
d) complexa

Resposta C

referência Green página 501, 502

TABLE 13.2 Analysis of Carpal Instability

Category I: Chronicity	Category II: Constancy	Category III: Etiology	Category IV: Location	Category V: Direction	Category VI: Pattern
Acute, >1 week (maximum primary healing potential)	Occult	Congenital	Radiocarpal	VISI rotation	Carpal instability dissociative (CID)
Subacute, 1 to 6 weeks (some healing potential)	Dynamic	Traumatic	Proximal intercarpal	DISI rotation	Carpal instability nondissociative (CIND)
Chronic, >6 weeks (little healing potential)	Static reducible	Inflammatory	Midcarpal	Ulnar translation	Carpal instability complex (CIC)
	Static irreducible	Neoplastic iatrogenic	Distal intercarpal	Dorsal translation	Carpal instability adaptive (CIA)
		Miscellaneous	CMC	Other	
			Specific bones		

CMC, Carpometacarpal; *DISI*, dorsal intercalated segmental instability; *VISI*, volar intercalated segmental instability.
Modified from Larsen CF, Amadio PC, Gilula LA, Hodge JC. Carpal instability analysis: I. *J Hand Surg Am* 20(5):757–764, 1995.

clinical findings consistent with carpal instability (Table 13.2). While not a classification system per se, the authors propose that consideration of each category will allow any instability pattern to be uniquely characterized and recorded, facilitating clinical reporting and ultimately treatment and prognostic recommendations.

The first three categories are prognostic, including the relative chronicity of the injury (acute, subacute, or chronic); the severity of the injury (dynamic, static, or fixed); and the etiology (traumatic, congenital, acquired, etc.). The next two are radiographic and describe the involved joints or carpal bones as well as the direction of malrotation (dorsal, volar, ulnar). The final category is descriptive, based on classes of instability (dissociative, nondissociative, complex, or adaptive). The authors' goal to provide an "exhaustive system" to describe a wide variety of conditions was met, and it is critical that each category be considered in the evaluation and management of each patient with carpal instability. The system is not, however, fully inclusive and as such has not been readily incorporated into clinical outcome studies. It is not possible, for instance, to categorize a patient with chronic reducible dissociative DISI pattern with dorsal scaphoid translation into "proximal intercarpal," "radiocarpal," or "midcarpal," as all three joints and their corresponding ligaments are involved.

For the traumatic instabilities reviewed in this chapter, the sixth category is particularly important to examine and understand, as there are four major instability patterns of the wrist (Table 13.3). The first group includes the so-called dissociative carpal instabilities, also known as carpal instability dissociative (CID), in which the predominant dysfunction (i.e., ligament rupture or insufficiency) occurs between bones of the same carpal row.[60,73] Most CIDs occur between the scaphoid and lunate and less often between the lunate and triquetrum. Dissociative instabilities seldom occur between the bones of the distal carpal row, as there is little mobility between them.

The second group includes the nondissociative carpal instabilities, also known as carpal instability nondissociative (CIND).[16,36,75,76] This group includes radiocarpal, midcarpal, and combined radiocarpal-midcarpal (or proximal row) instabilities. If the entire carpus is translocated with respect to the radius in any direction, this is radiocarpal instability.[77,78] If the proximal carpal row as a unit collapses and becomes unstable, either in flexion or extension, this is a combined radiocarpal and midcarpal instability, a condition that is more concisely termed nondissociative instability of the proximal carpal row, or more simply, proximal row instability.[75,76] While most frequently associated with ligament laxity, a severe, posttraumatic variety of CIND has recently been described, associated with acute fractures of the radius[79,80] or scaphoid.[63,73] Less frequently, there are cases (e.g., capitolunate instability pattern [CLIP])[81] where there is only a dysfunction at the midcarpal level, the radiocarpal joint being uninvolved, and the proximal carpal row aligned normally. The authors recommend that only these rare cases be referred to as "midcarpal" instabilities.[30]

TABLE 13.3 Major Patterns of Carpal Instability

Pattern	Subtype	Features
Carpal instability dissociative (CID)	Scapholunate dissociation	Rotatory subluxation Scapholunate diastasis Dorsal scaphoid translation DISI
	Lunotriquetral dissociation	LT dissociation VISI
Carpal instability nondissociative (CIND)	Radiocarpal	Dorsal, ulnar, volar
	Combined midcarpal/radiocarpal	VISI, DISI
	Traumatic proximal row	VISI, DISI
	Midcarpal	CLIP, CCI
Carpal instability complex (CIC)	Carpal dislocations	Radiocarpal/intercarpal
	Combined intercarpal/radiocarpal	Type 2 ulnar translocation
	Axial disruptions of the carpus	Axial-ulnar Axial-radial Axial-radial-ulnar
Carpal instability adaptive (CIA)	Distal radius malunion Neuromuscular conditions	VISI, DISI nondissociative

The third group of instabilities is formed by the so-called carpal instability complex (CIC), where there are features of both CID and CIND types. Carpal dislocations, if treated inadequately, may generate complex (i.e., CIC) patterns of instability where the dysfunction affects both the radiocarpal and the proximal row intercarpal joints. With time, however, the untreated or incompletely reduced carpal derangement may evolve into a stiff malaligned joint. Dissociative instabilities between the columns of the wrist are rare, involving bones of the proximal and distal carpal rows, and by necessity the radiocarpal, intercarpal, and midcarpal joints. These are usually the result of a violent dorsopalmar crushing mechanism.[33] These complex dissociative injuries present as axial disruptions of the carpus[66] and are analogous to Lisfranc fracture-dislocations of the midfoot.

The final group, or "carpal instability adaptive" (CIA), refers to cases of carpal malalignment not secondary to an intercarpal injury or radiocarpal/midcarpal ligamentous injury, but rather to a condition outside of the carpus. The most frequent type of CIA is the carpal malalignment that occurs when an otherwise normal carpus adapts to

a malunited, nonarticular distal radius fracture. The entire proximal carpal row follows the malunited articular surface and remains aligned with it, producing an apparent DISI or VISI deformity with respect to the *shaft* of the radius. The proximal row is also malaligned with respect to the distal carpal row, which is aligned with the metacarpals. It is important to note that the interosseous relationships of the proximal row remain normal and that patients are generally asymptomatic with respect to their carpal malalignment. These malalignments frequently reduce when the deformity is recognized and treated promptly, but may persist in chronic or neglected cases. Neuromuscular conditions (cerebral palsy, stroke) can also create an imbalance of forces (through disruption of normal sensorimotor pathways) that leads to postural deformities of the proximal carpal row. Further discussion and treatment of adaptive carpal instability patterns will be discussed in Chapter 15 and Chapter 32.

Diagnosis and Treatment

Patients with wrist disorders present in a spectrum of ways, ranging from the atraumatic to those involved in high-energy trauma such as a motor vehicle accident. Accurate diagnosis of their condition is critical to prevent carpal dysfunction. The mnemonic SCARCE may be helpful when assessing patients with wrist dysfunction and suspected carpal instability.

S for integrity of the critical **s**tabilizers
C for **c**arpal alignment
A for **a**cuity of injury (acute, subacute, or chronic)
R for **r**educibility of the carpus
C for the status of the articular **c**artilage (healthy versus degenerative)
E for the **e**xtent of the ligament injury (partial versus total or volar versus dorsal versus complete tear)

Assessment of the Symptomatic Wrist

The natural inclination to study radiographs or special imaging studies and reports *prior* to a thorough history and physical examination should be avoided, as this introduces cognitive bias, which can affect one's thinking and decision making. Doing so may save time in the short term but may lead to diagnostic and treatment errors. Similarly, physical examination always needs to be preceded by a thorough investigation of the patient's medical history, with special emphasis on the mechanism of injury and acuity. The patient should be asked details about the location, duration, and characteristics of any pain, including aggravating and relieving factors and previous treatments, if any. With chronic problems, it is also important to inquire about the patient's jobs and hobbies, and whether there has been exposure to repetitive stress, vibrating tools, or potentially dangerous instruments. Elucidating a history of ligamentous laxity or multiple joint instabilities, especially in younger patients presenting with chronic wrist pain, is also important. Such an evaluation should also include an assessment of their stress coping skills.

Examination. Except in cases with an open dislocation, the external appearance of most wrist dislocations may not be dramatic. Swelling is generally moderate, and bone displacements may be evident only if the patient is seen immediately after experiencing trauma. If there has been a delay since the accident, swelling may have increased substantially, making visualization of the displaced bones more difficult. When present, skin abrasions, contusions, or ecchymosed areas may be helpful in determining the mechanism of injury and the potential areas of damage.

ROM is usually limited by pain in acute injuries, whereas it may be reduced or normal in more chronic cases. In the latter, passive assessment of mobility is valuable not only in determining the presence of abnormal motion or crepitus but also in reproducing the patient's pain. The physician should also record the motion in the contralateral, uninjured wrist for comparative purposes.

Palpation for areas of maximal tenderness is one of the most useful tools in the diagnosis of wrist pathology, especially in patients with chronic dysfunctions.[82,83] In acute dislocations, because of extensive soft tissue damage, tenderness is seldom elicited at specific points but rather in a diffuse manner. Nonetheless, palpation should always be performed in a methodical way, starting from the basal joint of the thumb and proceeding across the proximal carpal row from the scaphoid to the triquetrum and continuing from the hamate (and its hook) back across the distal row and CMC joints, ending with provocative clinical maneuvers as needed (see below).

A careful assessment of neural and vascular status is imperative, with particular attention being paid to the median and ulnar nerves, which may be injured by direct contusion at the moment of impact, by compression from displaced bones or by swelling within the carpal canal.

Provocative maneuvers. A thorough set of provocative maneuvers should be performed, not just to concentrate on the suspected diagnosis but specifically to rule out alternative or even concurrent diagnoses. More complete descriptions of these tests follow in each treatment section. One's examination should be methodical and follow a routine so that all potential diagnoses are considered. In general, starting in an area away from the point of maximal tenderness is an ideal way to gain a patient's confidence and to avoid emotional reaction or withdrawal, which may preclude a thorough examination. In a fashion similar to palpation, the examination should begin in a nontender area and proceed rotationally around the carpus, ending at the most symptomatic area. A typical examination would begin at the radial column, with an assessment of stress instability of the thumb basal joint, moving to Watson's scaphoid shift test at the scaphoid tubercle (page 509), Finkelstein and Eichhoff maneuvers for first dorsal compartment tendinopathy (Chapter 56), and manually resisted flexion/radial deviation of the wrist to test for flexor carpi radialis tendinitis (Chapter 56). The examination then proceeds to ballottement and shear tests for LT instability (page 510). Tendinopathy of the ECU is ruled out with the synergy test (Chapter 56), and frank ECU instability with supination while maximally flexed and ulnar deviated (Chapter 14). The TFCC must be carefully examined, and the distal radioulnar joint must be assessed for instability in neutral, supination, and pronation. Ulnar impaction and ulnar styloid impingement must be assessed in pronation and supination, and osteoarthritis by compression testing (Chapter 14). Finally, resisted ulnar flexion can help rule out FCU tendinopathy and accompanied by a pisotriquetral "shuck" test for synovitis or osteoarthritis. Nondissociative instability of the carpus is next assessed with Lichtman's midcarpal shift test and the associated "catch up clunk" (page 539), as well as Louis' CLIP maneuver for midcarpal instability (page 542). This examination is by no means comprehensive, but performance of such a routine on normal and injured wrists will increase the examiner's diagnostic expertise.

Objective testing. Bilateral grip and pinch strength are useful to uncover underlying pathology in chronic cases. Strength may be diminished due to muscle atrophy, pain inhibition, or learned behaviors. Rapid alternating grip assessment may be helpful in determining voluntary effort. A local injection of anesthetic to a painful joint or selected tendon sheath may help normalize the dynamometer readings and narrow the diagnostic spectrum. Sensory testing should always accompany an examination of suspected nerve compression, using threshold (Semmes Weinstein or von Frey monofilaments) or density testing (static and moving two-point discrimination) (see Chapter 28).

Patient-reported outcome measures. Patient-reported (or patient-related, patient-rated) outcome measures (PROMs) represent a rapidly

83) O procedimento representado abaixo é o de

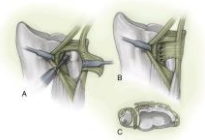

a) Sauvé-Kapandji
b) Darrach
c) Brian Adams
d) Bowers

Resposta D

referência Green página 587

of the TFCC. The procedure, which Bowers called the hemiresection–interposition technique, was derived from Dingman,[165] who found the best clinical results of the Darrach procedure occurred in patients who had minimal distal ulnar resection that was followed by regeneration within the retained periosteal sleeve. The primary indication for the hemiresection–interposition technique is posttraumatic or degenerative arthritis of the DRUJ. It may be useful also in patients with severe DRUJ contractures complicated by articular degeneration, which may not be discovered until the surgical release. Caution should be observed before using this procedure for the treatment of combined DRUJ arthritis and instability because often the instability will be exacerbated.

Resection procedures in younger patients are less reliable because the procedure may help relieve pain but may cause a loss of support for the ulnar carpus over time. Because some convergence of the radius and ulna occurs after partial resection of the ulnar head, ulnar-positive variance is a relative contraindication because it increases the likelihood of impingement between the ulnar styloid and triquetrum. Also, ulnar carpal translation may be a contraindication to partial or complete excision of the ulnar head because the resection may exacerbate the translation. Irreparable damage to the TFCC is a relative contraindication because the hemiresection–interposition technique would provide no theoretical benefit over a Darrach procedure.

In his original and modified techniques, Bowers[138] created several retinacular flaps to reconstruct the capsule and to stabilize the ECU. The arthroplasty may be augmented with a tendon or muscle interposition when local soft tissue is insufficient. The matched distal ulnar resection described by Watson and Gabuzda[166] is a similar alternative. Though the authors do not stress preservation of the TFCC and ulnocarpal ligaments, it is advisable to do so. The concept is to remove all of the articular cartilage and subchondral bone on the radial and dorsal margins of the distal ulna so as to prevent radioulnar impingement during forearm rotation. An intact periosteal sleeve is preserved to maintain continuity with the ulnar carpus, and the exposed cancellous bone encourages strong healing to the surrounding soft tissue sleeve.

AUTHOR'S PREFERRED METHOD OF TREATMENT: HEMIRESECTION–INTERPOSITION TECHNIQUE ARTHROPLASTY

A slight modification of Bowers' procedure is used involving less resection of the ulnar head with stabilization of the retinaculum and capsular flaps within the resection site to create both interposition and stabilization (Fig. 14.31). Theoretically, by resecting less of the ulnar head, the amount of potential radioulnar convergence is reduced. The seemingly increased risk of developing distal radioulnar bony contact is offset by the increased stability imparted from capturing a larger circumference of the distal ulna with a large capsular-retinacular flap, and it does not preclude adding free soft tissue for added interposition when desired.

The DRUJ is approached dorsally through the fifth extensor compartment in a manner similar to that described earlier for TFCC repair and distal radioulnar ligament reconstruction. An ulnar-based retinacular flap extending to the radial edge of the ECU sheath is elevated; its proximal margin is at the ulnar neck, and its distal margin is at the level of the ulnar styloid. The dorsal capsule is raised similarly as a large rectangular flap, with its base extending from the radial edge of the ECU sheath (the ECU sheath is not opened in this procedure). The flap begins over the ulnar neck, continues along the rim of the sigmoid notch and courses ulnarly, immediately proximal to the dorsal radioulnar ligament. Care is taken not to cut or to destabilize the dorsal radioulnar ligament.

Exposure of the distal surface of the TFCC or carpus is not indicated, unless symptomatic pathology is suspected. Small rongeurs are used to resect the surface of the ulnar head that articulates with the sigmoid notch to a depth of 3 to 7 mm; the depth of resection is guided by the size of the ulnar head. The head is shaped to resemble a dowel with approximately the same diameter as the ulnar neck. Slight distal tapering is done, but the fovea is not violated and the TFCC insertion is preserved. To reach the volar portion of the head, the radius and ulna are spread with strong retraction, or a laminar spreader is placed proximal to the DRUJ. The proximal surface of the TFCC and the remaining ulnar dome are inspected for degeneration and debrided if necessary.

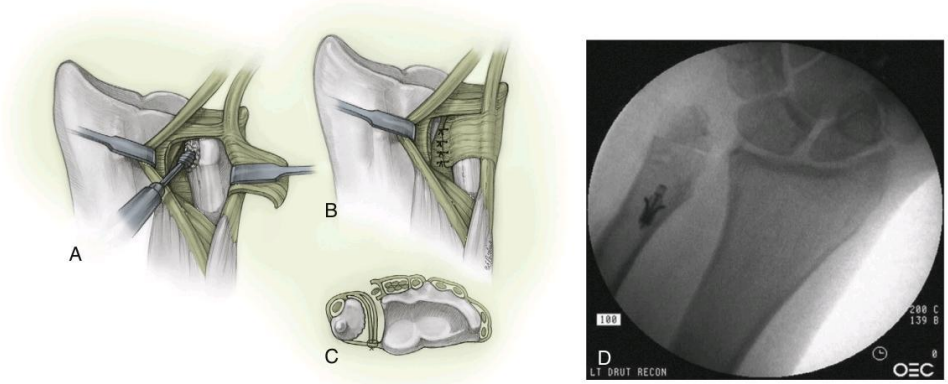

Fig. 14.31 **A** to **C,** Hemiresection arthroplasty of distal ulna with soft tissue interposition for arthritis of distal radial ulnar joint (DRUJ). In this modification of the procedure described by Bowers, a single, broad dorsal flap composed of extensor retinaculum and dorsal DRUJ capsule is used for interposition and stabilization (see text). **D,** Concomitant interarticular ulnar-shortening osteotomy has been fixed with embedded suture anchor. (**A** to **C,** Copyright © Elizabeth Martin.)

84) A fratura-luxação radiocárpica é classificada por Fernandez como tipo

a) I
b) II
c) III
d) IV

Resposta D

referência Green página 615

Fracture type	Number of fragments	Associated injuries (nerve, tendon, ligament, skeletal trauma)	Recommended treatment
Type I Bending fracture of the metaphysis	Two-part ± metaphyseal comminution	Rare	Stable: Nonoperative Unstable: Percutaneous pinning External fixation Volar locked plate Intramedullary fixation
Type II Shear fracture of the articular surface	Two-part Three-part Comminuted	Infrequent chauffeur: Suspect scapholunate interosseus ligament injury	Dorsal plate Radial columnar fixation Volar buttress or locked plate Combination
Type III Compression fracture of the articular surface	Two-part Three-part Four-part Comminuted	Common	Open or arthroscopic reduction of articular surface, and dorsal, volar, or fragment-specific fixation ± bone graft Augmented external fixation ± bone graft Spanning plate fixation
Type IV Avulsion fracture, radiocarpal fracture-dislocation	Two-part: Radial styloid Three-part: Styloid plus volar or dorsal margin Comminuted	Frequent	Closed or open reduction and K-wire or tension band fixation Columnar fixation Fragment-specific fixation Spanning plate fixation Assess carpal translation, treat accordingly
Type V Combined fracture (I-II-III-IV) High energy injury	Comminuted ± bone loss. Open injuries not uncommon.	Always	Angular stable fixation Fragment-specific fixation Spanning plate fixation Augmented external fixation Combination

Fig. 15.15 The Fernandez classification of distal radius fractures. (Copyright © Elizabeth Martin.)

85) Excluindo o escafóide, o osso do carpo mais fraturado é o

a) trapézio
b) triquetro
c) semilunar
d) pisiforme

Resposta B

referência Green página 714

CRITICAL POINTS

Fractures of the Triquetrum

Incidence

Second most common carpal bone fracture; approximately 15% of all carpal fractures

Classification

Type 1 Dorsal cortical fracture (see Fig. 16.41), most common
Type 2 Triquetral body fracture
- Medial tuberosity fracture
- Sagittal plane fracture
- Transverse proximal pole fracture
- Transverse body fracture
- Comminuted fracture

Type 3 Palmar cortical fracture

Mechanisms

Type 1 Dorsal cortical fracture
Mechanism 1: Extreme palmar flexion/twist with avulsion by dorsal ligaments: radiotriquetral (dorsal radiocarpal) and triquetroscaphoid (dorsal intercarpal) ligaments
Mechanism 2: Hyperextension and ulnar deviation during fall with impaction by ulnar styloid or hamate
Type 2 Triquetral body fracture
Medial tuberosity fracture (caused by direct blow)
Sagittal plane fracture (anterior-posterior crush injury or axial dislocation)
Transverse proximal pole fracture (perilunate injury)
Transverse body fracture (perilunate injury)
Comminuted fracture (due to high-energy trauma)
Type 3 Palmar cortical fracture
Avulsion of palmar ligaments (palmar ulnar triquetral or lunotriquetral ligament)
Shear from pisiform

Special Imaging

CT scanning still often necessary
Oblique, 45-degree pronated view for dorsal cortical fracture
Palmar cortical fracture may be a harbinger of carpal instability, and MRI may be helpful in further assessment

Treatment

Type 1 Dorsal cortical fracture
- Small fragment, no instability: wrist splint vs short-arm cast for 3 to 4 weeks, then wrist splint for comfort. Progressive range of motion and strengthening. Excision if symptomatic after 6 to 9 months
- Signs of carpal instability: ORIF

Type 2 Triquetral body fracture
- Nondisplaced body fracture: short-arm cast for 4 to 6 weeks
- Displaced body fracture: CRIF vs ORIF with compression screws and/or Kirschner wires
- Beware of associated lunotriquetral ligament injury. If lunotriquetral ligament is disrupted, pin across the joint

Type 3 palmar cortical fracture
- Small fragment, no instability: Wrist splint vs short-arm cast for 4 to 6 weeks
- Ligamentous avulsion with carpal instability: ORIF
- Shear from pisiform: short-arm cast for 4 to 6 weeks; excision of fragment and pisiform if injury remains symptomatic

Associated Injury

Perilunate fracture-dislocation
Axial pattern fracture-dislocations
Radius or ulna fractures

Complications

Nonunion
Persistent carpal instability
Pisotriquetral arthritis

nondissociative volar intercalated segment instability (VISI; see Chapter 13). Fractures of the body of the triquetrum associated with scapholunate instability are best managed by early primary repair of the ligamentous disruption and fixation of the triquetral fracture with Kirschner wire or a compression screw.

Palmar cortical fractures of the triquetrum are rare. MRI to evaluate the fracture pattern and involvement of potential carpal instability is recommended. Treatment should be directed toward restoring carpal stability rather than treating the small avulsion fragment.

Fractures of the Trapezium

The trapezium forms a set articulation for the base of the thumb metacarpal. Fractures of the trapezium constitute approximately 1% to 5% of all carpal bone fractures, making the trapezium the third most commonly fractured carpal bone in most authors' series.[216,217] The largest series of fractures of the trapezium was described by Pointu and colleagues, who reviewed 34 cases.[216] Fractures of the trapezium are usually associated with fractures of other bones, usually the distal radius or metacarpal. Isolated fractures occur rarely. Fractures of the trapezium typically involve the body or the ridge. The palmar ridge of the trapezium projects in a palmar direction and serves as an attachment for the transverse carpal ligament. The tendon of the FCR passes along a groove formed by the trapezial ridge. Fractures of the body are more common. Walker and colleagues described five different fracture patterns of the trapezium (Fig. 16.37).[218] A vertical intraarticular fracture pattern is the most common, followed by fractures of the dorsoradial tuberosity.

Mechanism of Injury

The position of the trapezium below the thumb metacarpal generally protects it from a direct blow, making this an uncommon cause of trapezial fracture. Several mechanisms of injury have been described for fractures of the trapezium. These fractures are incurred from a fall onto an outstretched thumb, causing the base of the thumb metacarpal to be driven axially into the trapezium. This results in a vertical intraarticular shear fracture on the radial aspect of the trapezial body (Fig. 16.38). The body of the trapezium is split and displaced proximally with the attached metacarpal, resulting in subluxation or dislocation of the joint. Depending on the angle of compression, a fracture of the trapezium or a Bennett fracture of the thumb metacarpal, or occasionally both, may occur. Dorsoradial trapezial fractures may be the result of vertical shear when the trapezium is being trapped between the metacarpal and the tip of the radial styloid. Most fractures of the trapezium have a vertical orientation consistent with a vertical shear force.

The ridge of the trapezium is superficial. It can be palpated just distal to the scaphoid tubercle at the base of the thenar eminence. Because the ridge is superficial, fractures of this structure are generally caused by direct trauma such as a fall onto an outstretched hand or being struck by a pitched ball. Other mechanisms include avulsion of the transverse carpal ligament produced by an AP crush (Fig. 16.39).

86) A incidência radiográfica oblíqua radiocapitelar para melhor visualização das fraturas da cabeça do rádio é realizada com o cotovelo em _____ e a ampola com inclinação _____ de 45 graus

a) AP / cefálica
b) Perfil / cefálica
c) AP / caudal
d) Perfil / caudal

Resposta B

referência Green página 899

Imaging

Anteroposterior, lateral, and oblique elbow radiographs usually provide sufficient information for the diagnosis and treatment of fractures of the head of the radius. The x-ray beam must be centered on the radiocapitellar joint to ensure a tangential view of the radial head.

Fig. 19.2 The radiocapitellar view can be useful because it places the radial head in profile. **A** and **B,** The elbow is positioned for a lateral radiograph, but the x-ray tube is angled 45 degrees cephalad.

Because a hemarthrosis prevents elbow extension, two anteroposterior radiographs may be required if there is significant loss of extension: anteroposterior views of the distal humerus and the forearm. An oblique radiocapitellar view can be useful as it places the radial head in profile.[6] The elbow is positioned for a lateral radiograph, but the x-ray tube is angled 45 degrees cephalad (Fig. 19.2). In patients with nondisplaced fractures of the radial head or neck, plain radiographs may only demonstrate elevation of the anterior or posterior fat pads (sail sign) as a consequence of a hemarthrosis (Fig. 19.3). Bilateral posteroanterior radiographs of both wrists in neutral rotation should be performed to evaluate ulnar variance in patients with wrist discomfort and in those who have a comminuted fracture of the radial head as there is a higher incidence of an associated interosseous membrane injury in these patients.[7-9] Magnetic resonance imaging (MRI) or ultrasound studies may be considered to evaluate the presence of associated collateral ligament or interosseous membrane injuries, but these investigations are uncommonly required.[8,10] Because of the cylindrical shape of the radial head, conventional elbow radiographs often underestimate the extent of articular surface involvement and magnitude of displacement.[11,12] Computed tomography (CT) is useful to quantify fracture size, location, displacement, and comminution in cases in which the indications for surgery are less clear. CT may also assist with preoperative planning with respect to the need for specialized equipment for fracture fixation or prosthetic replacement.

Mason classified fractures of the radial head into three types: type I, fissure or marginal sector fractures without displacement; type II, marginal sector fractures with displacement; and type III, comminuted fractures involving the whole head (Fig. 19.4).[13] One study demonstrated moderate to poor intraobserver and interobserver reproducibility of this classification based on plain radiographs.[14] Other authors have reported that many Mason II fractures are reclassified to type III during surgery owing to additional fracture segments being found that are not revealed on plain radiographs.[12] Johnston added a fourth type: fracture of the radial head associated with an elbow dislocation.[11] This additional category does little to direct treatment other than to emphasize that radial head excision without replacement is contraindicated in the setting of an associated elbow dislocation. Morrey has suggested that isolated fractures of the radial head be referred to as "simple or uncomplicated," while those associated with other soft tissue or bony injuries be referred to as "complex or complicated."[15]

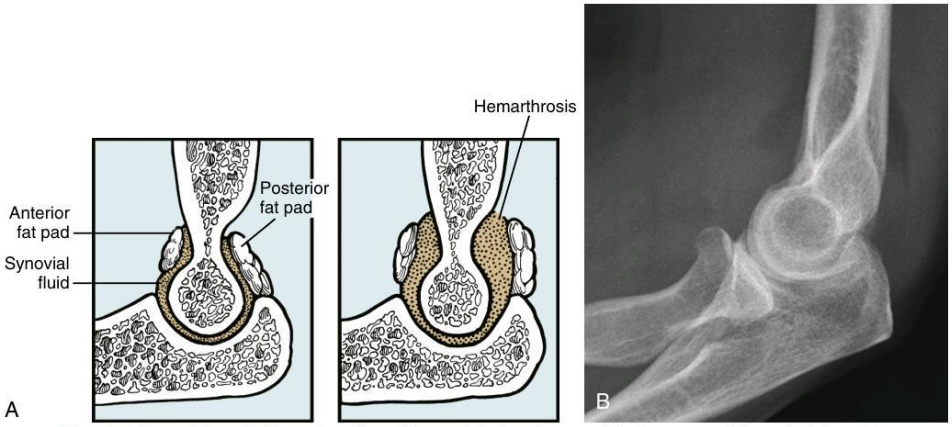

Fig. 19.3 Fat pad sign. **A,** Normal position of fat pads in the elbow and displacement of fat pads induced by an intraarticular effusion. **B,** Lateral radiograph demonstrating anterior and posterior fat pad signs in patient with a nondisplaced fracture of the radial head.

87) Na epicondilite medial é mais comum o acometimento da origem muscular do

a) pronador redondo e flexor radial do carpo
b) flexor superficial dos dedos e palmar longo
c) flexor profundo dos dedos e flexor ulnar do carpo
d) pronador Redondo e flexor ulnar do carpo

Resposta A

referência Green página 1026

described previously. Chondromalacia, arthritis, periarticular tumors, loose bodies, radiocapitellar plica, osteochondral defects, cervical radiculopathy, or ligamentous instability should be considered. Radial tunnel syndrome (supinator syndrome) may be concomitantly present (with an estimated incidence of 5%).[32,33]

Diagnosis

The diagnosis of lateral epicondylitis is based on the clinical history and examination findings of pain centered over the origin of the common extensor mechanism, particularly the area of the ECRB and EDC. Radiographic evaluation of the elbow is typically not helpful in lateral epicondylitis but is helpful to exclude other disease entities. There might occasionally be some ossification of the soft tissues, but whether this is a result of treatment from multiple injections or is a natural process of the disease is uncertain.

Frequently, magnetic resonance imaging (MRI) studies are obtained in patients with elbow pain, often ordered by the referring physician or requested by the patient. MRI findings consistent with lateral epicondylitis include increased signal on T1 and T2 sequences.[20,34] MRI can show frank tearing and separation of muscle from the bone,[20,22] and it has been suggested that there is good correlation between MRI findings and intraoperative findings.[20]

Frequently, asymptomatic patients have false-positive findings with signal enhancement.[34,35] In addition, enhancement may persist in symptomatic individuals even after the clinical resolution of symptoms.[35]

In practice, just about every patient with mild pain over the lateral aspect of the elbow seems to have signal changes on MRI, particularly if the patient has had a series of injections. MRI is not significantly helpful in making the diagnosis or dictating treatment but can be used as an adjunct to look for other causes of potential pain around the elbow.

Ultrasonography is increasingly being used in the evaluation of musculoskeletal pain and may be obtained in order to evaluate lateral elbow discomfort. Findings typically seen in the setting of lateral epicondylitis include thickening of the common extensor tendon, the presence of calcifications, hypoechogenicity of the common extensor origin, neovascularity, and bone cortical irregularity. However, ultrasonographic findings must be interpreted with caution; patients with pain frequently have similar findings to those without lateral epicondylar pain, as expected changes occur with age. Further, as with MRI, ultrasonographic findings that might be suggestive of epicondylitis are known to persist even following resolution of pain.[8,9,36,37]

MEDIAL EPICONDYLITIS

Presentation

Medial epicondylitis is much less common than lateral epicondylitis, with a prevalence of 0.4% compared with 1.3% in one study.[6] Other studies have found an estimated prevalence of 3.2% to 8.2% in patients employed in repetitive labor tasks.[13,38,39] Medial epicondylitis is suggested to constitute 10% to 20% of all epicondylitis cases.[40-42]

Risk factors are similar to those in lateral epicondylitis and seem to include obesity, physical loads, and smoking; some studies suggest a female preponderance, whereas others do not.[6,12,38,43,44]

There seems to be an association of medial epicondylitis with other work-related or overuse musculoskeletal disorders.[38,45] As in lateral epicondylitis, patients are typically middle-aged (fourth to fifth decades) and the dominant arm is usually involved.[40,45] An exception is young throwing athletes who may experience medial-sided elbow pain.[46]

The history typically involves the insidious onset of pain at the medial aspect of the elbow. Tenderness exists at the medial epicondyle and distally over the pronator teres (PT) and flexor carpi radialis (FCR). Pain is worsened with resisted pronation and resisted wrist flexion.[40]

Etiology and Pathogenesis

It has been suggested that the cause of epicondylitis is related to overuse or repetitive motions leading to microtrauma to the muscular origins at the medial epicondyle; most commonly, to the PT and FCR, but also occasionally to the palmaris longus, flexor digitorum superficialis, and flexor carpi ulnaris origins.[10,11,24,41,45,47,48] As implied by the layperson's term *golfer's elbow,* repetitive use and microtrauma can precipitate the condition, and it has been associated with repetitive valgus loads in golf, racquet sports, football, baseball, weight lifting, and archery, in addition to occupational exposures requiring repetitive motions of the hand, wrist, elbow, or forearm.[40,41,45,49-51] One of the oldest references is that of Morris,[52] who described a condition in rowers occurring after "long and vigorous sculling," with pain at the "inner part of the elbow," which resolved with rest and avoidance of pronosupination. Although usually associated with a chronic overuse type of phenomenon, occasionally a single sudden traumatic episode can cause avulsion of the flexor pronator origin and lead to this condition.[24]

As in lateral epicondylitis, pathologic findings include a degenerative tendinosis rather than an inflammatory tendinitis, and it has been suggested that this is due to the repetitive microtears in the setting of an inadequate healing response and, eventually, altered biomechanics of the elbow joint.[48] In pitchers, the stresses are conferred to the medial structures of the elbow, including the flexor pronator muscles and medial collateral ligament (MCL).[48]

Acceleration and valgus forces may exceed the tensile strength of the medial constraints of the elbow, leading to tears with a spectrum of pathologic findings ranging from epicondylitis to MCL insufficiency.[40,45]

The pathologic change found in medial epicondylitis is indistinguishable from that found in lateral epicondylitis with angiofibroblastic tendinosis.[45]

In 23% to 60% of patients, ulnar neuritis is present.[45,48,51,53,54] The pathophysiologic mechanism has been suggested to be a combination of traction injury with entrapment and compression.[40]

Diagnosis

The differential diagnosis of epicondylitis includes neurologic conditions (ulnar nerve neuritis, cervical radiculopathy, pronator syndrome); intraarticular pathologic conditions such as elbow synovitis, arthritis, or osteochondral defects; and ligamentous deficiency (MCL insufficiency).[48] Typically, the diagnosis is made on clinical grounds. Radiographs may reveal calcification adjacent to the medial epicondyle or traction spurs or calcifications, particularly in throwing athletes.[24,48] As in lateral epicondylitis, radiographs are not typically necessary for the diagnosis, but they may exclude alternative causes of elbow pain. Some authors have investigated use of other imaging modalities, and ultrasonography has been noted to be highly specific and sensitive. Typically, a focal hypoechogenic or anechogenic area is shown,[55] although ultrasound is usually not necessary to make the diagnosis.

MRI may be useful to rule out other conditions, such as MCL insufficiency or intraarticular pathologic conditions such as osteochondral defects. In the setting of medial epicondylitis, MRI may show increased signal intensity on T1 and T2 series,[50] but it is again typically not required to make the diagnosis and it is not specific because signal changes can be seen in asymptomatic individuals.[50] It has been suggested that these signal changes in asymptomatic patients may represent senescent changes or prior epicondylitis that has become quiescent.[50]

88) A síndrome compressiva mais comumente associada a Síndrome do Desfiladeiro Torácico é a do

a) túnel cubital
b) túnel radial
c) túnel do carpo
d) pronador

Resposta C

referência Green página 1132, 1133

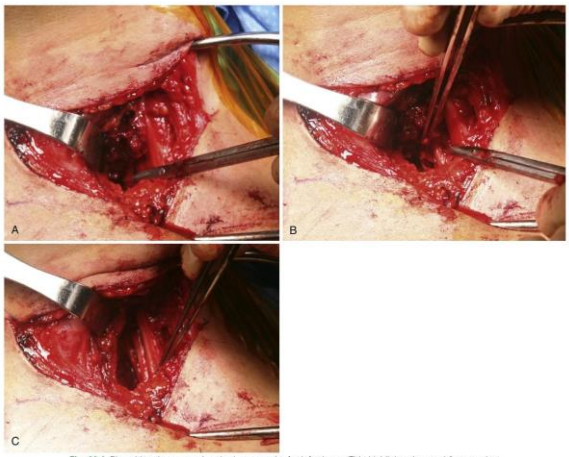

Fig. 29.8 Pleural band compressing the lower trunk of a left plexus. This highlights the need for complete exposure of the interscalene space to adequately decompress the plexus. **A,** A pleural band compressing the lower trunk is lifted by the tenotomy scissors. **B,** Once this band has been removed, circumferential scarring, held by the forceps in this picture, is now visible around the lower trunk. **C,** All three trunks are clearly visible after excising the pleural band and the circumferential scarring.

repetitive strain, muscle imbalance, and eccentric muscle contraction have been extensively studied, and objective effects on muscle strength, endurance, and decreased sarcomere length have been documented.[39-41] It should be emphasized that the presence of these abnormalities must be correlated with an individual's growth and development, body habitus, and patterns of limb usage to identify the particular pathoanatomy.

CLINICAL FINDINGS

Because the vast majority of symptomatic patients are classified as having the electrically negative neurogenic type of TOS, the diagnosis is usually made by physical examination and provocative maneuvers. There is no substitute for experience in evaluating patients. Although clinical symptoms are highly variable, there are certain commonalities that warrant mention.

The most commonly reported complaints are chronic pain of insidious onset involving the shoulder girdle, neck, and upper back in association with paresthesias of the upper extremity. Paresthesias are present in up to 95% of patients with TOS and are the most common initial complaint.[42] Although it usually involves the medial arm, forearm, and ulnar two digits, paresthesias involving the median nerve distribution or the entire hand or arm are not uncommon. A patient may describe the pain as dull, nagging, or throbbing. Fatigue of the extremity when used in a provocative position is typical.

As in carpal tunnel syndrome, symptoms while driving and grooming are common. Women typically have difficulty doing their hair and frequently have to bend their heads down to limit arm deviation. Patients also complain of tenderness at the base of their necks. Nocturnal complaints are frequent but different from those associated with carpal tunnel syndrome. Some patients request narcotics, but the clinician should exercise considerable caution when dis
cations for TOS. Narcotics should rarely be prescribed
Tricyclic antidepressants, neurotropics, or low doses
pines may help patients sleep.

An association between distal nerve compression been attributed to a form of double-crush syndrome.[43-4
a double-crush theory have described carpal tunnel syn

to 45% of patients with TOS; cubital tunnel syndrome in up to 10%; and, more rarely, radial tunnel syndrome, pronator syndrome, or cervical radiculopathy.[44,46] Critics believe that these "associations" are not actually separate areas of pathology but rather misdiagnoses.

Carroll and Hurst were the first to publish a large patient series with variable symptoms that they attributed to nerve compression at only one site.[47] Although in their study patients did have multiple areas of surgery, in-depth review of their symptoms revealed that relief was obtained by one procedure in each instance. These authors emphasized the difficulty of diagnosing carpal tunnel syndrome and differentiating it from TOS in patients with a primary complaint of shoulder pain. They also emphasized the importance of diagnosing and treating distal compression neuropathies in patients suspected of having TOS. These distal sites of compression are typically simpler and more economical to treat, with less risk to the patient.[48]

Others characterize TOS as a great mimicker and cite patients in whom the diagnosis of it is delayed because of multiple prior surgeries on distal nerves without relief.[49] In our practice, if we feel there is a diagnosis of TOS *and* a peripheral compression, and if the electrical studies are positive with very positive clinical findings for a distinct compression, and they respond appropriately to a discrete block, we will do a separate release of the involved nerve. Vague vascular complaints are very common in neurogenic TOS, including a sense of swelling and differential coolness of the hand, with or without discoloration. Complaints of migraine headaches are extremely common and, to a lesser extent, vertigo, memory loss, syncope, chest pain, eye irritation, and facial pain or numbness.[14,16,26,50-52]

Psychological issues can be secondary to chronic pain and the stress of being examined and treated by multiple practitioners, undergoing numerous tests without a definitive diagnosis, and unremitting symptoms.[53,54] Depression, anger, and frustration, especially when dealing with medical personnel, become more prevalent the longer the symptoms persist. For this reason, the concept of a multispecialty team approach, including psychological testing and therapy, may play an important role in dealing with such patients.

PHYSICAL EXAMINATION

Inspection and Palpation

A thorough physical examination with the patient in a gown and all concealing or constricting clothing, jewelry, and hair out of the way is essential. Because the history tends to be nonspecific and the clinical diagnosis in 97% of patients is made by physical examination alone, the initial patient evaluation must be comprehensive. A pain questionnaire may be helpful for both the patient and the clinician. Many unspoken issues can be gleaned from analysis of a patient's written responses on a pain questionnaire and an anatomic pain diagram (Fig. 29.9).

The general appearance of the patient both standing and sitting should be noted, as follows:

- Does the patient slouch with the head in a forward position?
- Is the female patient particularly large-breasted?
- Are there thick grooves in the shoulders from an "industrial-strength" brassiere?
- Is the neck held to one side?
- Is one shoulder drooping?
- Is there scapular asymmetry at rest or when moving the arms? If so, one must determine whether it is related to shoulder pathology or to muscle imbalance with or without neurologic deficit.

Important clues to muscle imbalance should be sought. The skin and contour of the anterior and posterior chest wall should be inspected.

Masses, fullness, and, in particular, tenderness in the supraclavicular and infraclavicular area and venous engorgement or collaterals should be noted (see Fig. 29.2). Most patients with TOS have moderate to significant tenderness in the posterior triangle and/or infraclavicular area as well. Dysesthesias and reproduction of radicular pain, when palpating these areas, is extremely important. The tone and bulk of the muscles of the neck, upper back, shoulder, arm, forearm, and hand need to be inspected by palpation and against resistance; two-point testing has not been particularly helpful. Provocative testing to assess distal sites of compression should be conducted before provocative testing for TOS; this is because once a provocative TOS test is conducted, a patient may complain of symptoms with just about every maneuver from that point forward during the examination. The examiner should start distally and work proximally, looking for carpal tunnel syndrome, tendinitis, cubital tunnel syndrome, rotator cuff problems, and cervical radiculopathy before testing for TOS.

Provocative Tests for Thoracic Outlet Syndrome

There are several standard provocative maneuvers for TOS. In general, the patient's symptoms must be reproduced or the radial pulse diminished or obliterated for a test to be considered positive. Older literature mentions the Adson, Wright, and Halstead tests, but they are frequently positive in the normal population and are neither sensitive nor specific enough, especially for neurogenic TOS. Anterior scalene bands that wrap around the subclavian artery are generally causative in this situation.

The Roos Test

This test is also called the 90-degree abduction external rotation test, the stick-up test, and the elevated arm stress test (EAST). The patient holds the arm(s) in the abducted, externally rotated position and pumps the hands open and closed quickly and repetitively for 3 minutes. A positive test requires reproduction of symptoms or rapid fatigue of the extremity (Fig. 29.10). Patients with positional nerve compression can tolerate this position for 1 minute or less. This maneuver is thought by many to be the most sensitive and reproducible provocative maneuver for the patient with TOS.[55-57] The degree to which symptoms occur also indicates the severity of the compression, in a manner similar to Phalen's sign at the wrist. Changes in the radial pulse also should be noted at this time.

Upper-Limb Tension Test

In this test, the arms are elevated out to the sides with the elbows straight and the head facing forward. Next, with the arms still out, the wrists are passively extended. Finally, the head is tilted away from the side being evaluated (Fig. 29.11). In a patient with TOS, each subsequent maneuver elicits increasing discomfort and/or paresthesias as the tension on the plexus increases. This is Sanders's modification of the test described by Elvey.[58]

Scalene Injection

Although some physicians advocate diagnostic injection of the scalenes[16] with lidocaine during one of the initial encounters, this is best done under ultrasound guidance.[59,60] Multiple techniques have been described with the use of both short-term and long-term anesthetic agents into the anterior scalene.[61-64] The use of image guidance ensures that the anesthetic agent is injected into the muscle belly without extramuscular spread, as blockade of the sensory nerves of the plexus can confound the results of the block.[62] As an adjuvant to physical therapy, anterior scalene injection with a long-acting anesthetic and corticosteroid has been advocated for the patient with palpable spasm of the scalenes. Middle scalene injections may also provide symptomatic relief without the increased risk of phrenic nerve palsy.[63] If the anterior or middle scalene injection helps, it is highly diagnostic and predicts

89) A técnica de Littler para correção da garra ulnar utiliza o tendão

a) flexor superficial do dedo médio
b) flexor superficial do quarto dedo
c) flexor superficial do quinto dedo
d) extensor próprio do indicador

Resposta A

referência Green página 1214

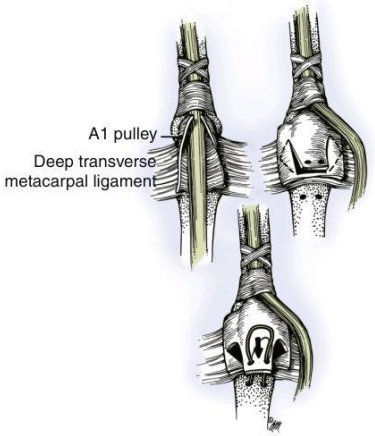

Fig. 31.16 Omer's modification of Zancolli's capsulodesis of the metacarpophalangeal joint in static correction of claw-finger deformity.[110] Omer advised excision of triangular segments of the deep transverse metacarpal ligament on either side to allow the flap of volar plate to be proximally advanced in a straight line. The palmar plate is anchored into the metacarpal neck.

MCP flexion than the other insertions and is only useful in mobile claw deformities in supple hands that do not require a great MCP flexion force to correct. In such hands, it probably has a lower risk of producing "overcorrection" (intrinsic-plus) deformities than other insertions.

Superficialis tendon transfer techniques and modifications. Stiles and Forrester-Brown are credited with the first description of a dynamic tendon transfer to correct finger clawing. They transferred one slip of each superficialis tendon into the corresponding extensor digitorum tendon over the proximal phalanx.[118] Bunnell modified their transfer by rerouting both slips of all the superficialis tendons through the lumbrical canals and anchoring them to both the radial and ulnar lateral bands of the extensor mechanism[109] (i.e., Stiles-Bunnell procedure). Bunnell's aim was to correct the claw deformity and also restore MCP abduction and adduction, but the Stiles-Bunnell operation was beset with problems resulting from its complexity, adhesion formation, and the conversion of the prime flexors of the PIP joints (FDS) into powerful extensors of the IP joints. It often resulted in the development of overcorrection and intrinsic-plus deformities in the fingers after 1 or 2 years.[119]

Modified Stiles-Bunnell procedure (Littler's transfer). Littler modified the Stiles-Bunnell procedure by only using one (usually the middle finger) superficialis tendon, and this has become the standard technique for correction of finger clawing.[56] The FDS of the middle finger is divided at the IP joint level, leaving a short length of one of its two distal slips attached to the middle phalanx. This is used to tenodese the PIP joint and prevent hyperextension. The main FDS tendon is withdrawn into a palmar incision and split lengthwise into four equal slips. One slip is passed through the lumbrical canal of each finger, palmar to the DTML, and is sutured onto the radial lateral band of the extensor apparatus (Fig. 31.19A). Each slip is sutured with the wrist in 30 degrees of palmar flexion, the MCP joints in 80 to 90 degrees of flexion, and the IP joints in full extension. The use of the ring, but not the middle, finger superficialis tendon for this procedure is contraindicated in high ulnar nerve palsy or when the profundus of the ring finger is weak.

Modifications of the superficialis transfer. Littler's transfer, the modified Stiles-Bunnell procedure, has itself been modified by many surgeons to subtly alter its function and reduce the risk of potential complications.[56] The modifications are primarily related to its insertion.

Burkhalter[92,104] inserted the superficialis slips onto the proximal phalanx in patients with traumatic ulnar nerve palsy so as to avoid the risk of PIP joint hyperextension that can occur when the transfer is attached to the lateral band of the extensor apparatus (see Fig. 31.19B). For the same reason, Riordan[120] recommended attachment of the tendon slips to the A1 pulley if the PIP joints are lax and hyperextend.

Zancolli usually looped the tendon slips beneath the entire A1 pulleys (i.e., lasso technique).[121] He used a single transverse skin incision at the level of the distal palmar crease for all the digits to ensure adequate exposure. However, he sometimes preferred to use the first and second dorsal interosseous tendons, rather than the A1 pulleys, as the insertions for superficialis tendon slips for the index and middle fingers, intending to restore finger abduction as well as proximal phalangeal flexion.[121] Palande extended this principle to correct intrinsic-minus hands associated with reversal of the transverse metacarpal arch.[105]

Omer preferred the A2 pulley instead of the A1 pulley (see Fig. 31.19C) as the insertion site to increase the force of MCP flexion.[111] He tensioned the transfers with the forearm supinated and the wrist flat on the table with MCP joints in 45 degrees of flexion. He intentionally placed the transfer for the little finger under greater tension than the ring finger because failure of claw deformity correction is more common in that digit.

Anderson[114] as well as Oberlin[122] performed "extended pulley insertions," looping a slip of the superficialis tendon around both the A1 and the proximal portion of the A2 (A2a) pulleys (see Fig. 31.19D) in each finger. Anderson[114] thinks this is a compromise that provides better mechanical advantage for flexion of the MCP joint than an A1 pulley insertion, but it avoids excessively powerful MCP flexion that can occur when the whole length of the A2 pulley is used.

Shah modified the superficialis transfer and only addressed clawing of the ring and little fingers.[123] In each of these digits he exposed the A1 pulley, opened the flexor sheath distal to this, and divided the superficialis tendon as far distally as possible. He then pulled the cut end of the tendon out of the window in the flexor sheath, pulled it down over the outer surface of the intact A1 pulley, and sutured it onto itself with the finger MCP joint flexed to 90 degrees. He performed the surgery under local anesthetic and reported good results in 12 of 15 cases due to leprosy. Hastings and McCollam performed the same procedure, though not under local anesthetic, whenever the claw correction surgery was restricted to the ring and/or little finger and the little finger had an adequate FDS.[102]

Results. Superficialis transfers do not increase grip strength[102] and risk donor-site morbidity, such as the development of swan neck and other deformities, as described earlier.[55]

Brandsma and Ottenhoff-De Jonge reported full correction of clawing in 16 and improved clawing in 43 of 76 hands with leprosy that underwent either middle or ring finger FDS transfer to the affected fingers.[55] They used an insertion into either a lateral band or the A1 pulley.

Hastings and McCollam assessed 3-year outcomes of FDS transfers using Zancolli's lasso insertion onto the A1 pulley in 23 digits of 12 hands, predominantly involving the ring and little fingers.[102] These procedures were performed for traumatic ulnar nerve injuries with no evidence of functional intrinsic recovery, and, whenever possible, utilized the FDS tendon of an involved finger as the donor for that digit. Thus in most hands both the ring FDS tendon was lassoed around the ring finger A1 pulley and the little FDS tendon was lassoed around the little finger A1 pulley. Correction of the claw deformity was achieved in 19 of the 23 fingers, with 2 of the failures due to preoperative fixed-flexion contractures of the PIP joints. Although grip strength was not improved and functional disability persisted, most patients felt that the procedure had subjectively improved their dexterity. Four fingers developed minor swan neck deformities, and these authors recommend the

90) Na transferência do músculo grácil para o bíceps, nas lesões do plexo braquial, o seu nervo motor é ramo do nervo

a) femoral
b) safeno
c) obturatório
d) ciático

Resposta C

referência Green página 1335

Preoperative Examination and Imaging

In addition to the detailed neurologic examination required for assessment of all brachial plexus injuries, particular attention is paid to the vessels and nerves required to provide nutrition and function to the transferred muscle(s). A conventional arteriogram, or more commonly a magnetic resonance arteriogram or CT angiogram, is required to assess the integrity of the axillary and subclavian vessels. The thoracoacromial trunk artery, a branch of the second part of the axillary artery, is most usually selected for arterial inflow. When proximal flow is disturbed by associated trauma, free muscle transfer is generally contraindicated, although collateral flow may at times allow a successful outcome.[127] Injury to the spinal accessory nerve may occur with brachial plexus injury. If used to power the FFMT, its strength and appearance should be assessed by physical exam, and its innervation by preoperative EMG. While chest wall trauma including pneumothorax and multiple rib fractures are common in patients with brachial plexus injury, the risk of intercostal nerve injury is no more than 10% of fractured ribs.[23]

Operative Procedures

Gracilis Harvest[133]

The gracilis is a superficial muscle that lies on the medial aspect of the thigh. A branch of the obturator nerve enters the muscle obliquely just cephalad to the major vascular pedicle, at a point 6 to 12 cm from its origin. The dominant arterial supply is provided by a branch from the profunda femoris artery 8 to 12 cm from the muscular origin and is approximately 4 to 6 cm long. The vascular pedicle is dissected between the adductor magnus (posteriorly) and adductor longus (anteriorly).

Harvest of the gracilis[133] for FFMT (Fig. 34.34) can be accomplished with three short incisions. The dissection starts with identification of the distal tendon at the tibial insertion. This is a longitudinal incision made over the pes anserinus. The sartorius fascia is elevated. The pes anserinus is identified. The superior tendon is that of the gracilis muscle, whereas the inferior tendon is that of the semitendinosus muscle. The gracilis tendon is isolated; its distal attachment is maintained. A distal medial thigh incision is made to identify the myotendinous

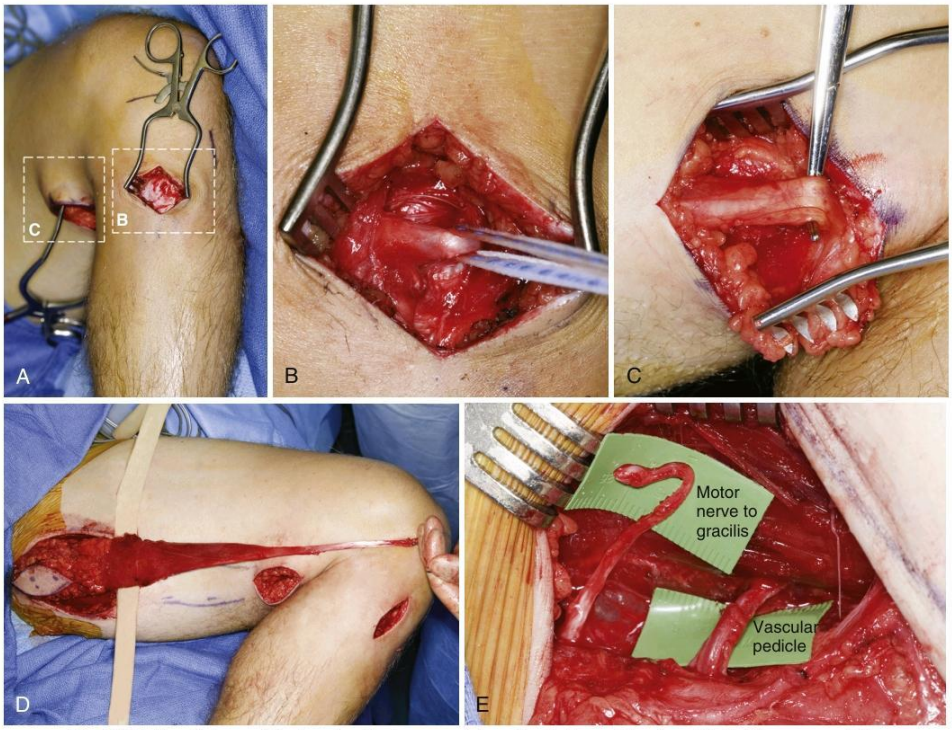

Fig. 34.34 Gracilis harvest for free functioning muscle transfer. **A,** Harvest begins with distal exposure of the gracilis tendon via a longitudinal incision made over the pes anserinus. After the gracilis tendon is identified, a distal medial thigh incision is made to identify the gracilis myotendinous junction. The *dashed boxes* are insets that are further clarified in **B** and **C**. **B,** The gracilis tendon *(in umbilical tape)* is identified underneath the sartorius fascia; the cephalad tendon is the gracilis, whereas the caudad one is the semitendinosus. **C,** The gracilis myotendinous junction is identified in the distal medial thigh incision. All attachments between the myotendinous junction and the distal insertion are then released. **D,** The proximal gracilis muscle is dissected while maintaining a fascial sling around it to preserve the septocutaneous perforators. A skin paddle with myocutaneous perforators is taken with the muscle to act as a monitoring flap. **E,** The vascular pedicle and motor nerve are identified in the interval between the adductor longus and gracilis muscles. The motor branch to the gracilis is dissected as far proximally as possible. The vascular pedicle is dissected laterally to the profunda femoris vessels, which requires identification and ligation of the vascular perforators to the adductor longus muscle. (Used with permission of Mayo Foundation for Medical Education and Research. All rights reserved.)

91) Na macrodactilia, Flatt classifica o gigantismo com neurofibromatose como tipo

a) I
b) II
c) III
d) IV

Resposta B

referência Green página 1438

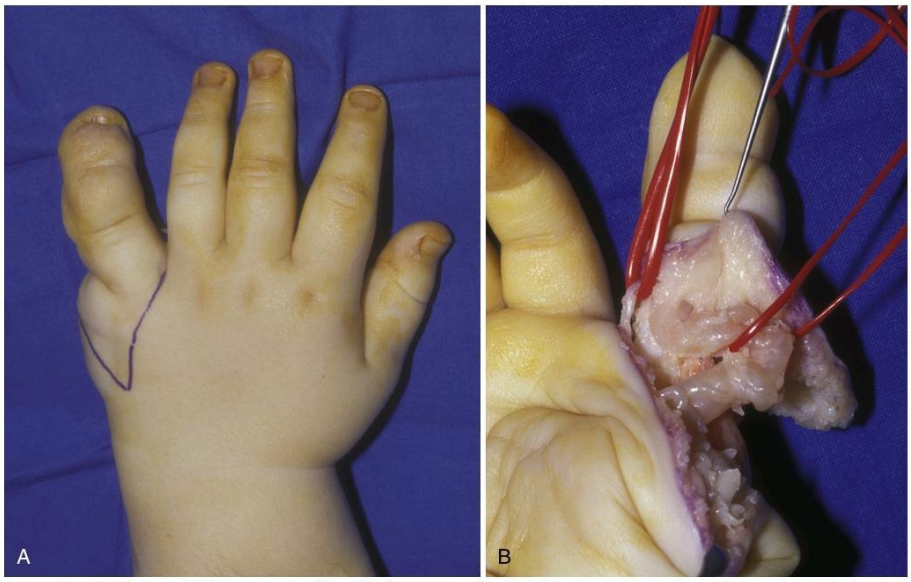

Fig. 36.94 **A** and **B,** Macrodactyly of the fifth finger associated with lipofibromatous change in the ulnar digital nerve along with a normal radial digital nerve.

CRITICAL POINTS

Kirner Deformity

- Kirner deformity is characterized by progressive palmar-radial curvature of the distal phalanx of the small finger.
- The precise etiology is unknown though deformity of the distal phalangeal physis is implicated.
- Radiographs reveal distortion and widening of the physeal plate along with curvature of the diaphysis of the distal phalanx.
- Kirner deformity typically develops in late childhood or adolescence with initial swelling along the dorsum of the distal phalanx. Subsequently, a painless palmar-radial curvature of the distal fingertip develops over time.
- Kirner deformity has little functional effect. The indication for surgery is to address the distal phalangeal and nail deformity.

MACRODACTYLY

Macrodactyly is the congenital condition of abnormally enlarged digits noted at birth or developing postnatal with disproportionate growth. Macrodactyly is uncommon with an incidence of only 0.9% in Flatt's series of upper limb congenital anomalies.[227] Despite being a relatively rare condition, the impact of substantial overgrowth on the appearance and function of the affected hand along with the psychological well-being of the child is substantial. The overgrowth can seem uncontrollable and the appearance of the digits bizarre and stigmatizing. Such overgrowth can affect the upper or lower extremity including the soft tissue and skeletal elements of the digit(s) that are diffusely enlarged. Almost all cases of macrodactyly are associated with *lipomatosis of nerve* (LN), the massive fibroadipose enlargement of the digital nerve within the enlarged digit and extending proximally to involve the affected nerve trunk (Fig. 36.94).[228]

Macrodactyly is remarkable for not only its clinical features but also the extent of the associated nomenclature. Both macrodactyly and the associated LN have had many labels including *nerve territory-oriented macrodactyly, megalodactyly, digital gigantism, macrodystrophia lipomatosa, macrodactylia fibrolipomatosis* and *lipomatosis overgrowth* to describe the enlarged digit and *fibrolipomatous hamartoma, lipofibromatous hamartoma, fibrolipoma, lipofibroma,* and *interfibrillar lipoma of the nerve* to describe the nerve pathology.[229-232] This excess of terminology contributes to confusion and a uniform nomenclature is advocated, hence macrodactyly is the preferred term for the enlarged digit and LN for the associated nerve pathology.

The extent of overgrowth in terms of the number and specific digits involved, extent of involvement of the proximal limb, and the rate and degree of enlargement varies between individuals. In addition to macrodactyly, distinct patterns of overgrowth of digits or the extremity may be seen in a number of syndromes (Box 36.2).

Classification

Macrodactyly has been classified on the basis of rate of growth with Barsky proposing division of cases into a *static* type, where the enlarged digit grew commensurate with the growth of the child, and the *progressive* type, where the affected digit's growth outstrips the normal digital rate of growth.[117] Flatt also proposed a classification based on the pathologic basis of the presentation distinguishing gigantism with lipofibromatosis (type I), gigantism with neurofibromatosis (type II), and gigantism with digital hyperostosis (type III).[227] Upton later added type IV, gigantism with hemihypertropy.[233] The clinical usefulness of these systems is limited in practice by the variation in phenotype that is characteristic of the condition.[234,235] There is value, however, in distinguishing the cases of overgrowth associated with specific syndromes because of the associated anomalies that may be expected and the importance of tumor surveillance in some of these syndromic patients.

92) Na sinostose radioulnar bilateral, classicamente se realiza a osteotomia derrotativa deixando o antebraço dominante e não-dominante, respectivamente, em

a) 10 a 20 graus pronado e supinado
b) pronado bilateralmente
c) 10 a 20 graus pronado e neutro
d) 10 a 20 graus supinado e neutro

Resposta C

referência Green página 1516

Fig. 38.29 Lateral radiograph of the right elbow in a 12-year-old girl demonstrating a congenital posterolateral radial head dislocation.

forearm rotation in infants and the use of compensatory shoulder and wrist motion.[78,79] Forearm rotation must be assessed at the radial styloid and ulnar head to avoid measuring rotation through the radiocarpal, intercarpal, or carpometacarpal joints (Fig. 38.33). Bilateral involvement is seen in approximately 60% of children, and the forearm is fixed in more than 60 degrees of pronation in approximately 40% of patients.[76,79] Children with bilateral involvement and forearms fixed in marked pronation have more functional limitations. In addition, PRUS is more often diagnosed during infancy in children whose arms are fixed in severe pronation and supination (Fig. 38.34).

PRUS has been classified by Cleary and Omer into four types (Table 38.6). In children with PRUS and anterior dislocation of the radial head (type 4), an acute elbow flexion contracture may develop after either forced hyperflexion of the elbow or a prolonged period of flexion of the elbow,[80] possibly associated with an abnormal annular ligament–like structure.

PERTINENT ANATOMY

PRUS is initially cartilaginous and eventually ossifies, at which point it becomes visible on radiographs. The radial head may be dislocated. The synostosis is nearly always proximal, and the length of the synostosis varies.[74,76]

Types of Operations

Resection of Synostosis

Surgery to restore forearm rotation by resection of the synostosis has traditionally been unsuccessful.[81] A review of the literature showed that resection of the synostosis and mobilization of the forearm failed in 22 of 23 forearms.[82] Interposition of a free vascularized fascial flap between the separated forearm bones may prevent recurrence of the synostosis,[82-84] but the amount of forearm rotation gained is small. One contributing factor to the difficulty of simple resection of the synostosis is the underlying bony deformity present in most cases.[85]

Derotation Osteotomy

Fixed extreme pronation (>60 degrees) that interferes with function is an indication for derotation osteotomy[76,86]; unilateral PRUS does

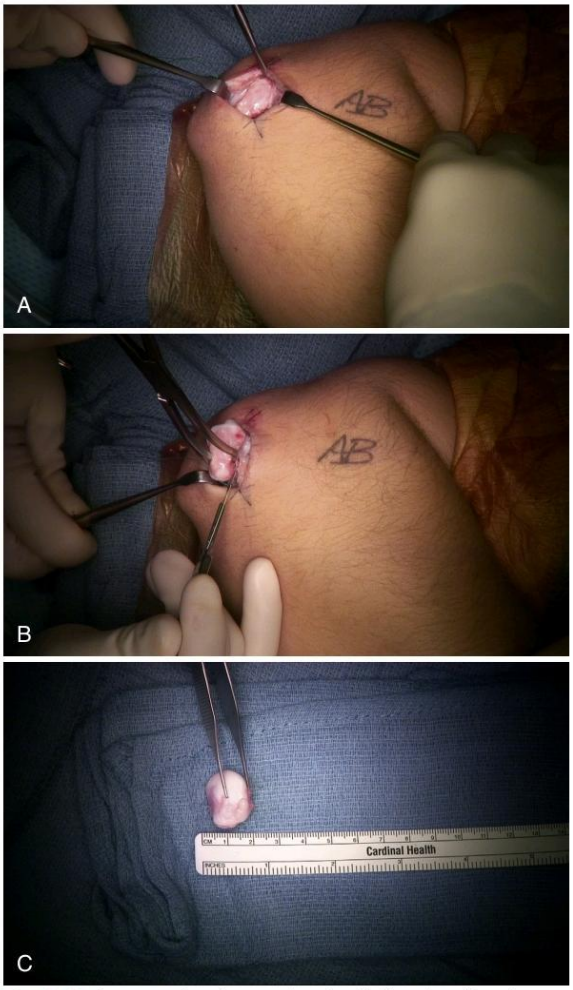

Fig. 38.30 Intraoperative photographs of radial head excision for congenital radial head dislocation. **A,** A Kocher approach to the elbow is used. **B,** Excision of the radial head. **C,** The radial head after excision, demonstrating the typical "mushroom" shape and cartilage loss. (Copyright © Andrea Bauer, Children's Orthopaedic Surgery Foundation.)

not usually cause sufficient functional impairment to warrant surgical repositioning. The timing of surgery is controversial. Recommendations vary from before school age to waiting for the child to choose an intended occupation.[76] The child's preoperative rotational position should be carefully measured and recorded. The optimal rotational position of the forearm is also controversial because the best position varies with the task. Preoperative evaluation by an occupational therapist can help determine the individual child's functional deficits and optimal forearm position. Recommendations for surgical treatment of bilateral synostosis have classically been to place the dominant forearm in 10 to 20 degrees of pronation and the nondominant forearm in neutral rotation. The increasing use of technology requiring bilateral forearm pronation has led many surgeons to position both forearms in slight pronation. Supination tasks, such as eating, perineal care, and carrying, require careful consideration when determining the optimum position. For unilateral PRUS, the forearm is generally placed in 0 to 15 degrees of pronation.[76] A study of the optimal

93) O último osso do carpo a se ossificar é o

a) escafóide
b) trapezóide
c) semilunar
d) pisiforme

Resposta D

referência Green página 1618

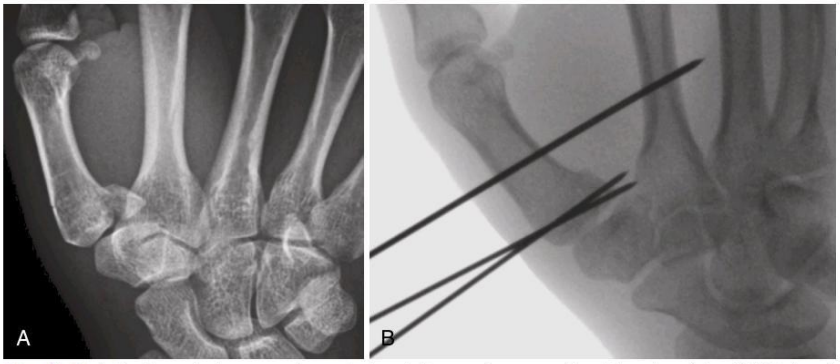

Fig. 41.20 A, Radiograph demonstrating a displaced Bennett fracture with subluxation of the CMC joint of the thumb. **B,** Intraoperative radiograph demonstrating improved alignment of the CMC joint and the fracture. A heavy Kirschner wire from the thumb metacarpal to the index metacarpal can be used to keep the fracture out to length and the tension off the proximal fixation.

recommended to confirm or exclude a scaphoid fracture (Fig. 41.21).[84-86] Immediate MRI evaluation of all children presenting with snuffbox tenderness and negative radiographs is not recommended because the majority are not scaphoid fractures, making advanced imaging studies too costly.[84,86,87] A tomogram is another option, with less radiation than CT scan, that can potentially confirm an acute scaphoid fracture (Fig. 41.22).

Similarly, patients with other fractures of the carpus may present with subtle complaints after relatively innocuous traumatic injuries. Careful observation and systematic clinical examination—with specific palpation of each bony structure of the carpus and wrist—should guide the subsequent diagnostic workup and treatment.

Unlike fractures of the carpus, the diagnosis of distal radial fractures is not subtle. Patients present with pain, swelling, and deformity of the affected wrist following trauma. Clinical examination of the skin is performed to assess for open injuries. A neurovascular examination is performed to assess for injury or impending compartment syndrome.[88] Compartment syndrome is particularly prevalent in children with both a forearm and elbow fracture ("floating elbow" injuries) (Fig. 41.23).[89] Plain wrist radiographs usually confirm the diagnosis and guide treatment. A thorough radiographic evaluation should be performed, x-raying the joint above and below the injury. Relatively innocuous findings, such as ulnar styloid fractures or plastic deformation, can affect the treatment necessary.[90] For example, the classic Galeazzi fracture-dislocations are uncommon in children. The equivalent pediatric pattern is distal radial fractures accompanied by distal ulnar physeal or styloid fractures. Identification of associated injuries guides treatment decisions regarding both nonoperative and operative strategies. In general, imaging of the entire forearm, including the elbow, is performed to evaluate for concomitant ipsilateral upper extremity fractures, which may occur in up to 13% of cases.[91]

Distal radial fractures are generally characterized according to anatomic location (metaphysis, physis, epiphysis, intraarticular) and amount of displacement, angulation, and rotation. Physeal fractures are typically categorized according to the Salter-Harris classification.[17] Salter-Harris type I and II patterns predominate, although Salter-Harris type III and other intraarticular fracture patterns may occur in children.[90] In general, it is important to remember that the metaphyseal Thurston-Holland fragment in type II fractures lies opposite the disruption in the periosteum. This anatomic point assists fracture reduction maneuvers and guides the surgical approach when open operative treatment is necessary.

PERTINENT ANATOMY

Ossification Centers

The radiographic appearance of the carpal centers of ossification occurs in a predictable, ordered sequence.[22,23] The capitate and hamate typically appear at 6 to 8 months of age. The triquetrum ossifies at 2 to 3 years of age, followed by the lunate at 4 years. The scaphoid becomes radiographically apparent at 4 to 5 years of age, followed by the trapezium and trapezoid at 5 years. The pisiform is the last carpal bone to ossify, typically at 6 to 8 years of age.

The scaphoid ossific nucleus appears between age 4 and 5 years.[23] The bony scaphoid forms via enchondral ossification from distal to proximal until the bone is fully ossified, typically by age 14 to 16 years. Multiple ossification centers may appear, and bipartite scaphoids have been described. As discussed earlier, the gradual distal to proximal ossification process may explain the predisposition for distal pole fractures in young children and more adult patterns of scaphoid fractures (waist and proximal pole fractures) in older children and adolescents.

The secondary center of ossification of the distal radial epiphysis becomes radiographically apparent by the first year of life, whereas the distal ulnar epiphysis appears at approximately 6 years of age.[92] The distal ulnar epiphysis often arises from two distinct centers of ossification, giving rise to a bipartite appearance that may be confused with an ulnar styloid fracture. In general, the distal ulnar physis closes at 16 years in females and 17 years in males, with the distal radial physis closing, on average, 6 months later.[22] Knowledge of this timing and the variable patterns of ossification assist in distinguishing acute skeletal injuries from developmental norms. Although the radiographic appearance of the distal radius and ulna changes with development, similar parameters delineate "normal alignment" in both children and adults. Evaluation of radial inclination, radial length, ulnar variance, and volar tilt is appropriate in all but the youngest patients.

Growth

Because the distal physis contributes approximately 70% to 80% of the longitudinal growth of the radius and 40% of the upper extremity, distal radial fractures have tremendous inherent remodeling potential.[22] Prior investigations confirmed that up to 10 degrees of dorsal volar angulation per year may remodel with continued skeletal growth.[93-96] As with other fractures of the developing skeleton, remodeling potential is dependent on the amount of skeletal growth remaining, distance

94) No retalho da artéria interóssea posterior reverso, o pedículo vascular está localizado entre os músculos

a) extensor longo do polegar e extensor próprio do indicador
b) extensor próprio do indicador e extensor comum dos dedos
c) extensor comum dos dedos e extensor próprio do dedo mínimo
d) extensor próprio do dedo mínimo e extensor ulnar do carpo

Resposta D

referência Green página 1731

CRITICAL POINTS

Radial Forearm Flap

Indications
- Wounds of dorsal hand, forearm, or elbow
- Acute coverage of trauma or tumor resection

Preoperative Evaluation
- Allen test and Doppler examination to ascertain adequacy of ulnar artery flow to hand
- Normal forearm skin without injury or scar (where flap is to be designed)

Pearls
- For a flap based on the distal radial artery, design pedicle to allow ample room for rotation.
- Dissect pedicle out as a unit, without separation of artery and venae comitantes.
- Begin dissection on ulnar side of flap.

Technical Points
- Take skin, subcutaneous tissue, and fascia off muscle.
- Take great care to elevate flap from brachioradialis tendon, avoiding injury to perforators.
- Identify and protect radial nerve under brachioradialis.
- Avoid separation of artery and venae comitantes.
- Suture superficialis muscle over the flexor carpi radialis to improve skin graft take at donor site.
- Avoid kinking pedicle with distal rotation.
- When tunneling flap under intact skin bridge, make sure tunnel is spacious to avoid compression of pedicle.

Pitfalls
- Elevating fascia with perforators when dissecting over brachioradialis tendon
- Kinking pedicle with distal rotation
- Loss of skin graft at donor site due to flexor carpi radialis and brachioradialis tendon exposure

Postoperative Care
- Immobilize wrist, MCP joint, and PIP joint for 2 to 3 weeks for skin graft to take.
- Motion is initiated after graft has taken.

Expected Outcomes
- The radial forearm flap supplies excellent supple skin to the hand with a good color match.
- There are few functional problems from the donor harvest.
- Cosmetic aspect of the donor site may be unsightly.
- Minor revision (defatting) of the flap may be necessary.

Reversed Posterior Interosseous Artery Flap

In 1986, the anatomic basis[83] and clinical application[84] of a flap based on the posterior interosseous artery (PIA) were first reported. The flap was initially based on proximal flow to cover elbow defects. The popularity of the PIA flap has increased due to a better understanding of its anatomy and its use as a reversed flap.[85,86]

The PIA arises in the anterior compartment from the common interosseous artery, which also gives rise to the anterior interosseous artery (AIA). The PIA immediately passes dorsal through the interosseous membrane approximately 6 cm distal to the lateral epicondyle, emerging just distal to the edge of the supinator. Throughout its course, it lies between the extensor carpi ulnaris and the extensor digiti minimi, ultimately lying on the abductor pollicis longus muscle belly in close approximation to the posterior interosseous nerve. Some 2 cm proximal to the ulnar styloid, the PIA has an anastomosis with AIA and then passes on to the dorsum of the carpus, where it has additional anastomoses with branches of the radial artery. Throughout its course, the PIA gives septocutaneous perforators that supply the skin over the dorsum of the forearm.

To raise the flap, a line is first drawn from the lateral epicondyle to the distal radioulnar joint. A point on this line 2 cm proximal to the ulnar styloid is marked, which represents the pivot point of the flap based on distal flow. Measurements are taken from this point to the proximal and distal edges of the primary defect. These represent the distances from the pivot point along the line initially drawn. At this point, the distal and proximal margins of the flap are designed and marked (Fig. 44.37). The radial margin of the flap and a distal extension to the distal radioulnar joint are incised. The distal extension can be made 1 cm radial to the previously made surface marking of the PIA. The flap is raised, and the fascia over the extensor digiti minimi is incised 5 mm radial to the thick fascial septum. While retracting the muscle in a radial direction, the PIA branches and the distal anastomosis to the AIA are dissected, preserving the perforating vessels to the skin. A similar skin and fascial incision is next performed on the ulnar aspect over the extensor carpi ulnaris, which is mobilized by division of the muscular branches of the PIA. Most authors suggest keeping a segment of dorsal forearm fascia intact with the distal septal vessels that may contain veins to improve venous outflow in the flap (see Fig. 44.37C). The relationship between the motor branch of the extensor carpi ulnaris and the PIA must be inspected. The most proximal relevant perforator (MPRP) may pass superficial to the PIA, and the MPRP must be preserved. In this situation, the surgeon may decide to divide and repair the nerve. In my opinion, this anatomy is one of the primary factors that mitigates against the choice of this flap. The potential morbidity of dividing and repairing the posterior interosseous nerve in a flap that often has questionable viability makes this flap a secondary option. Once the pedicle and flap have been fully mobilized, they are attached only by the proximal and distal vascular connections. At this time, there is merit in placing a microvascular clamp on the PIA proximal to the MPRP and releasing the tourniquet. If flow is satisfactory, the clamp is removed and the vessel ligated. The flap can then be rotated onto the hand.

The reach of the PIA flap has not been clearly defined. The flap can certainly reach the first web space and the MCP joints. Büchler and Frey[87] have utilized the flap to the PIP joint, but they reported a 21% incidence of partial necrosis. Statistical analysis of their results indicated that the necrosis was not related to pedicle length. This incidence of partial flap loss, however, is higher than that encountered in other series. Nonetheless, this flap remains somewhat problematic in most hands, regardless of the length of the pedicle. Despite enthusiasm for this flap, Brunelli et al. reported a 14% incidence of at least partial necrosis of 113 posterior interosseous flaps.[88] Another more recent report found anatomic variations in 24% of 88 flaps elevated, which led to inability to harvest the flap in 5 patients (6% of cases).[89] This same group noted variable degrees of flap necrosis in 13% of their cases. For these reasons, this flap should only be performed with thorough knowledge of the anatomy (and its variations) along with an acceptance of a rather high rate of partial or complete flap failure.

Musculocutaneous Flap

The blood supply of muscles has been classified into five types[90]:

Type I: One vascular pedicle (e.g., tensor fascia lata)

Type II: One dominant plus other minor (e.g., gracilis)

95) Pensando em uma Síndrome Compartimental, o número de compartimentos que temos na mão é:

a) 4
b) 5
c) 7
d) 10

Resposta D

referência Green página 1972

TABLE 51.4 Compartments of the Upper Extremity

Compartments			Contents
Arm	Anterior		Biceps and brachialis muscles, brachial artery, and median nerve
	Posterior		Triceps muscle and ulnar and radial nerves
	Deltoid	Not technically a separate compartment but has a thick epimysium that may require decompression	Anterior, middle, and posterior heads may require separate release of each area of epimysium
Forearm	Volar	Superficial	Flexor carpi radialis, palmaris longus, pronator teres, flexor carpi ulnaris, and flexor digitorum superficialis muscles
		Deep	Flexor digitorum profundus, flexor pollicis longus, pronator quadratus muscles,[a] and anterior interosseous nerve and artery
	Dorsal	Mobile wad	Brachioradialis, extensor carpi radialis longus, and extensor carpi radialis brevis muscles
		Extensor	Extensor digitorum communis, extensor carpi ulnaris, extensor pollicis longus, abductor pollicis longus, extensor pollicis brevis, and supinator muscles,[b] and posterior interosseous nerve
		Anconeus[a]	Anconeus
Hand	Thenar		Abductor pollicis brevis, opponens pollicis, and flexor pollicis brevis muscles
	Hypothenar		Abductor digiti minimi, flexor digiti minimi, and opponens digiti minimi muscles
	Adductor pollicis		Adductor pollicis muscle (two heads)
	Dorsal interossei (4)		Each is a separate compartment
	Volar interossei (3)		Each is a separate compartment
Fingers[c]			

[a]Reported isolated involvement in exertional compartment syndrome.
[b]The supinator muscle is not typically a component of the extensor compartment, but decompression can be done through the brachioradialis/extensor carpi radialis longus interval.
[c]Compression of the neurovascular structures by the rigid Cleland and Grayson ligaments can lead to skin necrosis and/or loss of the finger.

40% to 60% depending on the presence of dry or wet blood on the cast padding.[64] Cast padding filled with blood is a rigid structure and referred to as a "blood cast." This cast padding must be split. The limb should be elevated only to heart level. Although limb elevation may decrease swelling, it can also reduce perfusion to the affected limb and exacerbate tissue ischemia.

In cases of atraumatic ACS, a more detailed history is necessary. The history should include a list of medications, recent activities, exposure to sick individuals, any bleeding diathesis, and any periods of intoxication or obtundation with prolonged pressure on the extremity.

Laboratory evaluation may be indicated in ACS. CK is a predictor and prognosticator in ACS. CK levels more than 300 U/L are strongly suggestive of ACS following forearm injury. Levels higher than 10,000 U/L after forearm injury are associated with a poor outcome. Baseline complete blood count (CBC) and renal laboratory values (blood urea nitrogen [BUN] and creatinine) should be obtained. In cases of atraumatic ACS, laboratory evaluation should include tests for coagulopathy (prothrombin time [PT], partial thromboplastin time [PTT], CBC, liver function tests), infection (white blood cell [WBC] count, erythrocyte sedimentation rate [ESR], C-reactive protein [CRP], lactic acid), indicators of muscle injury (CK), and baseline renal function (BUN and creatinine). Urinalysis for myoglobin, serum electrolytes, creatinine, and myoglobin should be obtained in the setting of prolonged ischemia, crush injury, or ischemia-reperfusion injury. If there is a suspicion of a bleeding disorder, a hematologist should be consulted.

Medical management of shock, hypoxia, metabolic acidosis, and electrolyte imbalance should be addressed immediately. Supportive care with vigorous hydration, correction of metabolic function, and treatment of hyperkalemia is necessary to prevent sequelae such as renal failure, shock, hypothermia, cardiac arrhythmias, or cardiac failure. Supportive care should be initiated in the emergency room but should not delay surgical treatment.

Hypertonic mannitol has been used to lower intracranial pressure. The use of mannitol in decreasing extremity swelling has been described in animal models and limited case studies. Mannitol administration has not gained widespread use for treatment of impending or ACS. Nonetheless, it has been hypothesized that the use of mannitol may have played a role in the decreased incidence of compartment syndrome in trauma patients at a single medical center over a 10-year time period.[15] Hypertonic mannitol has been found to decrease endothelial swelling and may help reduce muscle necrosis in its function as an oxygen-free radical scavenger.[65] In one clinical report, patients were given a 100-mL bolus of 20% mannitol, followed by an infusion of 10 g/hour for 6 to 24 hours.[66]

Emergent surgical decompression (fasciotomy, or release of the fascia overlying the affected compartments) performed quickly and safely is the treatment for ACS. Neonatal compartment syndrome must be treated with similar urgency (Fig. 51.4). Early fasciotomy is associated with a lower rate of permanent functional impairment. Release of the epimysium surrounding the muscle may also be necessary. Necrotic tissue should be excised. Dead tissue is a nidus for secondary infection or it leads to subsequent fibrosis and contracture. Questionable tissue should be left in situ and reevaluated in a few days to avoid inadvertent removal of viable tissue.[67] Late fibrosis of necrotic muscle can lead to compression of the adjacent nerves, which further impairs extremity function. Concomitant procedures may be necessary at the time of

96) A alteração radiográfica do tipo “pencil-in-cup” é típica da artrite

a) gotosa
b) psoriática
c) reumatóide
d) lúpica

Resposta B

referência Green página 2040

55

Rheumatoid Arthritis and Other Inflammatory Arthropathies

Daniel B. Herren, Kevin C. Chung

This video may be found at ExpertConsult.com:
55.1 Metacarpophalangeal Arthroplasty in Rheumatoid Arthritis

Acknowledgments: The authors would like to acknowledge Nathalie Baxter for her help in revising this chapter. We thank the authors of the seventh edition chapter: Paul Feldon, Andrew L. Terrono, Edward A. Nalebuff, and Lewis H. Millender. Parts of their work have been incorporated into this text.

ETIOLOGY AND DIFFERENTIAL DIAGNOSIS OF INFLAMMATORY DISEASE IN THE HAND

Among the different inflammatory diseases, rheumatoid arthritis (RA) is one of the most prevalent forms. RA has an incidence of 0.5% to 1% depending on the population; it is more common in the northern hemisphere and its prevalence decreases from north to south.[1] Although RA affects mainly the joints, it is considered a systemic disease because of extraarticular manifestations like vasculitis and muscle, heart, and lung involvement, among other medical comorbidities.[2,3]

RA is best characterized as an immune-mediated inflammatory disease.[3] The disease seems to be initiated by a complex combination of genetic and unknown extrinsic factors.[4-6] Although a genetic predisposition is likely, its exact influence is still unclear. Even in monozygotic twins, the range of concordance is only 15% to 35%. However, a positive family history increases the risk of RA roughly three to five times. The seropositive forms have a higher degree of inheritance than the seronegative forms.[7] Regarding extrinsic factors, smoking seems to be a significant risk factor for triggering the disease. Bacterial infection has often been cited as a possible cause of RA, but it has never been proven to be the single driving factor.

The main tissue involved in RA is the synovial membrane in joints and around tendons. In RA, the synovial membrane is hypertrophied in all its layers, is heavily infiltrated by inflammatory cells, and shows angiogenesis. The hypertrophied synovium, also called pannus, erodes cartilage and bone to leave significant defects. The driving cytokines in this process are interleukin-1 and -6 (IL-1 and IL-6) and tumor necrosis factor-alpha (TNF-α).[8-10] Bone destruction is mainly mediated by macrophage-induced osteoclast activation. A major development in the identification and prognosis of RA is the detection of antibodies to cyclic citrullinated peptides (anti-CCP), which are part of the autoimmune reaction. The presence of anti-CCP is more than 98% specific for the diagnosis of RA and generally represents a more aggressive phenotype of the disease. Although not all patients with RA develop anti-CCP, these antibodies can be present up to 15 years before the first clinical symptoms. Rheumatoid factors are less specific for RA and are also found in other chronic inflammatory diseases, such as hepatitis C and tuberculosis. The most important inflammatory mediators in RA are cytokines, including IL-1, IL-6, and TNF. These cytokines are released in the synovial membrane and are responsible for many systemic manifestations of the disease, in addition to local destructive processes in bone and cartilage.[9,10]

There are many different pathways leading to this disease, and no single disease agent explains the pathogenesis. Interleukins, T and B cells, and macrophages interact in a complex manner to initiate and sustain the inflammatory process.

This probably explains the different success rates of the various pharmaceutical agents. Even years before the clinical onset of disease, there may be raised levels of autoantibodies and cytokines in the blood.

Knowledge of the complex interactions among the different cell mediators has increased significantly over the last decade. This facilitates the development of new therapeutic approaches including biologics. The multiple immunologic and inflammatory pathways that seem to be active in RA may explain the effectiveness of different medications.

Differential Diagnosis of Inflammatory Disease in the Hand

Among the different inflammatory diseases affecting the hand, the most common besides RA are psoriasis, systemic lupus erythematosus (SLE), systemic sclerosis, and crystal arthropathies (gout and pseudogout). Each of these diseases has specific patterns of hand involvement and requires an individual approach. However, the general techniques used to treat these diseases and RA are similar because the form of joint and soft tissue destruction is often comparable.

Psoriatic Arthritis

Thirty percent of patients who have psoriasis, a common skin disease, develop psoriatic arthritis.[11] The course of disease is devastating on peripheral joints, as well as the spine and tendon insertion areas (e.g., Achilles tendon). In its most aggressive form, psoriatic arthritis causes arthritis mutilans, which is characterized by bone resorption or osteolysis. This leads to telescoping or flail or unstable fingers, and it is sometimes called “opera-glass” deformity. It is also called a “pencil-in-cup” deformity because of the radiographic appearance of the finger joints. Compared with RA, psoriatic arthritis shows oligoarticular and more distal joint involvement. A typical appearance is the dactylitis, a form of finger inflammation, which mainly involves the distal interphalangeal (DIP) and proximal interphalangeal (PIP) joints and surrounding soft tissue. This gives the fingers a sausage-like appearance (Fig. 55.1).

Psoriatic arthritis is classified as one of the seronegative arthritides with no specific biomarker for detection. It typically starts around the age of 30 to 40 years but can also have an onset in childhood. Skin involvement usually precedes joint involvement, but there are cases in which the joint disease occurs first. This presents a challenge in making the diagnosis. In 2006, the CASPAR study group published classification criteria for the diagnosis of psoriatic arthritis. These include current skin psoriasis or a positive (family) history of psoriasis, dactylitis, juxtaarticular bone

97) Nas queimaduras térmicas, as bolhas aparecem no grau:

a) 1º
b) 2º
c) 3º
d) 4º

Resposta B

referência Green página 2123

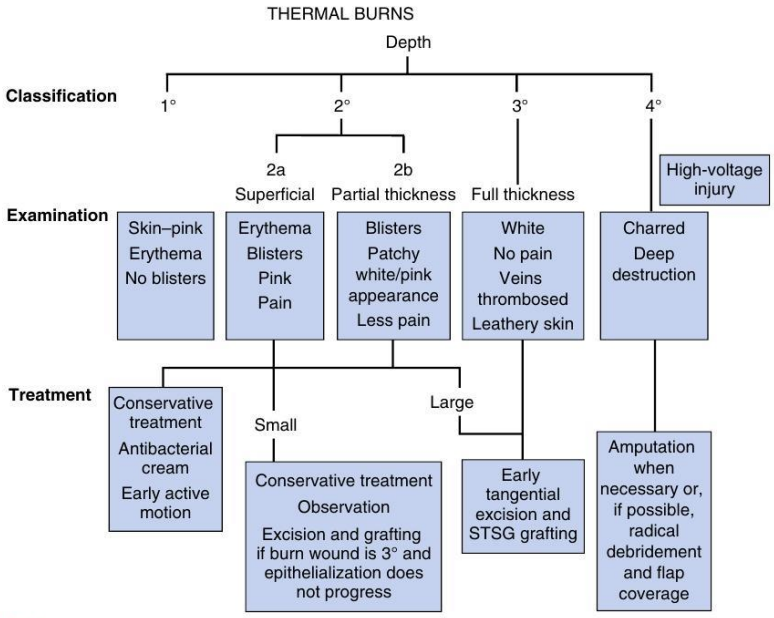

Fig. 57.2 Decision algorithm for the treatment of cutaneous burns. *STSG*, Split-thickness skin graft. (With permission from Germann G, Sherman R, Levin SL: *Decision Making in Reconstructive Surgery on the Upper Extremity*, New York, Springer-Verlag, 1999.)

BOX 57.1 Postburn Hand Deformities

First web adduction contractures
Web space contractures
Dorsal skin contractures
Digital flexion contractures
Boutonnière deformity
Dorsal skin deficiency
Digital loss secondary to ischemia
Median and ulnar nerve compression syndrome

of the dermis. They are considered to be the most painful type in the immediate posttrauma period because sensitive nerve endings are not damaged. They have the potential to heal by virtue of regeneration from the living epidermal elements remaining in the dermis (sweat or sebaceous glands and hair follicles).[19,21] Regeneration, however, may be quite prolonged, depending on the depth of the injury. In second-degree injuries, the resulting scar formation is directly dependent on the depth of injury, and the quality of the regenerated skin is inversely proportional: The deeper the burn, the poorer the quality of the regenerated skin (Fig. 57.3).

Deep partial-thickness second-degree burns appear as a moist mottled surface that may be pale or erythematous, depending on the depth of the burn. These wounds typically blanch with pressure and refill on release. Nerve endings are still present in the vital layers, and thus these burns can be quite painful. The skin still bleeds after a needle prick (Fig. 57.4).

Full-thickness third-degree burns are characterized by the death of all germinal epidermal elements. The wound extends below the level of the dermis. The skin has a leathery unyielding appearance and is pale to brown in color. The nerve endings are destroyed, so the pain may not be significant. Because all the dermal appendages, as well as the overlying epidermis, are destroyed, these wounds cannot heal by epithelial regeneration and thus are not self-healing (Fig. 57.5).

Fig. 57.3 Superficial-thickness second-degree burn with blister formation.

A fourth-degree injury involves necrosis of deeper structures such as tendons and bone and is usually found only after contact burns or high-voltage injuries.[10,19,22]

Determination of Burn Depth

Clinical assessment has not been usurped by modern technology in the evaluation of burn depth. Evaluation is based on the clinical

98) Os aneurismas nas mãos acometem mais frequentemente

a) a artéria radial
b) o arco palmar superficial
c) o arco palmar profundo
d) a artéria ulnar

Resposta D

referência Green página 2251

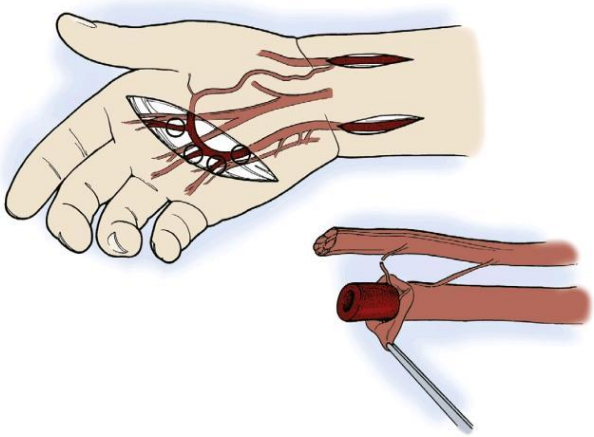

Fig. 60.28 Schematic representation of periarterial sympathectomy of the hand. Longitudinal incisions are used to expose the radial and ulnar artery, and an oblique incision is used in the palm to expose the superficial arch and the origins of the common volar digital arteries (i.e., the Koman technique). A separate incision (not shown) can be used over the anatomic snuffbox to expose the radial artery. After initial dissection under loupe magnification, the operating microscope is used to strip the adventitial fibers from the vessels and sever connections with parallel peripheral nerves. (From Koman LA [ed]: *Bowman Gray School of Medicine Orthopaedic Manual,* Winston-Salem, NC, Wake Forest University Orthopaedic Press, 1997, with permission.)

their symptoms. This is probably the result of the benefit of the sympathectomy effect of excising the diseased and/or occluded artery.

Postoperative management and anticoagulation. The use of heparin, low molecular weight heparin, or other acute antithrombotic agents in the perioperative period has been helpful; however, there are no short-term or large studies documenting efficacy. In the setting of grafts, some surgeons use a single dose of 5000 U of heparin at the release of the tourniquet. In subsequent weeks, others have reported the use of warfarin for the first 3 months following the vascular procedure.[74] These measures seem to be used on a case-by-case basis.

AUTHOR'S PREFERRED METHOD OF TREATMENT: PERIARTERIAL SYMPATHECTOMY

As noted earlier, I feel that periarterial sympathectomy is indicated for patients who have ongoing or worsening symptoms despite conservative measures to manage their vasospasm. The acute development of ulcers usually signals ulnar artery thrombosis. I generally study these patients and if the involved segment of ulnar artery is limited to the very distal forearm and palm, I consider sympathectomy with excision of the ulnar artery. If there is found to be adequate flow from the ulnar artery proximal to the area of occlusion, I perform a bypass as discussed previously. If the segment of ulnar artery thrombosis/thickening goes above the dorsal arterial branch in the forearm, I generally do not perform bypass because, in my experience, long grafts that cross the wrist have a rather poor patency rate. I perform periarterial stripping of the radial and ulnar arteries in the forearm as well as the palmar arch. If the primary symptoms (e.g., ulcers) are on the radial side of the hand, the radial artery in the anatomic snuffbox can also be stripped; this seems to be helpful for some patients.

Aneurysms

Aneurysms in the vessels of the forearm and hand are uncommon and are usually from trauma resulting in a "false" aneurysm due to injury

Fig. 60.29 Arteriogram of young woman who suffered a "minor" stab wound to palm approximately 1 month ago. Now she has a mass in the palm, ulnar nerve paresthesias, and numbness.

to the vessel wall. These are by far most commonly seen in the ulnar artery secondary to hypothenar hammer syndrome (see before) but can be the result of other traumatic injury as well (Fig. 60.29). These patients often present with ulnar nerve symptoms based on compression of the nerve in the palm from the mass of the aneurysm.[80] One also can see aneurysms of the digital vessels as a result of injury. The management of these depends on which vessel is involved and whether ligation and/or

99) A principal estrutura que evita a instabilidade rotatória póstero-lateral do cotovelo é o(a)

a) ligamento colateral ulnar lateral
b) cabeça do rádio
c) ligamento colateral radial
d) ligamento anular

Resposta A

referência Green página 977

22

Complex Traumatic Elbow Dislocation

George S.M. Dyer, Jesse B. Jupiter

Acknowledgment: We wish to thank Dr. Jawa and Dr. Hotchkiss for their excellent chapter in a previous edition of Green's Operative Hand Surgery *and their generosity in permitting much of their text and many of their illustrations to be reused.*

The elbow is one of the most constrained and inherently stable joints in the body, owing to numerous bony and soft tissue structures.[1,2] Therefore, even simple elbow dislocation, where there is no fracture, indicates substantial soft tissue injury with disruption of the capsule and ligaments.[3,4] Due to the joint congruity, it is unusual to observe chronic elbow instability or arthrosis after a stable reduction of a simple dislocation.[5-7]

In contrast, complex elbow dislocations are defined by capsuloligamentous disruption in association with fracture of one or more of the major bony stabilizers: the radial head, coronoid, or olecranon.[8,9] These fractures make the dislocation inherently unstable and almost always necessitate operative intervention to restore alignment and elbow stability.[10,11] The risk of recurrent instability and late arthrosis increases with the complexity of the injury and the number of stabilizers that are injured.[9,12,13] Our understanding of the pathoanatomy of these injuries is advancing rapidly. Although there are still controversies with treatment algorithms, the outcomes of many complex elbow injuries are now predictably good. Successful evaluation and treatment require an understanding of the importance, function, and relationship of each major element of bony and soft tissue anatomy and its contribution to elbow stability.

FUNCTIONAL ANATOMY

Ulnar-Humeral Joint

The primary contributor to elbow stability is the ulnar-humeral joint. It is highly constrained: 180 degrees of the trochlea articulates with the proximal ulna.[1,2,14] The distal humerus tilts 30 degrees anteriorly, and the semilunar notch tilts posteriorly.[15,16] This reciprocal relationship increases the prominence of the coronoid and makes it a key stabilizer of the ulnar-humeral joint. The intact coronoid resists the posteriorly directed moments of the biceps and the triceps (Fig. 22.1).[2,17,18] The coronoid is also important because the anterior band of the medial collateral ligament (MCL) inserts at its base. The MCL is the primary stabilizer to valgus moments.[19] The anteromedial facet of coronoid in now recognized for resisting varus moments[11,18,20,21] (Fig. 22.2).

The olecranon process is less important as a bony stabilizer. In cadaveric studies, resistance to posterior translation decreases linearly with olecranon excision, although 50% of the olecranon can be resected without significantly affecting elbow stability.[14] The intact olecranon is important, however, in resistance to valgus moments.[22]

Radiocapitellar Joint

The radial head, along with the coronoid, resists posterior subluxation of the elbow.[23] With other osseous and ligamentous components of the elbow intact, the radiocapitellar articulation contributes minimally to valgus stability.[2,24] With MCL or coronoid injury, the radial head becomes the primary stabilizer to valgus stress and prevents subluxation or dislocation of the elbow.[25]

Capsuloligamentous Components

The MCL and the lateral collateral ligament (LCL) are the main capsuloligamentous stabilizers of the elbow.[26,27] The MCL is composed of anterior, posterior, and transverse bundles. The posterior and transverse bundles are subtle thickenings of the capsule, whereas the anterior bundle is a robust, identifiable structure that is crucial to resist valgus moments.[22,28,29] The anterior bundle originates from the medial epicondyle and inserts on the sublime tubercle at the base of the coronoid process.[30,31] Medial epicondyle fracture, large coronoid fracture, and MCL tear all are injury variants that can cause valgus elbow instability.[27]

The LCL complex comprises the radial collateral ligament, annular ligament, and posterior band, or lateral ulnar collateral ligament (LUCL).[32] The LUCL originates from the lateral epicondyle and inserts on the supinator crest of the proximal ulna, where it is confluent with the annular ligament. The LUCL is the prime restraint to posterolateral rotatory instability.[33-36] Additional lateral soft tissues, including the extensor origin and the annular ligament, contribute to resisting posterolateral instability.[37-39]

Musculotendinous Components

The osseous and ligamentous structures all provide static stability for the elbow, whereas the muscles crossing the elbow joint provide dynamic stability.[9] The biceps, brachialis, and triceps muscles help maintain the trochlea in the semilunar notch with posteriorly directed forces.[28] The flexor and extensor masses are secondary stabilizers of the medial and lateral sides.[33,37]

PREOPERATIVE EVALUATION

Clinical Assessment

Acute Injury

As in all acute fractures, especially high-energy elbow fracture-dislocations, the patient should be evaluated first according to the Advanced Trauma Life Support guidelines. Associated head trauma has an effect on management and outcome of the elbow because of increased incidence of heterotopic bone formation.[40,41] Additionally, concomitant fractures, dislocations, and injuries in the ipsilateral upper extremity occur in 10% to 20% of cases.[11] Distal radioulnar joint tenderness may represent an interosseous ligament disruption and should alert the examiner to the possibility of an Essex-Lopresti injury.[11,42,43]

Fracture-dislocations are notable for significant swelling, pain, and visible deformity. A thorough neurovascular examination before and after any reduction or manipulation is mandatory because of the high-energy nature of these injuries. Most nerve injuries are secondary to traction. The ulnar nerve is the most vulnerable and commonly injured because of its positioning along the medial ulnohumeral joint

100) A incidência de Brewerton é útil para identificar qual lesão não visualizada nas incidências de rotina:

a) avulsão do ligamento colateral lateral
b) avulsão da placa volar
c) avulsão do fragmento dorsal
d) subluxação articular

Resposta A

referência Green página 261

BOX 7.1 Indications for Fixation of Metacarpal and Phalangeal Fractures

- Irreducible fractures
- Malrotation (spiral and short oblique)
- Articular fractures
- Subcapital fractures (phalangeal)
- Open fractures
- Segmental bone loss
- Polytrauma with hand fractures
- Multiple hand or wrist fractures
- Fractures with soft tissue injury (vessel, tendon, nerve, skin)
- Reconstruction (i.e., osteotomy)

BOX 7.2 Types of Fractures of the Metacarpal Head

- Epiphyseal (all nondisplaced Salter-Harris type III)
- Ligamentous avulsions
- Osteochondral shear fractures
- Two-part fractures occurring in different planes (sagittal, coronal, axial)
- Comminuted fractures
- Boxer fractures with articular extension
- Fractures with substance loss
- Occult compression fractures with subsequent avascular necrosis

of the adjacent overlying metacarpal heads. The Brewerton view (MCP joint flexed 65 degrees with the dorsum of the fingers lying flat on the x-ray plate and the tube angled 15 degrees in an ulnar-to-radial direction) can be helpful to delineate collateral ligament avulsion fractures of the metacarpal head not seen on routine views.[27] A skyline metacarpal view[28] may also be helpful in visualizing the dorsal articular profile of the metacarpal head following a clenched-fist injury. The MCP and interphalangeal (IP) joints are fully flexed and the beam is directed parallel to the dorsal shaft of the proximal phalanx. If fracture visualization remains suboptimal on radiographs or operative intervention is contemplated, then computed tomography (CT)[29] is often necessary.

Treatment of these fractures must be individualized. Displaced ligament avulsion fractures and osteochondral fractures can be satisfactorily managed by ORIF.[22] Kumar and Satku[30] emphasized that small osteochondral fragments should not be discarded but instead "trapped in place" by larger fragments and not separately internally fixed. Two-part coronal, sagittal, and oblique articular fractures are best managed by ORIF with Kirschner wires, small headless compression screws, or interfragmentary screws[21,22,31] (Fig. 7.1). A recent study of 13 patients managed with open reduction and headless compression screws, Kirschner wires, or both achieved union in all cases, 89 degrees MCP range of motion and Disabilities of the Arm, Shoulder, and Hand (DASH) 3.8 at 1-year follow-up, highlighting the need for accurate reduction and stable fixation in these injuries.[32] With refinements in small joint arthroscopy, the role of arthroscopic-assisted reduction with pinning or internal fixation of these injuries has been expanding in recent years though few studies have been published.[33] (See Chapter 17.)

Occasionally, an injury occurs with partial loss of a metacarpal head. While smaller defects may be tolerated, large defects have been successfully managed with osteochondral grafting. Boulas[34,35] has reported successful short-term results with osteochondral autografts taken from a corresponding toe, and Capo and Orillaza reported utilizing a nonarticulating portion of the dorsal aspect of the same metacarpal head successfully.[36] More commonly however, osteochondral

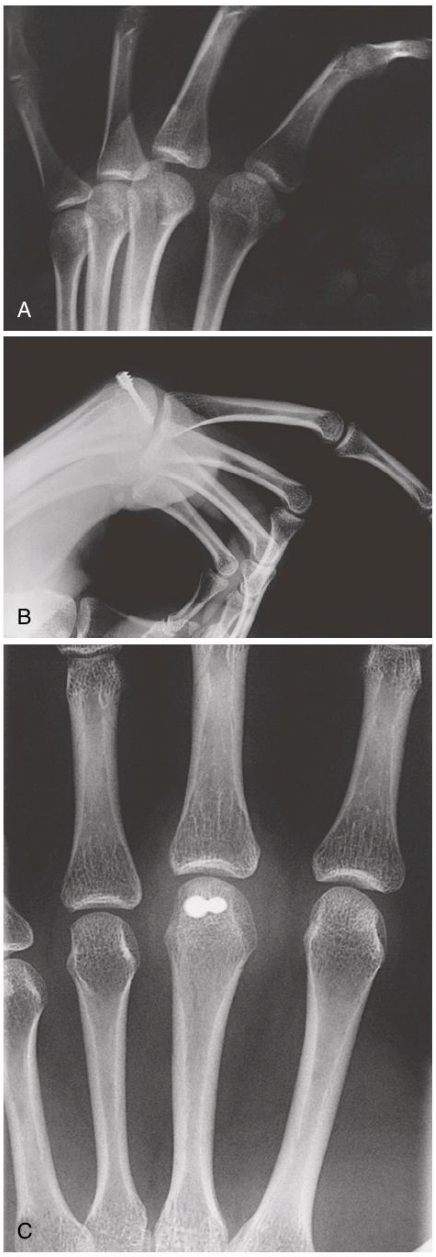

Fig. 7.1 **A,** Displaced, articular sagittal slice fracture of middle finger metacarpal head. **B** and **C,** Postoperative posteroanterior **(B)** and lateral **(C)** views show anatomic reduction and fixation with headless screw. Full MCP mobility was restored.

autografts are obtained from the knee and press-fit into the corresponding defect in the metacarpal head. This can be done acutely for focal defects or as a salvage for posttraumatic osteonecrosis.[37]

A comminuted articular fracture is the most difficult to treat. It is often associated with soft tissue injuries and metaphyseal compaction